

Eosinophilic meningoencephalomyelitis.

Sumalee Siriaungkul*
Saowanee Yenrudi*

Siriaungkul S, Yenrudi S. Eosinophilic meningoencephalomyelitis. Chula Med J 1987 Dec; 31 (12) : 993-999

A 13-year-old girl presented with paresis of extremities. Eosinophilic pleocytosis was prominent and skin test was positive for Gnathostoma. During hospital course, evidence of hemorrhage into the eosinophilic CSF, progressive alteration of consciousness, and signs of brainstem destruction ensued. Postmortem examination revealed eosinophilic meningitis and radiculomyeloencephalitis with multiple tracks. Both clinical features and pathological findings are strongly suggestive of Gnathostomiasis involving the CNS.

Reprint requests : Siriaungkul S. Department of Pathology, Faculty of Medicine, Chulalongkorn University, Bangkok 10500, Thailand.

Received for publication. February 8, 1987.

สุมาลี ศิริอังกุล, เสาวณีชัย เข็นตุคี. การอักเสบของสมอง ไขสันหลังและเยื่อหุ้มสมอง ชนิดอีโอสิโนฟิลิก. จุฬาลงกรณ์เวชสาร 2530 ธันวาคม ; 31 (12) : 993-999

ผู้ป่วยเด็กหญิงไทยอายุ 13 ปี มาโรงพยาบาลด้วยอาการอ่อนแรงของแขน ขา อีโอสิโนฟิลสูงในเลือด และน้ำหล่อเลี้ยงสมองและไขสันหลัง ทดสอบผิวหนังด้วยแอนติเจนของพยาธิตัวจืดให้ผลบวก ขณะอยู่ในโรงพยาบาล มีการเปลี่ยนแปลงของระดับความรู้สึกตัวตรวจพบว่ามีเลือดออกในน้ำหล่อเลี้ยงสมองและไขสันหลัง และอาการทางคลินิกบ่งบอกถึงการทำลายก้านสมอง ตรวจศพพบมีการอักเสบของรากประสาท, ไขสันหลัง, สมอง, และเยื่อหุ้มสมอง รวมถึงรอยทางเดินของพยาธิในไขสันหลังและสมอง ได้ให้การวินิจฉัยจากอาการทางคลินิกร่วมกับพยาธิสภาพที่พบที่น่าจะเป็นไปได้อย่างมาก ได้แก่ โรคพยาธิตัวจืดที่มีการทำลายเนื้อสมองและไขสันหลัง

Parasitic infestation is common disease in tropical areas and Southeast Asia, including Thailand.⁽¹⁾ Gnathostomiasis is a tissue parasitic infection of humans usually manifested as migratory subcutaneous swelling. The significant lesion appears when the parasite involves the central nervous system (CNS) as eosinophilic meningitis, meningoencephalitis, radiculomyelitis, or in combination with frequent lethal outcome.⁽²⁻⁴⁾ The CNS infection caused by *Gnathostoma spinigerum* is characterized by eosinophilic leukocytosis in the cerebrospinal fluid (CSF) and/or hemorrhage. The tissue reaction discloses conspicuous eosinophilic infiltration. The affected organs reveal migratory tracks and/or immunologic sequences arousing by the parasitic product.⁽³⁾ We present herein a fatal case of eosinophilic meningoencephalomyelitis. Although no parasite or its product is observed in the lesion, the clinical features combined with pathologic findings in the CNS point to the *Gnathostoma spinigerum* as the infective agent.

Case Report

A 13-year-old girl was hospitalized on 29 August, 1985, because of progressive weakness of the right arm and leg for three days. She experienced a sharp pain in the neck and right arm, four days before the onset of weakness. The patient had neither fever nor history of migratory subcutaneous swelling. She was borned and lived in Nong Khai, Northeastern Thailand, and just moved to Bangkok four months ago.

On hospitalization, body temperature was 37.5° C, pulse rate 88 beats/min, respiratory rate 28 times/min and blood pressure 80/50 mmHg. She had good consciousness. There was pericardial rub at the left parasternal border. The liver was 2 cm below the right costal margin. Neurological examination revealed motor weakness of all limbs and sensory impairment of hands. Deep tendon reflexes of lower limbs were diminished.

A complete blood count exhibited 9.9 g/dl of hemoglobin and 12,750 leukocytes/mm³ with 62% of neutrophils, 25% of eosinophils, and 8% of lymphocytes. Stool examination revealed eggs of *Opisthorchis*. Roentgenogram of chest showed slightly cardiomegaly. Electrocardiogram revealed generalized low voltage in standard leads with inverted T in V_{4R} - V₄. The lumbar CSF was slightly turbid with a pressure of 70 mmH₂O. It contained 82 mg/dl of protein and 38 mg/dl of sugar. Blood sugar was 96 mg/dl. There were 1,015 leukocytes/mm³ in the CSF with 32% of

eosinophils, 42% of polymorphonuclear cells, and 26% of lymphocytes. Skin test for *Gnathostoma* was positive.

The clinical diagnosis was radiculomyelitis caused by *Gnathostoma spinigerum* and she was treated with corticosteroids. Subsequently, she had progressive drowsiness with disappearance of the pericardial rub. On the third day of admission, she had headache, stiff neck, and blurred nasal side of the left optic disc. Repeated lumbar puncture displayed xanthochronic CSF that contained 580 leukocytes/mm³ with 30% of eosinophils, 160 mg/dl of protein, and 40 mg/dl of sugar. Blood sugar was 106 mg/dl. She developed apnea and cardiac arrest on the fourth day of hospitalization. After resuscitation, the unconscious patient had tachycardia (130 beats/min), hypertension (140/120 mmHg), and negative Doll's eye sign. The left eye had blurred optic disc and hemorrhage. Both pupils were fixed and dilated. The clinical diagnoses were intracranial hemorrhage, damage of the vital centers, and brain herniation. She became hypotensive, hypothermic (35° C), and died after six days of admission.

Pathology

A postmortem examination (A-28-172) revealed small amount of subdural hemorrhage in the posterior cranial fossa and subarachnoid hemorrhage in the right cerebellar hemisphere. A 1350 g brain showed prominent bilateral uncus and tonsillar herniations. Several foci of recent hemorrhage were observed in the cerebellar hemisphere, medulla, and pons on the right side (figure 1). A linear recent hemorrhage, 3 cm in length, was also present in the right cerebellar hemisphere. The spinal cord displayed subarachnoid hemorrhage and reddish and shrunken right gray column in the cervicothoracic regions.

Histologically, the brain and spinal cord were edematous. The blood vessels were congested and surrounded by plasma cells, lymphocytes, eosinophils, and neutrophils (figure 2). These cells also infiltrated the meninges and right cervical dorsal nerve roots. Axonal swelling was noted in the right lateral funiculus of the spinal cord, especially the corticospinal tract (figure 3). Several hemorrhagic and necrotic tracks of different ages and sizes were scattered randomly in both brain and spinal cord. Most tracks in the spinal cord appeared more chronic as characterized by the presence of gitter cells (figure 4). In lower cervical segment, however, there was a recent hemorrhagic

track with few gitter cells. Recent tracks surrounded by necrotic neural tissue and red blood cells were also present in the medulla, pons, and cerebellum (figure 5). A few microabscesses and perivascularities

were seen in the cerebellum and medulla. Additionally, organizing pericarditis, and bronchopneumonia were found.

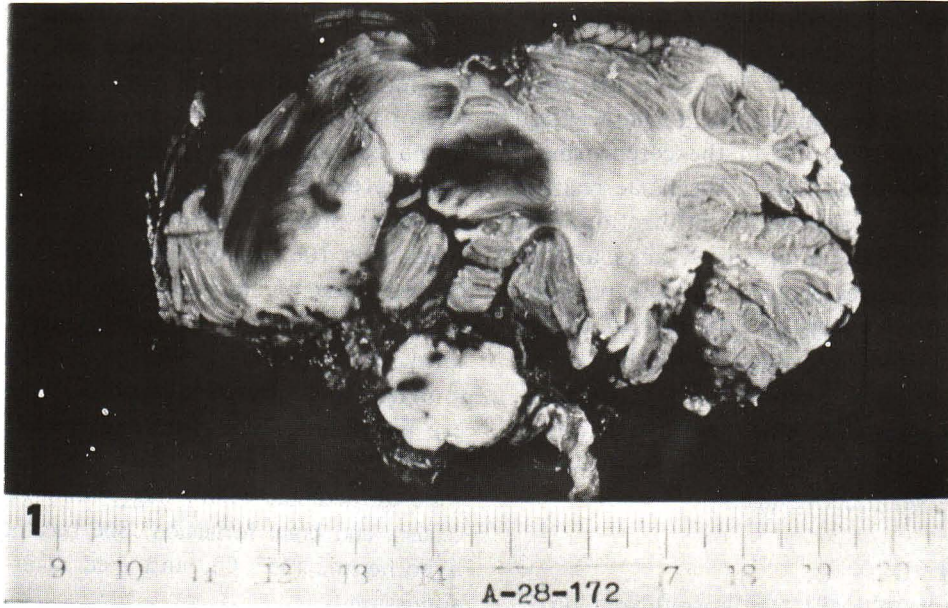


Figure 1 Gross pathology of cerebellum and medulla shows linear foci of recent hemorrhage to represent tracks as well as subarachnoid hemorrhage.

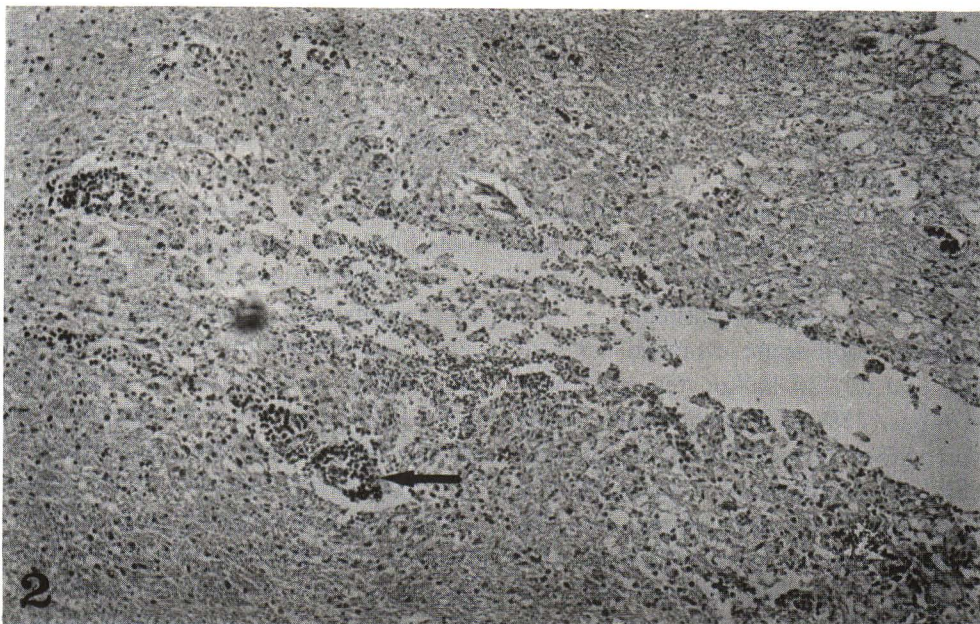

Figure 2 Section of cervical spinal cord shows a track and prominent perivascular infiltration (arrow) in the surrounding parenchyma. (H & E. $\times 100$)

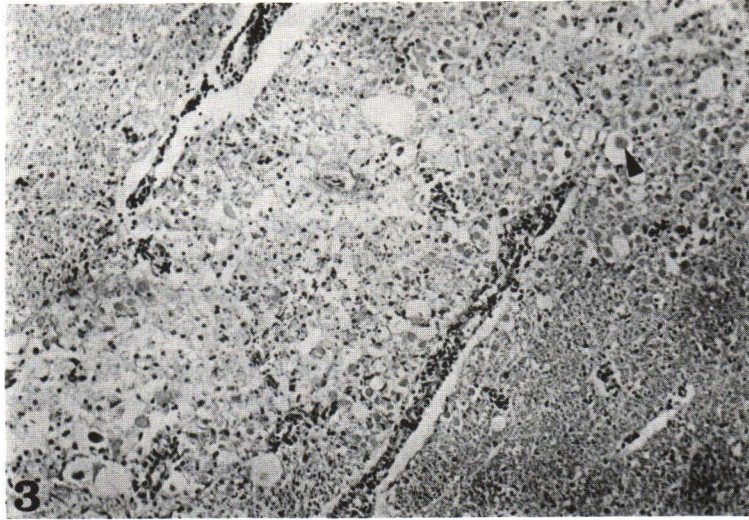


Figure 3 The lateral funiculus of the spinal cord shows axonal swelling (arrow). (H & E, $\times 100$).

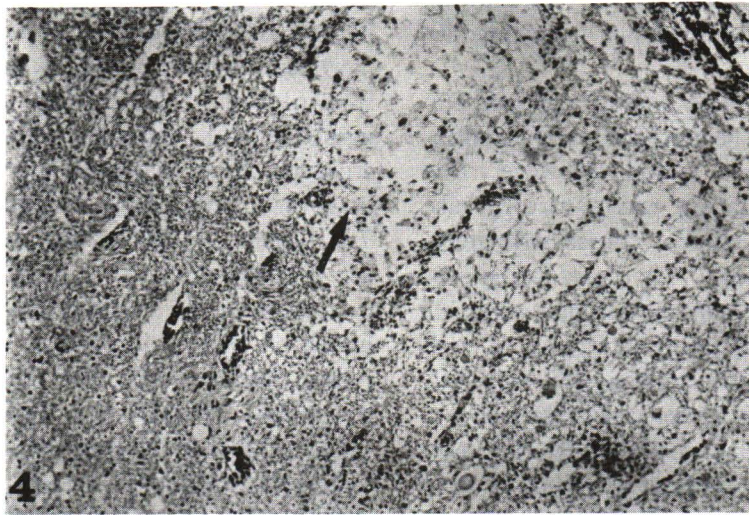


Figure 4 Section of the spinal cord shows a relatively old track (arrow) filled with gitter cells. (H & E, $\times 100$).



Figure 5 Section of the cerebellum shows a recent track filled with necrotic neural tissue and red blood cells (arrow). (H & E, $\times 100$).

Discussion

The spinal cord of this case disclosed acute and chronic inflammation with reparative process and axonal degeneration. The affected structures corresponded well with the signs and symptoms of radiculomyelitis. During hospital course, eosinophilic pleocytosis and xanthochronic CSF were noted along with progressive alteration of consciousness and stiff neck. All were clinical features of CNS lesion with particular meningeal involvement which were confirmed pathologically by identification of multiple hemorrhagic tracks in the brain and subarachnoid hemorrhage. Both affected spinal cord and brain correlated well with course of the disease since admission until termination. Additional morphological changes in the brain included foci of acute abscesses and perivascularities. They might represent superimposed bacterial infection or immunological response following the primary CNS lesion.⁽⁵⁾

When combined with hemorrhagic necrotic lesion, acute necrotizing hemorrhagic encephalomyelitis should be considered as well. However, this form of CNS inflammation was a rare disease characterized by rapid clinical course with polymorphonuclear pleocytosis. It, therefore, is not similar to our case. The current case may resemble other CNS lesions with tissue necrosis, eg such as allergic, viral, or bacterial infection.⁽⁶⁾ However, these conditions disclosed neither clinical presentation nor CSF findings which are similar to our case. The case present herein exhibited ascending myelitis which progressed to meningoencephalitis with simultaneous pericarditis. It indicated involvement of multiple organs. The skin test was positive for *Gnathostoma spinigerum* which could be positive as well in hepatic fluke.⁽⁷⁾ However, the CSF eosinophilic pleocytosis could not be correlated with hepatic fluke infestation. Eosinophilic pleocytosis was observed in both meningitic and meningoencephalitic forms.^(3,8) The two parasites believed to be the causative agents were *Angiostrongylus cantonensis* and *Gnathostoma spinigerum*.⁽⁹⁾ Clinically, *A. cantonensis* could not exhibit migratory lesion as in *G. spinigerum*. It has been claimed that degree of eosinophilic pleocytosis was higher in the *Gnathostomiasis*.⁽²⁾ The latter, moreover, often exhibits usual fatal outcome.^(3,4) Ascending myelitis was as well observed in *Gnathosto-*

miasis as a sole feature or combined with encephalitis and subarachnoid hemorrhage.⁽¹⁰⁾ Bases on morphology in the brain alone, *A. cantonensis* causing non hemorrhagic tract of different size without massive hemorrhage and hematoma formation. While hemorrhagic tract and other hemorrhagic phenomena are strongly suggestive of *Gnathostomiasis*.⁽⁹⁾

Diagnosis of *Gnathostomiasis* involving GNS has previously classified into 3 group according to evidences concerning parasite, morphology of the lesion, clinical manifestation, and laboratory findings.⁽¹⁰⁾ It falls into the first group when living parasite is observed. The second group is notified when there are hemorrhagic tracks in the CNS. The third group consists of eosinophilic pleocytosis with paralysis of extremities and/or cranial nerves, or hemorrhage into the eosinophilic CSF. The pathological features disclose subarachnoid hemorrhage of diverse severity, multiple and variable sizes of hemorrhagic tracks of varying duration involving both brain and spinal cord.⁽⁹⁾ The microscopic study exhibits destructive parenchymal tissue with hemorrhage and leukocytic infiltration. The feature of hemorrhage and cellular reaction are dependent on the age of the lesions. Recent necrosis with red blood cells, either diffuse distributing or forming hematoma, is noted in the early lesion. The cellular infiltration is predominant eosinophils. More chronic lesion characterized by blood pigments, many gitter cells, plasma cells, and some lymphocytes as well as eosinophils. Most chronic lesion consists of astroglial cells and fibrosis. When dead worm is found in the CNS, granulomatous reaction with numerous Charcot-Leyden crystals and lipid filled macrophages rimming the worm are evident. Additional thrombotic necrotizing vasculitis and even abscesses are occasionally noted as well. Study of *Gnathostomiasis* in infected animal indicates a great deal damage on tissue and blood vessels occurring as a result of toxin, spinous body, and marked activity of immature larvae.⁽⁸⁾ Formation of abscesses may explain as a result of superimposed bacterial infection. Perivascularitis is as well an effect of infection or immunological response secondary to parasitic product. Fatal CNS *Gnathostomiasis* usually is the result of intracerebral hemorrhage or involvement of vital centers.^(9,10)

References

1. Vajrasthira S, Herinusuta C. Incidence, distribution and epidemiology of seven common

intestinal helminths in Thailand. *J Med Assoc Thai* 1957 Sep; 40 (5) : 309 - 338

2. Chitanondh H, Rosen L. Fetal eosinophilic encephalomyelitis caused by the nematode *Gnathostoma spinigerum*. *Am J Trop Med Hyg* 1967 Sep; 16 (5) : 638-645
3. Punyagupta S, Juttijudata P, Bunnag T. Eosinophilic meningitis in Thailand : clinical studies of 484 typical cases probably caused by *Angiostrongylus canthonensis*. *Am J Trop Med Hyg* 1975 Nov; 24 (6) : 921-931
4. Punyagupta S, Limtrakul C, Vicdhipanthu P, Kamchanchetanee C, Nye SW. Radioculomyeloencephalitis associated with eosinophilic pleocytosis : report of nine cases. *Am J Trop Med Hyg* 1968 Jul ; 17 (4) : 551-560
5. Punyagupta S, Puttijudata P. Two fatal cases of eosinophilic myeloencephalitis a newly recognized disease caused by *gnathostoma spinigerum*. *Trans Roy Soc Trop Med Hyg* 1968 Dec; 62 (6) : 801-809
6. Antel JP, Arnason BGW. Multiple sclerosis and other demyelinating diseases. In : Petersdrof RG, Adams RD, eds. *Principles of Internal Medicine*. New York : McGraw-Hill, 1983. 2103-2104
7. Saksirisangant W, Sunmanavong K, Kravichian P. *Gnathostoma* antigen : an analysis of protein profiles. *Chula Med J* 1986 Aug; 30 (8) : 739-742
8. Bunnag T, Punyagupta S, Thirachandra S. Study on pathogenicity and central nervous system migration of the larval stage of *Gnathostoma spinigerum* in experimental animals. *Southeast Asian J Trop Med Public Health* 1981 Mar; 12 (1) : 63-68
9. Nye SW, Hill C, Tangchai P, Sundarakiti S, Punyagupta P. Lesions of the brain in eosinophilic meningitis. *Arch Pathol* 1970 Jan; 89 (3) : 9-19
10. Boongird P, Phuapradit P, Siridej N, Chirachiyavej T, Chuanhirum S, Vejjajiva A. Neurological manifestations of gnathostomiasis. *J Neurol Sci* 1977 Mar; 31 (2) : 279-291