

Original article

Quantitative measurement in knee joint effusion: Correlation between plain radiographs and MRI

Chindarat Ratanakornphan*, Teeraphorn Boonswang

Department of Radiology, Faculty of Medicine, Chulalongkorn University, King Chulalongkorn Memorial Hospital, Bangkok, Thailand

Background: Knee joint effusion is a common manifestation of synovial disease resulting from traumatic injury, infection, inflammation and degenerative disease. Plain radiographs and magnetic resonance imaging (MRI) play an important role in diagnosing knee effusion. However, there is scant data demonstrating the correlation of the two studies.

Objective: The purposes of our study were to investigate the correlation of knee effusion between thickness of radiodense area within the suprapatellar pouch on lateral radiographs and volume measurement on MRI studies, and to assess the distribution of effusion in various compartments.

Methods: Quantitative measurement of effusion volume on sagittal fat-saturated T2 weighted images was compared to thickness of radiodense area within suprapatellar recess on lateral radiographs performed within 2-week interval. The correlation between the thickness and volume was assessed by using Pearson test.

Results: Eighty-four studies, performed both MRI scan and lateral knee radiographs during 2-week intervening time, were retrospectively identified. The median thickness of joint effusions on lateral knee radiographs was 7.5 mm (interquartile range (IQR), 2.6 - 16.3 mm). The median volume of suprapatellar fluid on sagittal fat-saturated T2 weighted images was 19.5 mL (IQR, 2.6 - 85.7 mL). Most effusions were found in the central portion (98.8%) and less frequently seen in Baker's cyst (19.0%).

Conclusion: The relationship of knee effusion between thickness of soft tissue density within the suprapatellar pouch on lateral radiographs and the volume on MRI studies was demonstrated as a linear regression model. We have assumed that the volume of MRI is about 1.9 folds of the thickness on lateral radiographs plus 7.0. The accuracy of the equation was 20.9%. To apply for clinical use, we recommend a concise formula that the volume of fluid equals to 2 folds of the thickness plus 7.

Keywords: Knee joint effusion, plain radiographs, MRI, correlation.

Knee joint effusion occurs when a synovial-lined structure contains more than a physiologic amount of fluid. Most effusions are results of traumatic injury, degenerative change, infection or other inflammatory diseases.⁽¹⁾

Recognition of joint effusion on radiographs is to measure a thickness of radiodense area within the suprapatellar recess in lateral view. This line is normally less than 5 mm wide.⁽¹⁾ When there is excess synovial fluid accumulation, it appears as the increased thickness of soft tissue density in this recess.⁽²⁾

*Correspondence to: Chindarat Ratanakornphan, Department of Radiology, Faculty of Medicine, Chulalongkorn University, King Chulalongkorn Memorial Hospital, Bangkok 10330, Thailand.

E-mail: yokmdu@gmail.com

Received: April 9, 2020

Revised: November 1, 2020

Accepted: December 14, 2020

Magnetic resonance imaging (MRI) is the most accurate modality for evaluation knee joint effusion⁽¹⁾, allowing the quantitative volume measurement of effusion and visualization of the distribution of joint fluid.⁽³⁾ However, there is scant data demonstrating on how the quantitative measurement of knee joint effusion in plain radiographs is related to MRI.

The primary outcome of the study was to investigate the correlation of knee effusion between thickness of radiodense area within the suprapatellar recess on lateral radiographs and volume of fluid on sagittal MRI.

The secondary outcome was to assess the distribution of joint effusion in various compartments.

Materials and methods

We retrospectively identified knee MRI studies performed at King Chulalongkorn Memorial Hospital

between March 21, 2014 and May 8, 2019. Among 91 MRI examinations, plain radiographs were performed on the same side during 2-week interval. We presumed that the amount of joint fluid was not significantly different within 2 weeks.

Demographic and clinical data were collected from the electronic medical records. Exclusion criteria included intraarticular lesions or lipohemarthrosis, or documentation of any interventions around knee joint during the intervening time of the two studies. The study was approved by the Ethical Committees, the Institutional Review Board of Faculty of Medicine, Chulalongkorn University (IRB no. 427/61).

Lateral knee radiographs assessment

Lateral knee radiographs were obtained with the patients in weight bearing and knee flexion of 30 degrees.⁽⁴⁾ However, degree of knee flexion depends on each patient's ability. Good image technical evaluation includes all of the followings: 1) superimposition of the medial and lateral condyles of the distal femur; 2) open patellofemoral joint spaces; and, 3) slight superimposition of the fibular head with the tibia.⁽⁴⁾ We measured the maximal thickness of radiodense areas within the suprapatellar pouch on true lateral radiographs (Figure 1).

MRI assessment

All MRI studies were performed at 3.0 T (Phillips Medical Systems) using a commercial

transmit-receive extremity coil. The patients were in supine position and natural external rotation of the knee of 5 - 15 degrees. Image sequences included the following: 1) Sagittal fat-suppressed T2-weighted fast spin echo (FSE) image, flip angle 90, repetition time 3,700 msec, echo time 70 msec, field of view (FOV) 30 x 15 cm, 28 slices, slices thickness of 4 mm; 2) Axial fat-suppressed proton density-weighted image, flip angle 90, repetition time 3,000 msec, echo time 30 msec, FOV 30 x 15 cm, 28 slices, slices thickness of 4 mm.

For quantitative measurement, the effusion volume was generated from fluid in suprapatellar pouch (the recess between suprapatellar fat pad and prefemoral fat pad) in the entire series of sagittal fat-saturated T2 weighted images⁽³⁾ using GE AW Volumeshare 5 software (Figures 2 and 3).

We assessed the distribution of joint effusions in the following compartments on both axial proton density-weighted and sagittal fat-saturated T2 weighted images. The knee joint space was divided into other four compartments: central portion, posterior femoral recess, subpopliteal recess⁽⁵⁾ and Baker's cyst. The posterior femoral recess was further subdivided into 2 regions: medial (anterior to medial gastrocnemius muscle) and lateral (anterior to lateral gastrocnemius muscle)⁽⁶⁾ (Figure 4).

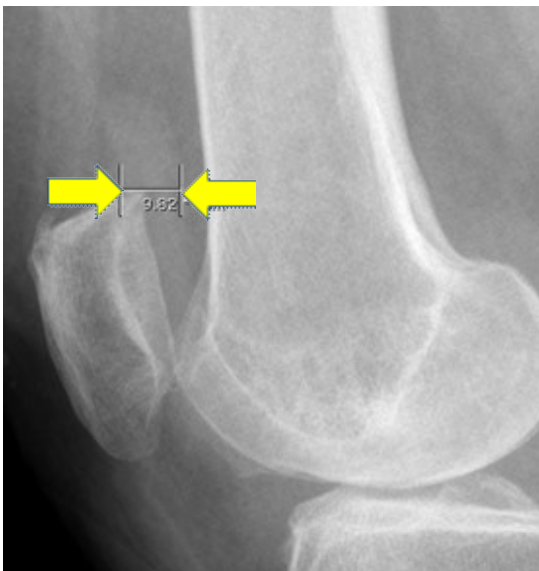


Figure 1. Knee joint effusion on weight-bearing lateral radiograph (arrow).

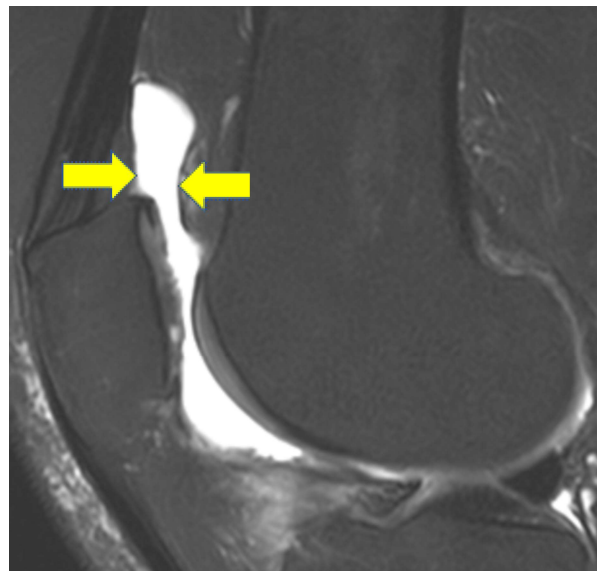


Figure 2. Knee joint effusion on sagittal fat-saturated T2 weighted image (arrow).

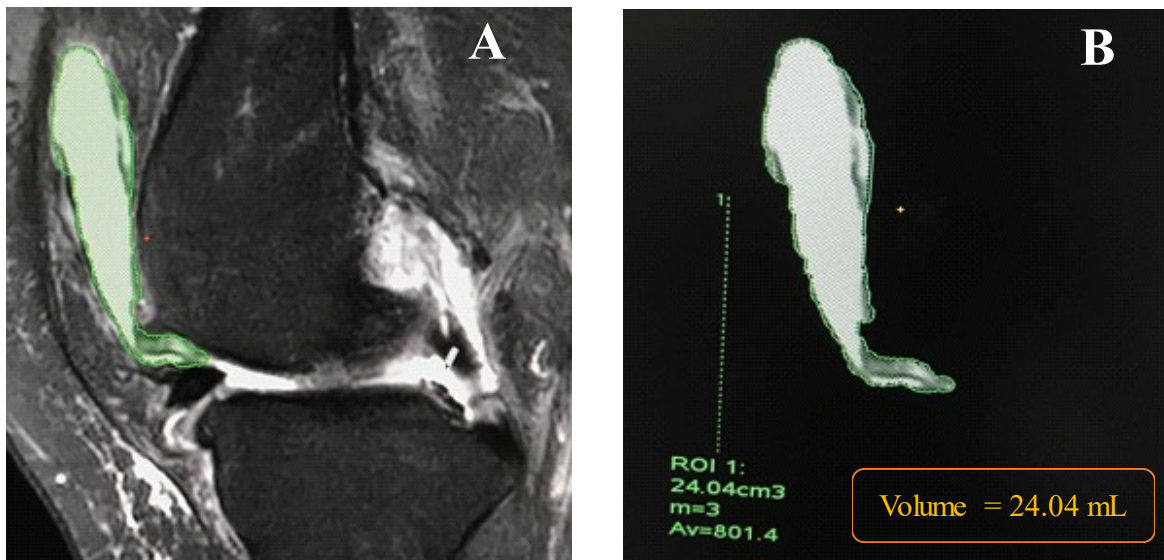


Figure 3. (A) Sagittal T2FS of MRI knee, showing the area of high signal intensity with superimposed color data as green. (B) ROI was placed according to intra-articular fluid in the suprapatellar recess and the total volume was generated from the entire series of images using GE AW Volumeshare 5 software.

MRI images and plain radiographs were independently reviewed by a third-year radiology resident and a musculoskeletal radiologist with more than 5 years of experience using consensus review. When consensus could not be reached, the imaging review was conducted again and adjudicated by a musculoskeletal radiologist. The reviewers were blinded to both studies' measurement outcome.

Statistical analysis

The normality of distribution of continuous variables was tested by histogram And Q - Q plots. Continuous variables were presented as means \pm standard deviation (SD) or medians with interquartile ranges (IQRs). Categorical variables were reported as number and percentage. Correlation between thickness on radiographs and volume on MRI studies was measured using Pearson Correlation (R). A *P*-value < 0.001 was considered statistically highly significant. Analyses were performed with Jamovi version 1.1.7.0 for Windows.

Results

Study population

A total of 91 knee studies, 7 cases were excluded: 3 cases were diagnosed as lipoma arborescens, 2 cases were presented with lipohemarthrosis, 1 subject was found with pigmented villonodular synovitis (PVNS), and 1 study with large

osteochondral bodies. Overall, 84 studies that underwent both MRI scans and radiographic studies during 2-week interval were eligible for the study. There were 8 studies which both lateral knee radiograph and MRI examination were received from the same patient.

Baseline characteristics are provided in Table 1. Forty-six (57.5%) patients were female and 34 (42.5%) were male. The average age of the study group at the time of studies was 50.04 (SD 15.9; range 17 - 77). Most of the studies were left sided knees (61.9%).

Outcomes

The average thickness of joint effusions on lateral knee radiographs was 7.5 mm (SD 3.1) and the median was 7.5 mm (IQR, 2.6 - 16.3 mm) (Table 2).

Joint fluid was homogeneously of high signal intensity on T2FS-weight images.⁽⁵⁾ Quantitative suprapatellar fluid volume measurement on sagittal T2FS-weighted images, the median was 19.5 mL (IQR, 2.6 - 85.7 mL). Of the total of 84 studies, 83 cases (98.8%) had effusions in the central portion; 75 subjects (89.3%) had effusions in the medial posterior femoral recess; while 70 subjects (83.3%) were presented in lateral posterior femoral recess; 51 cases (60.7%) were found in subpopliteal recess and 16 studies (19.0%) were less frequently seen in Baker's cyst.

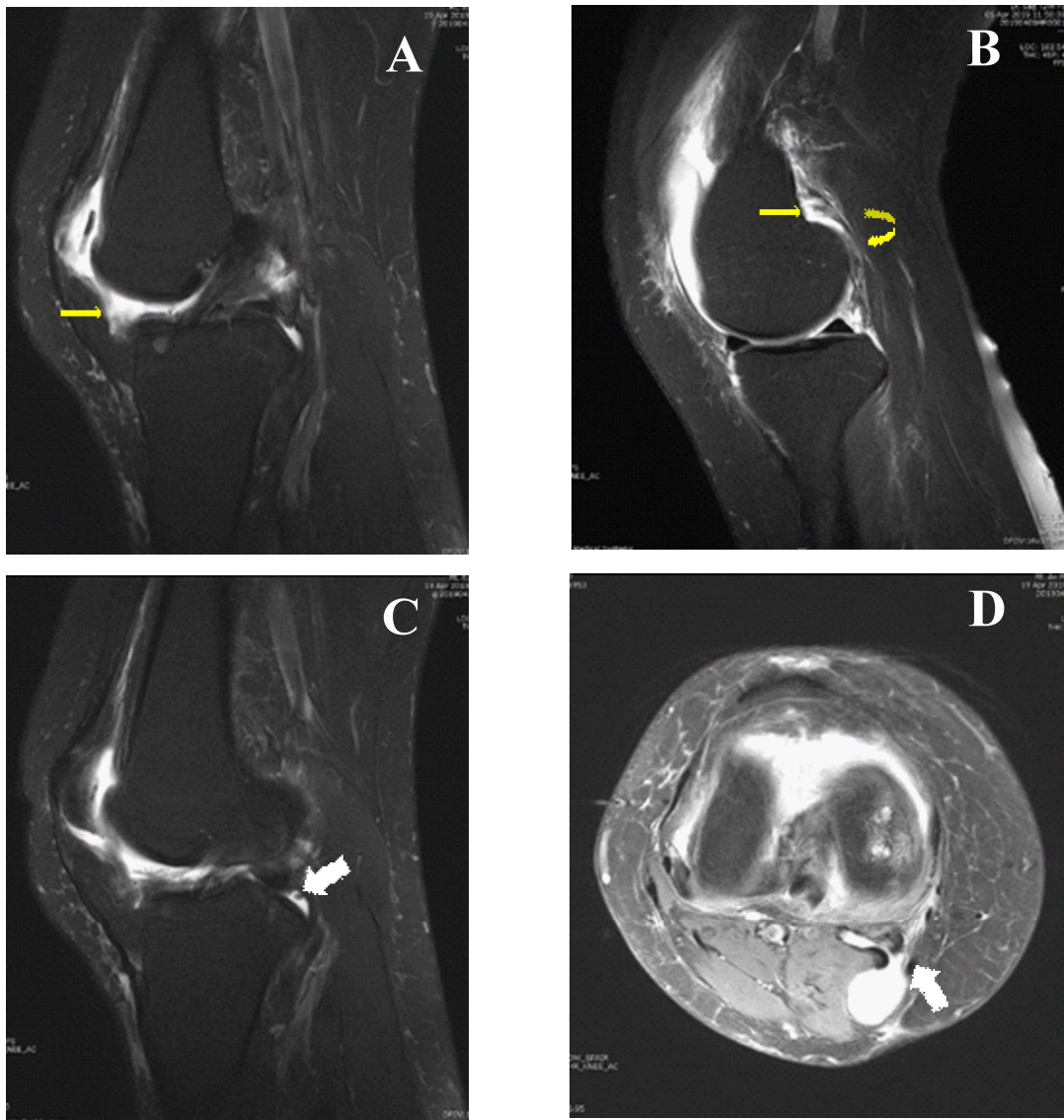


Figure 4. Distribution of knee joint effusion.

Sagittal T2 weighted images showed (A) central synovial recess located anterior to the anterior cruciate ligament (arrow), (B) posterior femoral recess (arrow) located between the knee capsule and the medial or lateral head of the gastrocnemius muscle (curved arrow), (C) subpopliteal recess (curved arrow), (D) Axial proton-density weighted image showed the Baker's cyst (curved arrow).

Table 1. Baseline characteristics of study group.

Variables	N (%) or mean \pm SD	Median [min, max]
Gender		
Female	46 (57.5)	
Male	34 (42.5)	
Age (years)	50.0 \pm 15.9	54.5 [17, 77]
Radiographic assessment		
Position		
Left	52 (61.9)	
Right	32 (38.1)	

Table 2. Quantitative suprapatellar pouch measurements on lateral radiographs and MRI studies.

Variables	N (%) or mean ± SD	Median [min, max]
Radiographic assessment		
Thickness	7.5 ± 3.1	7.5 [2.6, 16.3]
MRI assessment		
Volume	20.9 ± 12.8	19.5 [2.6, 85.7]
Presence of effusion in other cavity		
Central	83 (98.8)	
Posterior: medial	75 (89.3)	
Posterior: lateral	70 (83.3)	
Subpopliteal recess	51 (60.7)	
Baker's cyst	16 (19.0)	

The correlation between suprapatellar fluid volume measurement on sagittal MRI studies and all examined thickness of radiodense area on lateral radiograph was 0.457 ($P < 0.001$, Table 3).

In 21 out of 84 studies, the relationship between thickness less than 5 mm and volume measurement was a negative linear relation ($r = -0.057$, $P = 0.805$) without statistical significance.

There was fair agreement between 5 - 10 mm width and volume measurement with statistical significance ($r = 0.495$, $P < 0.001$) in 47 cases.

There were 16 cases showing positive linear strength between more than 10 mm width and quantitative measurement without statistical significance ($r = 0.278$, $P = 0.298$).

Applying linear regression model, we predicted the volume of MRI is 1.9 folds of thickness on lateral radiographs plus 6.7. The accuracy of the equation was 20.9% ($r = 0.45$, $P < 0.001$) (Figure 5).

Table 3. Correlation between radiographic thickness assessment and volume MRI measurement.

		Radiographic assessment of thickness			
		All	< 5	5 - 10	> 10
Volume MRI Assessment	Pearson correlation	0.457	-0.057	0.495	0.278
	P - value	< 0.001*	0.805	< 0.001*	0.298
	N	84	21	47	16

Table 4. Linear regression models and correlation coefficient of categorized groups; x = thickness , y = volume

Thickness (mm)	Equation	R
All thickness	1.9 * (Thickness) + 7.0	0.45
5 - 10	3.6 * (Thickness) - 4.2	0.49
>10	2.5 * (Thickness) - 4.7	0.27

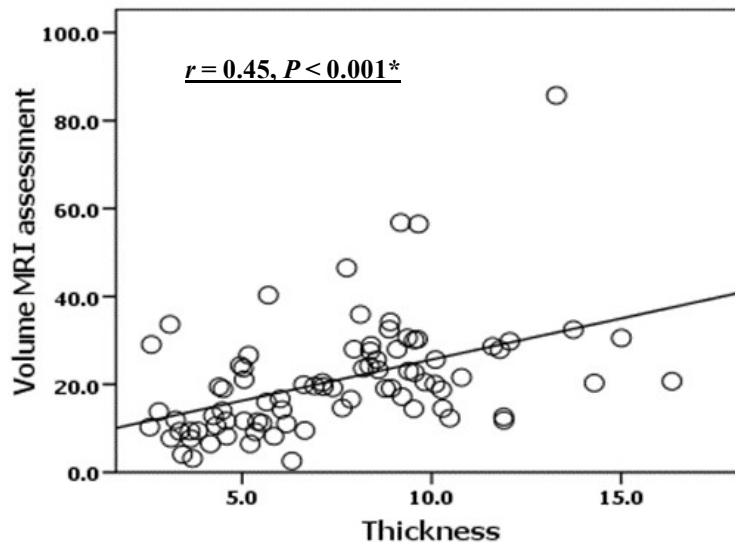


Figure 5. Linear regression model of correlation between radiograph thickness assessment and MRI volume measurement.

Discussion

Knee joint effusion is the manifestation of synovial disease which may be the results from trauma, degenerative change, infection or inflammatory disease.⁽¹⁾ The radiographic sign of knee effusion has been widely described as the increased width of soft tissue density in suprapatellar area on lateral view.^(2, 7)

The previous study by Ferris M. Hall in 1975 showed that fat pad separation corresponding to the width of the base of the suprapatellar bursa was by far the most accurate sign of joint fluid.⁽²⁾ Any fat pad separation greater than 5 mm was assumed to represent an effusion. Hall evaluated each roentgenogram for evidence of effusion and performed subsequently joint aspiration. As the results, 8 of 9 cases of effusions of 6 - 9 mL had fat pad separations of 5 -10 mm, while 25 of 27 cases demonstrated a width of 10 mm or greater had more than 10 mL of joint effusion.

Schweitzer ME, *et al.*⁽⁸⁾ established the MR criteria that enable assessment of the quantity of effusion by injecting various amount of fluid into cadaveric knees. When 4 mL of fluid was injected, a 10.0-mm width in the suprapatellar recess was seen on lateral sagittal MR image.

In our study, there were moderate agreement of suprapatellar pouch thickness on lateral radiographs and volume of fluid on sagittal T2FS-weighted images, with Pearson correlation of 0.45.

This study we developed three methods to measure effusion volume with linear equation

(Table 4). When thickness (x) increases, volume (y) multiplies by 1.9 then added with 7.0 (or volume of MRI assessment = $1.9 * (\text{Thickness}) + 7.0$) The correlation coefficient of this equation was 0.45. For subgroup analysis, when x ranges from 5 to 10 mm, y increases 3.6 times then minus 4.2. Another equation demonstrated with x more than 10 mm, y increases 2.5 folds then deducted by 4.7. The correlation coefficient (r) of the two latter equations were 0.49 and 0.27 respectively, indicating the superior correlation for x ranges from 5 to 10 mm.

This suggests that covariate variables (i.e. gravity, degree of knee rotation, degree of knee flexion) may influence the effect of the two variables (x , y). The thickness of fluid in the suprapatellar pouch was assessed on lateral weight bearing knee radiographs while the volume measurement was obtained in supine position. On lateral weight-bearing radiograph, the fluid moves toward the dependent recess of the knees which results in the decreased thickness in suprapatellar bursa and was not approximate to the volume on MRI.

Joint effusions are distributed within the various compartments mostly in the central portion and suprapatellar pouch. Effusions were occasionally found in posterior recess, subpopliteal recess and less frequently seen in Baker's cysts. This reflects anatomical communications between synovial joint spaces. It is noteworthy that joint fluid in the suprapatellar pouch may not represent the accurate volume of effusions thus the assumption of joint effusions solely on radiodense thickness from lateral

plain radiographs may be insufficient. MRI conveys more sensitive and accurate data in diagnosing joint effusion.

Our study has limitations. First, the study design was retrospective, and the comparison with addition of amount of joint fluid performed by arthrocentesis would be optimal. Second, the amount of joint fluid may have changed during 2-week interval. Third, we did not find significant relationships between thickness which $x > 10$ mm, $x < 5$ mm and volume assessment on MRI because of a relatively small sample size. Finally, the different position of the knee examination between MRI (lay down position) and plain radiographs (weight-bearing position) would qualify as a potential covariate, yielding low accuracy of the equation.

Conclusion

The radiologic sign of knee joint effusion is related to measurement of soft tissue density in the suprapatellar area on the lateral view. The width ranges of 5 – 10 mm showed significant correlation with volume measurement on T2FS-weighted MRI. In summary, we have proposed the linear equation to estimate volume of effusion demonstrated as 1.9 folds of thickness of radiodense area within suprapatellar pouch on lateral weight-bearing radiograph plus 7.0. The accuracy of the equation was 20.9%. We, hereby, recommend a concise formula for clinical use that volume of fluid equals to 2 folds of thickness plus 7. Nevertheless, due to the relatively low correlation coefficient value, further studies are needed to affirm the equation.

References

1. Resnick DL, Kransdorf MJ. Bone and joint imaging. 3rd ed. Philadelphia, PA: Elsevier Saunders; 2005.
2. Hall FM. Radiographic diagnosis and accuracy in knee joint effusions. *Radiology* 1975;115:49-54.
3. Wang X, Cicuttini F, Jin X, Wluka AE, Han W, Zhu Z, et al. Knee effusion-synovitis volume measurement and effects of vitamin D supplementation in patients with knee osteoarthritis. *Osteoarthritis and Cartilage* 2017;25:1304-12.
4. Er A, Murphy A, Knee (horizontal beam lateral view). Radiology reference article [Internet]. 2020 [cited 2020 Mar 16]. Available from: <https://radiopaedia.org/articles/knee-horizontal-beam-lateral-view-1>.
5. Kaneko K, De Mouy EH, Robinson AE. Distribution of joint effusion in patients with traumatic knee joint disorders: MRI assessment. *Clin Imaging* 1993;17: 176-8.
6. Bolog N, Andreisek G, Ulbrich E. MRI of the knee: A guide to evaluation and reporting. Cham: Springer International Publishing; 2015.
7. Tai AW, Alparslan HL, Townsend BA, Oei TN, Govindarajulu US, Aliabadi P, et al. Accuracy of cross-table lateral knee radiography for evaluation of joint effusions. *AJR Am J Roentgenol* 2009;193: W339-44.
8. Schweitzer ME, Falk A, Berthoty D, Mitchell M, Resnick D. Knee effusion: Normal distribution of fluid. *AJR Am J Roentgenol* 1992;159:361-3.