

Suprahepatic membranous obstruction of inferior vena cava : a case report

Chesada Sangsubhan*
Chirojana Suchato**

เจษฎา แสงสุพรรณ, จิโรจน์ สุชาโต. แผ่นกั้นในเส้นเลือดดำใหญ่อินฟีเรีย
เวนาคาวาเหนือต่อระดับเส้นเลือดดำเฮปatica. จุฬาลงกรณ์เวชสาร 2527
พฤศจิกายน ; 28 (11) : 1305-1310

Suprahepatic membranous obstruction เป็น *congenital malformation* ของ *I. V.C.* ซึ่งพบได้ไม่บ่อยนัก ลักษณะเป็น *membrane* กั้นอยู่ใน *I. V.C.* ที่เหนือระดับ *hepatic vein* อาจเป็น *complete* หรือ *incomplete obstruction*

อาการโดยทั่วไปเป็นอาการของ *I.V.C. obstruction* *cavography* และ *ultrasonogram* เป็นสิ่งที่จำเป็นที่สุดในการวินิจฉัย โรคนี้สามารถรักษาได้ 3 วิธี *balloon membranotomy, transatrial membranotomy* และ *by pass grafting.*

* Department of Surgery, Faculty of Medicine, Chulalongkorn University.

** Department of Radiology, Bangkok General Hospital.

A case of Suprahepatic Membranous obstruction of inferior vena cava is presented. A congenital anomaly of the valve is the probable cause but may be superimposed by a thrombosis. The diagnosis is made by cavography and ultrasonography

Suprahepatic membranous obstruction of the inferior vena cava is a rare condition recognized in relatively recent times.⁽¹⁻¹²⁾ It can be misdiagnosed as portal hypertension from liver cirrhosis or Budd-Chiari syndrome. Many patients with this condition may have undergone the unnecessary operation of portacaval or leinorenal shunt.

Case Report

A 23 year-old male khmer refugee was referred from Khao-I-Dang, Prachinburi, Thailand with a history of dilated veins over the abdominal wall and scrotum for 5-6 years. No associating symptoms were noted. Physical examination revealed pitting edema of both legs,

no jaundice, no ascites. The superficial dilated veins of the paraumbilical areas and lateral abdominal walls were seen with an ascending flow. Scrotal veins were also dilated. Liver was enlarged to 4 c.m. below the right costal margin. The spleen was not palpable. Hepatic encephalopathy was not present.

Routine blood examinations, urinalysis and liver function tests were within normal limits. E.K.G. and Chest x-rays were normal. An Ultrasonogram revealed a suprahepatic obstruction of I.V.C. and dilatation of the hepatic vein (Figure 1). Celiac and superior mesenteric arteriograms were normal (Figure 2). Cavography was performed percutaneously via the right femoral vein. Right atrium injection study was also performed via the right cephalic vein. Complete obstruction of the suprahepatic portion of I.V.C. was evident, with reflux into the hepatic, renal and retroperitoneal veins (Figure 3,4).

The patient migrated to the U.S.A. where the operation was performed.

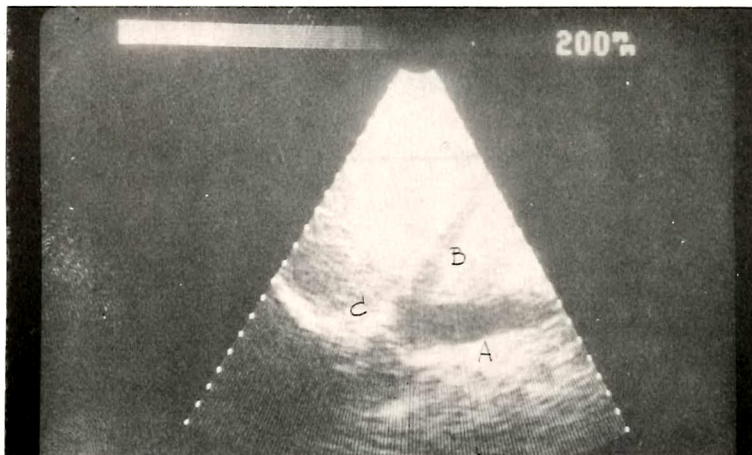


Figure 1 Ultrasonogram of I.V.C. show obstruction above hepatic vein. I.V.C. show by A, hepatic vein B, right atrium C.

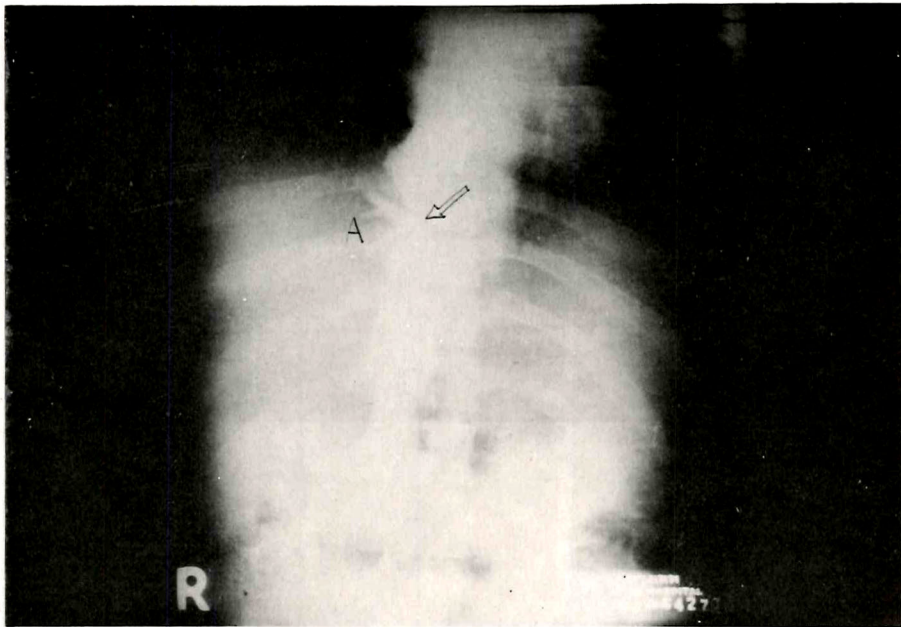


Figure 2 Superior mesenteric angiography show normal finding.

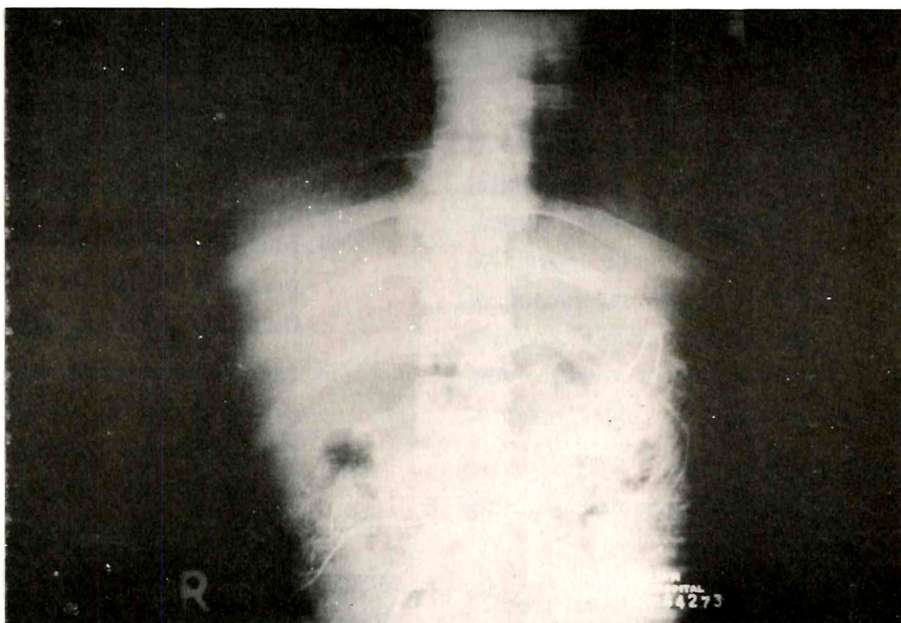


Figure 3 Cavography via right femoral vein and right atrial injection. Arrowed is the membranous obstruction of I.V.C. above hepatic vein. Dilated hepatic vein shown as A.

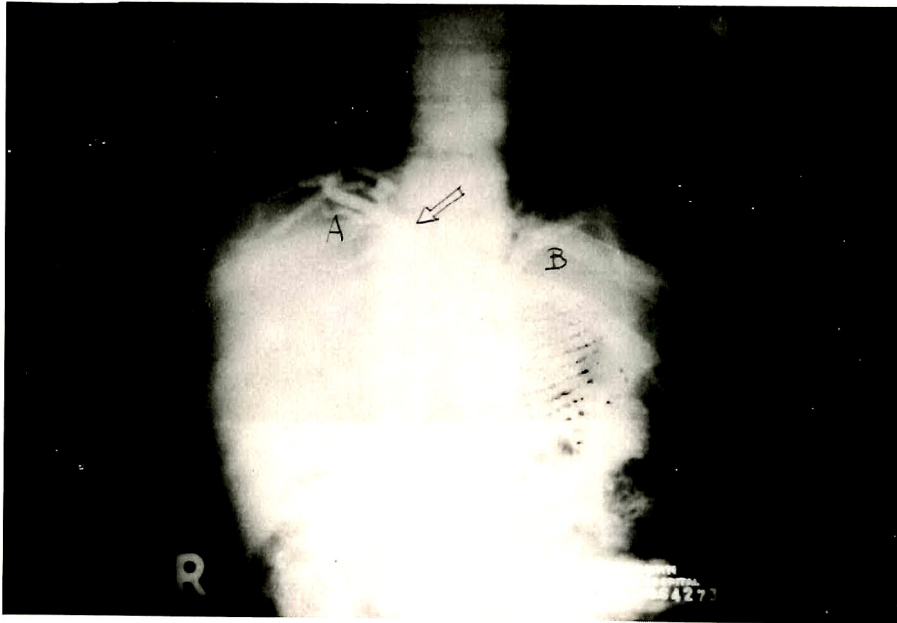


Figure 4 Right Femoral vein cavography shows a membranous obstruction (Arrow). Dilated hepatic vein, retroperitoneal vein shown as A,B.

Discussion

The etiology of the membrane is unknown, but may be a congenital anomaly. Thrombophlebitis may superimpose on the valve. The valvelike membrane in the suprahepatic portion of I.V.C. is known as the "EUSTACHIAN VALVE." The structure is variable and may contain a network, ridge, valve or a combination there of.⁽¹⁰⁾ This valve may be lacerated, inflamed causing thrombosis.

The essentials for a diagnosis are:⁽¹¹⁾

1. Ascending collateral circulation over anterior abdominal and lower chest walls. (Cephalad blood flow)

2. Pitting edema and venous engorgement of lower extremities.
3. Normal cardiac function
4. Marked difference of venous pressures between S.V.C. & I.V.C. (normal in S.V.C., high in I.V.C.)
5. Membranous obstruction can be demonstrated by cavogram with two catheters (above & below the obstructive site.)

Ultrasonography is a non-invasive investigation. The two dimensional echocardiography can be imaged the cardiac structures and unexpected finding of membrane like structure within right atrium.^(13,14,15,16,17)

A collateral circulation occurs via the lumbar, azygos, anterior abdominal wall, lateral thoracic and phrenic veins.^(8,11)

The effective and safe surgical method is transatrial membranotomy

using an extracorporeal circulation.^(7,9,11)

The operative mortality is 37.5%.⁽⁷⁾

Balloon membranotomy should be tried as it may avoid a major operation.^(8,4)

References

1. Bennet IL Jr. Unique case of obstruction of the inferior vena. Bull Johns Hopkins Hosp 1950 Oct; 87 : 290-298
2. Burcheler E, Weber KW. Membranous occlusion of the inferior vena cava. Br J Radiol 1974 Aug; 47(8) : 444-447
3. Suchato C, Kitiyakara K, Arkrawong K. Suprahepatic membranous obstruction of inferior vena cava. J Can Assoc Radiol 1977 Jun; 28(2) : 148-149
4. Eguchi S, Takeuchi Y, Asano K. Successful balloon membranotomy for obstruction of the hepatic portion of the inferior vena cava. Surgery 1974 Nov; 76(5) : 837-840
5. Gips CH. Membranous obstruction of the inferior vena cava as a cause of macronodular cirrhosis. Lancet 1972 Sep 23; 2(7778) : 655-656
6. Hirooka M, Kimura C. Membranous obstruction of the hepatic portion of the inferior vena cava : surgical correction and etiological study. Arch Surg 1970 Jun; 100(6) : 656-665
7. Kimura C, Matsuda S, Koie H, Hirooka M. Membranous obstruction of the hepatic portion of the inferior vena cava : Clinical study of nine cases. Surgery 1972 Oct; 72(4) : 551-559
8. Kimura C, Shirotani H, Hirooka M, Terada M. Membranous obliteration of the inferior vena cava in the hepatic portion. J Cardio Surg 1963 Apr; 4(4) : 87-98
9. Kimura C, Shirotani H, Kuma T. Transcardiac membranotomy for obliteration of the inferior vena cava in the hepatic portion. J Cardio Surg 1962; 3 : 393
10. Powell EDU, Mullaney JM. The chiari network and the valve of the inferior vena cava. Br Heart J 1960 May; 22(3) : 579
11. Boonkasem S, Subhanachart W, Tovanaronte, Kitiyakara K. Chincial Surgery. Proceedings of the Intermedical School Conference at Ramathibodi Hospital. 1980 Jun 6; 1 : 91-96
12. Watkins E Jr, Fortin CL. Surgical correction of a congenital coarctation of the inferior vena cava. Ann Surg 1964 Apr; 159(4) : 536-541

13. Bommer WJ, Kwan OL, Mason DT, DeMaria AN. Identification of prominent eustachian valves by m-mode and two-dimensional echocardiography : differentiation from right atrial masses. *Am J Cardiol* 1980 Feb; 45(2) : 402
14. Gondi B, Nanda Nc. Two-dimensional echocardiographic features of atrial septal aneurysms. *Circulation* 1981 Feb; 63(2) : 452-457
15. Manno BV, Pandis IP, Kotler MN, Mintz GS, Ross J. Two-dimensional echocardiographic detection of right atrial thrombi. *Am J Cardiol* 1983 Feb; 51(2) : 615-616
16. Tajik AJ, Seward JB, Hagler DJ, Mair DD, Lie JT. Two-dimensional realtime ultrasonic imaging of the heart and great vessels : technique, image orientation, structure identification, and validation. *Mayo Clin Proc* 1978 May; 53(5) : 271-303
17. Werner JA, Cheitlin MD, Gross BW, Speck SM, Lvey TD. Echocardiographic appearance of the Chiari network : differentiation from right-heart pathology. *Circulation* 1981 May; 63(5) : 1104-1109