

Catch-up growth in a girl with prolonged autoimmune hypothyroidism complicated by precocious puberty after thyroid hormone replacement

Vichit Supornsilchai*

Chawkaew Kongkanka* Suttipong Wacharasindhu*

Supornsilchai V, Kongkanka C, Wacharasindhu S. Catch-up growth in a girl with prolonged autoimmune hypothyroidism complicated by precocious puberty after thyroid hormone replacement. Chula Med J 2011 May – Jun; 55(3): 253 - 60

Decreased height velocity (HV), one of the clinical manifestations of hypothyroidism which is completely reversed by appropriate thyroid hormone replacement, is called catch-up growth. The objective of this report is to determine the longitudinal growth of a girl with prolonged hypothyroidism due to Hashimoto's thyroiditis complicated by precocious puberty. A 9-year-and-6-month-old girl presented with vaginal bleeding, growth failure and the typical physical signs of hypothyroidism due to Hashimoto's thyroiditis. She received Eltroxin replacement. The height has gained a total of 33 cm during 2 years and 6 months of treatment without additional treatment by GnRHa or any combination of GH and GnRHa. The recent age is 12 years, and her height is 145 cm which is within the target range. A patient with long-standing hypothyroidism, complicated with precocious puberty, has the potential to catch up with their height close to their genetic potential after thyroid hormone replacement alone.

Keywords: *Precocious puberty, hypothyroidism, Hashimoto's thyroiditis.*

Reprint request: Supornsilchai V. Department of Pediatrics, Faculty of Medicine, Chulalongkorn University, Bangkok 10330, Thailand.

Received for publication. August 9, 2010.

วิจิต สุพรศิลป์ชัย, ช่อแก้ว คงการคำ, สุทธิพงศ์ วัชรสินธุ. การเจริญเติบโตของผู้ป่วยเด็กหญิงที่ได้รับการวินิจฉัยเป็นภาวะพร่องไทรอยด์จากอต่อมหมูไทรอยด์ไคติสร่วมกับภาวะเข้าสู่วัยรุ่นก่อนวัย. *จุฬาลงกรณ์เวชสาร* 2554 พ.ศ. – ม.ย.;55(3): 253 – 60

อัตราการเพิ่มความสูงลดลงเป็นอาการแสดงหนึ่งของภาวะพร่องไทรอยด์ ซึ่งสามารถแก้ไขให้กลับมาปกติได้โดยการทดแทนด้วยฮอร์โมนไทรอยด์เรียกภาวะนี้ว่า catch-up growth รายงานผู้ป่วยนี้มีวัตถุประสงค์เพื่อติดตามการเจริญเติบโตในระยะยาวของผู้ป่วยเด็กหญิง ซึ่งได้รับการวินิจฉัยเป็นโรคอต่อมหมูไทรอยด์ไคติสและมีภาวะเข้าสู่วัยสาวเร็วร่วมกับ ผู้ป่วยเด็กหญิงอายุ 9 ปี 6 เดือน มีเลือดออกทางช่องคลอด เต็บโตเข้าร่วมกับมีอาการของภาวะพร่องไทรอยด์ เนื่องจากโรคอต่อมหมูไทรอยด์ไคติสได้รับการรักษาด้วยยาเอลทรอกซิน ความสูงเพิ่มขึ้น 33 ซม. หลังการรักษา 2 ปี 6 เดือน โดยที่ไม่ได้รับการรักษาเพิ่มเติมด้วยฮอร์โมนเจริญเติบโต หรือ GnRH agonist ปัจจุบันอายุ 12 ปี สูง 145 ซม. ซึ่งอยู่ในช่วงของความสูงเป้าหมายทางพันธุกรรม ผู้ป่วยที่มีภาวะพร่องไทรอยด์เป็นระยะเวลานาน และมีภาวะเข้าสู่วัยสาวเร็วร่วมด้วยมีศักยภาพในการเพิ่มส่วนสูงได้ใกล้เคียงกับความสูงเป้าหมายทางพันธุกรรม ถ้าได้รับการทดแทนด้วยฮอร์โมนไทรอยด์เพียงอย่างเดียวในขนาดและเวลาที่เหมาะสม

คำสำคัญ: ภาวะเข้าสู่วัยสาวเร็ว, ภาวะพร่องไทรอยด์, อต่อมหมูไทรอยด์ไคติส.

Prolonged primary hypothyroidism causes a distinct form of isosexual precocity,^(1,2) characterized by breast development, uterine bleeding, and multicystic ovaries in girls,^(3,4) and these can be completely reversed by thyroxine replacement alone. The pathogenesis of precocious puberty in this condition is unclear. In this regard, at least two hypotheses have been postulated. The similarity of the biochemical structure of FSH and TSH, TSH therefore acts through the FSH receptors and stimulates ovaries to produce estradiol. This mechanism is well-known and has been classified as Gonadotropin-induced precocious puberty. The other possibility, low thyroid hormone level in primary hypothyroidism due to a negative feedback response to the hypothalamus then secretes TRH which can also stimulate the gonadotroph to produce gonadotropin. The pathogenesis is similar to that of Gonadotropin-dependent precocious puberty.^(5,6)

Thyroid hormone is an important hormone for normal linear growth. Decreased height velocity (HV) is therefore a clinical manifestation of hypothyroidism which is completely reversed after appropriate thyroid hormone replacement. Catch-up growth is defined as increased linear growth rate greater than that for the age after a period of growth inhibition,⁽⁷⁾ i.e., illness or starvation.⁽⁸⁾ Markedly increased of HV in patients with hypothyroidism after thyroid hormone replacement is a good model for catch-up growth. Chen QW et al reported complete catch-up growth in a 17-year-old man who was lately diagnosed congenital hypothyroidism and only treated with thyroid hormone. His height was increased from 114 cm to 152 cm after that treatment.⁽⁹⁾ However, height gain depends on the duration of hypothyroidism, height deficit at the diagnosis, etiological difference

and the potential for catch-up growth.⁽¹⁰⁾ The age of thyroid hormone replacement is also important for height gain. If the treatment starts before the pubertal period, the height gain is greater. However, the capacity for height gain in patient with juvenile hypothyroidism being treated with thyroid hormone at the peripubertal or pubertal age is maximized with a combination of GH and GnRHa⁽¹¹⁾ or GnRHa replacement alone.⁽¹¹⁻¹⁵⁾

We reported a case of 9-year-old girl presenting with vaginal bleeding, growth failure and other typical physical signs of hypothyroidism due to Hashimoto's thyroiditis. This report demonstrates the catch-up growth of a girl with a long-term period of hypothyroidism complicated by precocious puberty, thirty-three cm of height gain over three years of treatment without GnRHa or any combination of GH and GnRHa. Recently, she was 12 years old and 145 cm tall which is within the genetic target potential.

Case (Fig. 1a)

A 9-year-and-6-month old girl presented with bleeding from the vagina for one week without any history of traumatic injury. Breast buds were not recognized and were hidden by the obesity. She was shorter than her peers of the same age, and her height velocity had deviated from the usual percentile shown in the growth curve (Fig. 2), while her weight had increased since the age of four. Goiter was also retrospectively observed at that time. The developmental milestone had been normal for her age, but her school performance had been poorer than usual since the time the goiter had developed. Cold intolerance, calm behavior and inactivity were also observed.

The physical examination revealed a chubby and pale looking coarse face with generalized dryness of the skin. Her height was 112 cm (<P3) and her weight was 32 kg (P 50 - 75) (Fig. 2). Vital signs showed a blood pressure of 90/65 mmHg and pulse rate of 75 /min with regular pattern. The thyroid gland was diffusely enlarged. The breasts had developed to Tanner stage III without galactorrhea (Fig.1). Fundoscopy showed no papilledema, and the confrontation test of visual field was normal.

The thyroid function test revealed FT4 of 0.04 ng/dL and TSH > 100 μ U/mL. The antithyroglobulin antibody and antithyroid peroxidase antibody were 1:2,560 and 1:6,400, respectively. The FSH level was 4.4 IU/L, LH 0.1 IU/L, estradiol 81.3 pmol/L and prolactin 23.6 ng/mL. The biochemical finding revealed cholesterol of 399, triglyceride 213, HDL 45, LDL 342 mg/mL, SGOT 69, SGPT 77, and alkaline phosphatase 105 U/L. The bone age was 4 years and 2 months old according to the Greulich and Pyle method. Hip AP view showed an irregular surface of

metaphysis with an erosion of the greater trochanter (Fig. 3a). Pelvic ultrasound found a large ovarian cyst of 69 X 65 X 67 mm³ in size at the Rt and 62 X 70 X 62 mm³ in size at the Lt (Fig. 3b). The chest X-ray revealed a normal heart size and EKG found no mosque sign. The lateral view of the skull X-ray showed a widening of the sella turcica without erosion (Fig. 3c). A CT brain scan revealed a pituitary enlargement (Fig. 3d). Hashimoto's thyroiditis was diagnosed with secondary pituitary gland enlargement and ovarian cysts. Eltroxin was prescribed, starting with a low dose and titrated upwards while keeping up to the normal range. She had an onset and a regular cycle of menstruation at the age of 10 years and 10 months old. The Tanner degree of breast development was at stage IV and the bone age was 11 years by the Gleulich and Pyle method. At a recent visit, her height was 145 cm and the bone age was 15 years old. Her target height is 143 -158 cm.

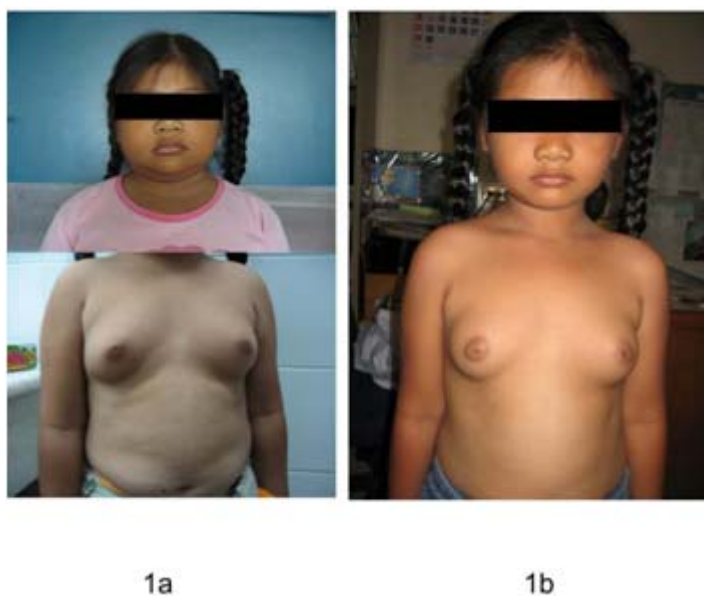

Figure 1. The appearance of the patient at diagnosis of Hashimoto's thyroiditis (a) and 3 months of thyroid hormone replacement (b).

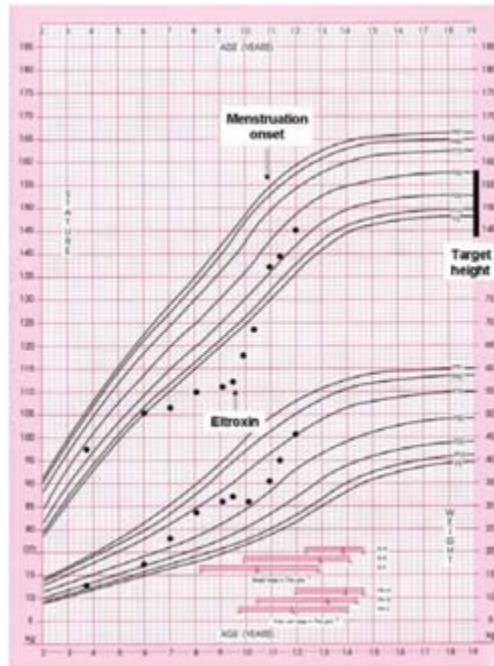


Figure 2. Longitudinal growth curve of the patient after thyroid hormone replacement.

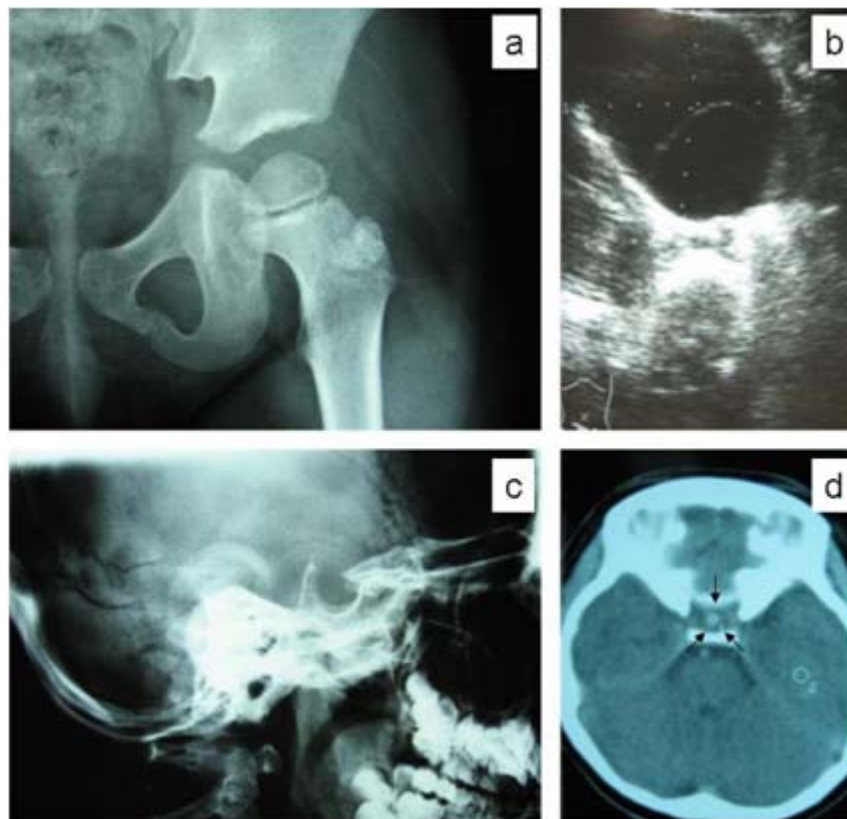


Figure 3. The secondary changes due to long-term untreated primary hypothyroidism revealed an irregularity of metaphysis (a), ovarian cysts (b), a widening of Sella turcica (c) and pituitary enlargement (d).

Discussion

We report a patient with Hashimoto's thyroiditis who had grown well since birth, and whose developmental milestones were appropriate for her age until goiter developed with the signs and symptoms of hypothyroidism including inactivity, constipation, poor school performance, increased weight and height deviation, at the age of four. Unfortunately, she had not received any appropriate treatment for the condition until vaginal bleeding developed at 9 years and 6 months of age. The secondary changes from the long-term negative feedback mechanism to the pituitary gland and hypothalamus showed as the pituitary gland enlarged and the sella turcica widened.⁽¹⁶⁾

Hashimoto's thyroiditis was diagnosed according to markedly antithyroglobulin and antithyroid peroxidase antibody elevation. Thyroxine replacement had been started on a low dose and an adjusted dose, to keep the thyroid function test normal. The sequence of the clinical response was similar to that of a previous report.⁽¹⁷⁾ After replacement, the vaginal bleeding disappeared within 3 days and the clinical hypothyroidism including cold intolerance and inactivity improved within one month. The thyroid function test turned normal within two months. Height and weight changed to their usual percentile, and her shape became normal as shown in Fig. 2 and 1b. Magnetic resonance imaging showed a pituitary gland of normal size within 6 months.⁽¹⁸⁻²¹⁾ The ovarian cysts completely disappeared within a few months and did not need any surgery.⁽²²⁻²⁶⁾ Breast tissue was unable to regress completely as in the report due to the more advanced stage of the breast Tanner and her relative obesity⁽⁵⁾ (Fig. 1b).

Catch-up growth in hypothyroidism depends on the duration of the hypothyroidism, the height deficit at diagnosis, etiological difference, and the potential for catch-up growth⁽¹⁰⁾ as well as the age at the onset of treatment.⁽⁷⁾ Raul M *et al.* studied the mechanism of catch-up growth by looking at the growth plate changes in rats at 8 weeks of treatment with Propylthiouracil (PTU) to induce hypothyroidism and after discontinuation of PTU. They concluded that hypothyroidism conserved the limited proliferative capacity of the growth plate chondrocytes called growth plate senescence and the chondrocytes would be growing compensation after a period of growth inhibition.⁽⁷⁾ Our case was complicated by precocious puberty that is well-known to compromise with the final height. Some authors suggested that the administration of GnRHa or combined GH and GnRHa in patients who have hypothyroidism with signs of puberty will improve final height.⁽¹¹⁻¹⁵⁾ However, GnRHa is not able to correct all the pathophysiological process of precocious puberty caused by hypothyroidism and it is costly and inconvenient. The height gain in our patient was 12 cm in the 1st year, 15 cm in the 2nd year and 6 cm in the 3rd year. The twelve cm gained over the 1st year of treatment was by the effect of thyroid hormone; the 15 cm gained in the 2nd year by the effect of thyroid and sex hormone; and the remaining 6 cm gained in the 3rd year by the late pubertal growth, after the onset of menstruation. The patient had a total of 33 cm of height gain without any additional treatment with GnRHa or a combination of GH and GnRHa. In conclusion, patients with long-standing hypothyroidism complicated by precocious puberty have the potential to catch up their height close to their genetic potential after thyroid hormone replacement alone without any additional treatment.

Acknowledgements

We would like to thank the patient and her family for participation in the study. We are grateful to every fellow of the Endocrine Unit, especially Dr.Yodporn Hiranras, Dr.Chansuda Bongsebandhuphubhakdi and Dr. Voraluk Phatarakijrurund, for taking care of the patient.

References

1. Fisher DA. The thyroid. In: Kaplan SA, ed. Clinical pediatric endocrinology. 2nd ed. Philadelphia: Saunders, 1990: 87-126
2. Barnes ND, Hayles AB, Ryan RJ. Sexual maturation in juvenile hypothyroidism. Mayo Clin Proc 1973 Dec;48(12):849-56
3. Costin G, Kershner AK, Kogut MD, Turkington RW. Prolactin activity in juvenile hypothyroidism and precocious puberty. Pediatrics 1972 Dec;50(6):881-9
4. Lindsay AN, Voorhess ML, MacGillivray MH. Multicystic ovaries detected by sonography. Am J Dis Child 1980 Jun;134(6):588-92
5. Niedziela M, Korman E. Severe hypothyroidism due to autoimmune atrophic thyroiditis predicted target height and a plausible mechanism for sexual precocity. J Pediatr Endocrinol Metab 2001 Jul-Aug;14(7):901-7
6. Anasti JN, Flack MR, Froehlich J, Nelson LM, Nisula BC. A potential novel mechanism for precocious puberty in juvenile hypothyroidism. J Clin Endocrinol Metab 1995 Jan;80(1):276-9
7. Marino R, Hegde A, Barnes KM, Schrier L, Emons JA, Nilsson O, Baron J. Catch-up growth after hypothyroidism is caused by delayed growth plate senescence. Endocrinology 2008 Apr;149(4):1820-8
8. Ranke MB. Catch-up growth: new lessons for the clinician. J Pediatr Endocrinol Metab 2002 Dec;15 Suppl 5:1257-66
9. Chen GW, Huang HS, Wang PW, Lin JD, Huang BY, Huang MJ. Growth catch-up in the case of congenital hypothyroidism after delayed treatment –a case report. Chang Yi Xue Za Zhi 1990 Jun 20;13(2):125-33
10. Ozgen T, Guven A, Aydin M. Precocious puberty in a girl with Down syndrome due to primary hypothyroidism. Turk J Pediatr 2009 Jul-Aug; 51(4):381-3
11. Quintos JB, Salas M. Use of growth hormone and gonadotropin releasing hormone agonist in addition to L-thyroxine to attain normal adult height in two patients with severe Hashimoto's thyroiditis. J Pediatr Endocrinol Metab 2005 May;18(5):515-21
12. Rivkees SA, Bode HH, Crawford JD. Long-term growth in juvenile acquired hypothyroidism: the failure to achieve normal adult stature. N Engl J Med 1988 Mar 10;318(10):599-602
13. Boersma B, Otten BJ, Stoelinga GB, Wit JM. Catch-up growth after prolonged hypothyroidism. Eur J Pediatr 1996 May; 155(5):362-7
14. Chiesa A, Gruneiro de Papendieck L, Keselman A, Heinrich JJ, Bergada C. Final height in long-term primary hypothyroid children. J Pediatr Endocrinol Metab 1998 Jan-Feb; 11(1):51-8
15. Teng L, Bui H, Bachrach L, Lee P, Gagn N, Deal C, Wilson DM. Catch-up growth in

- severe juvenile hypothyroidism: treatment with a GnRH analog. *J Pediatr Endocrinol Metab* 2004 Mar;17(3):345-54
16. Khawaja NM, Taher BM, Barham ME, Naser AA, Hadidy AM, Ahmad AT, Hamamy HA, Yaghi NA, Ajlouni KM. Pituitary enlargement in patients with primary hypothyroidism. *Endocr Pract* 2006 Jan-Feb;12(1):29-34
17. Radaideh AM, Nusier M, El-Akawi Z, Jaradat D. Precocious puberty with congenital hypothyroidism. *Neuro Endocrinol Lett* 2005 Jun;26(3):253-6
18. Singh SK, Singh R, Maurya VK. Isolated menarche and multicystic ovaries in a 7(1/2)-year- girl with hypothyroidism. *Indian Pediatr* 2001 Dec;38(12):1431-2
19. Lindsay AN, Voorhess ML, MacGillivray MH. Multicystic ovaries detected by sonography. *Am J Dis Child* 1980 Jun;134(6):588-92
20. Desai MP, Mehta RU, Choksi CS, Colaco MP. Pituitary enlargement on magnetic resonance imaging in congenital hypothyroidism. *Arch Pediatr Adolesc Med* 1996 Jun;150(6):623-8
21. Chemaitilly W, Thalassinis C, Emond S, Thibaud E. Metrorrhagia and precocious puberty revealing primary hypothyroidism in a child with Down's syndrome. *Arch Dis Child* 2003 Apr;88(4):330-1
22. Chattopadhyay A, Kumar V, Marulaiah M. Polycystic ovaries, precocious puberty and acquired hypothyroidism: The Van Wyk and Grumbach syndrome. *J Pediatr Surg* 2003 Sep;38(9):1390-2
23. Takeuchi K, Deguchi M, Takeshima Y, Maruo T. A case of multiple ovarian cysts in a prepubertal girl with severe hypothyroidism due to autoimmune thyroiditis. *Int J Gynecol Cancer* 2004 May-Jun;14(3):543-5
24. Campaner AB, Scapinelli A, Machado RO, Dos Santos RE, Beznos GW, Aoki T. Primary hypothyroidism presenting as ovarian tumor and precocious puberty in a prepubertal girl. *Gynecol Endocrinol* 2006 Jul;22(7):395-8
25. Sharma Y, Bajpai A, Mittal S, Kabra M, Menon PS. Ovarian cysts in young girls with hypothyroidism: follow-up and effect of treatment. *J Pediatr Endocrinol Metab* 2006 Jul;19(7):895-900
26. Indumathi CK, Bantwal G, Patil M. Primary hypothyroidism with precocious puberty and bilateral cystic ovaries. *Indian J Pediatr* 2007 Aug;74(8):781-3