

Filtration Surgery with twisted Double Polypropylene Suture loop implant in Glaucoma.

Chaiyen Ratnavijarn*

Ratnavijarn C. Filtration Surgery with twisted Double Polypropylene Suture loop implant in Glaucoma. Chula Med J 1986 Feb ; 30 (2) : 167-171

Glaucoma which responds poorly to both medical and repeated surgical managements, is considered one of the most difficult forms of glaucoma to control. Filtration surgery with twisted double polypropylene loop implant was performed in two of these cases. The device, consisting of two double arm 6-0 polypropylene sutures twisted together and as a double loop, was inserted at the corneoscleral limbus 2-3 mm. into the anterior chamber with the remaining sutures lying under the scleral flap. Post-operatively, up to the time of report, the intra-ocular pressures have been under satisfactory control for over twelve and six months, in the first and second cases respectively.

ชัยเอนทร์ รัตนาวิจารย์. Filtration Surgery with twisted Double Polypropylene Suture loop implant in Glaucoma. จุฬาลงกรณ์เวชสาร 2529 กุมภาพันธ์ : 30(2) : 167-171

โรคต้อหินที่ไม่สามารถรักษาความดันลูกตาให้ลดลงด้วยการให้ยาใด ๆ รวมทั้งให้การผ่าตัดแล้วถึง 2-3 ครั้ง ถือว่าเป็นต้อหินจำพวกที่รักษายากมาก เราพบว่าการผ่าตัดครั้งต่อไปจะได้ผลดีเมื่อใช้เส้นด้ายโพลีโพรไพลีนสองเส้นขั้วและทำเป็นห่วง แล้วใส่คาไว้ในแผลที่ทำผ่าตัดระหว่างคอร์เนียกับตาขาวเข้าไปในช่วงตาดำหน้า 2-3 มม. ในการทำผ่าตัดฟิลเตอร์ริง เราได้ทำผ่าตัดแบบนี้ในผู้ป่วย 2 ราย และพบว่าความดันลูกตาคงอยู่ในระดับปกติดีหลังผ่าตัดจนถึงเวลารายงานนี้เป็นเวลา 1 ปี และ 6 เดือน ตามลำดับ

Filtering surgery for primary open-angle glaucoma is reasonably successful, However about 20% of such procedures ultimately fail.⁽¹⁾ In the past many investigators⁽²⁻⁴⁾ have employed implants of various kinds in the attempt to maintain the opening for aqueous humor to be drained out of the anterior chamber.

Historical Review

Zorab 1912⁽⁵⁾ inserted silk loop through a superior keratome incision 5 mm. from behind the limbus and covered it with a conjunctival flap. Later, Mayou⁽⁶⁾ 1912, Wood⁽⁷⁾ 1915, vail⁽⁸⁾ 1915, Wolffe and Blaess⁽⁴⁾ 1936 repeated Zorab's technique with modifications and supported his results.

Weekers⁽⁴⁾ 1922 used a hollow gold cuff 2.0×1.5 mm; Stefansson⁽⁹⁾ 1925 inserted a T-shape piece of gold, while Tron-soco,⁽¹⁰⁾ 1940 used a mangesium sheet implant and Bick⁽¹¹⁾ 1949 a tantalum tube. Muldoon⁽¹²⁾ 1951 employed a platinum wire and Haberberger⁽¹³⁾ 1951 inserted a proto-plast loop through an Elliot trephine hole. Loche⁽¹⁴⁾ 1952 and Strampelli⁽¹⁵⁾ 1956 used supramid thread, Qadeer⁽¹⁶⁾ 1954 an acrylic plate and Teulieres⁽¹⁷⁾ 1956 catgut to suture one side of the scleral wound. Laval⁽¹⁸⁾ 1955 used gelatin (Gelfilm) and was opposed by Barky and Schimek⁽¹⁹⁾ 1958 who reported that gelation caused a prolonged post-operative reaction, scarring and fibrosis which obliterated the opening, later confirmed by Mc. Gaslin⁽²⁰⁾ 1959.

The complications arising from the use of these various seton operations included erosion, keratitis, iritis, iris atrophy, dislocation of the implant, severe inflammatory reaction, scar formation and blockage of the filtration. The basic problem was the toxicity of the material and the migration of the implant.

Present Study

We tried to eliminate these problems by using a # 6-0 polypropylene suture which has been employed as suture and suspensory haptic for intraocular lens for years, as it caused least reaction to the surrounding tissues⁽²¹⁾. The loop of double polypropylene suture was inserted at the corneoscleral limbus 2-3 mm. into the anterior chamber to create a permanent double channel for aqueous out-flow from the anterior chamber. Since in the nature of the healing process, tissue growth usually occurs in a flat pattern, it has the tendency not to project into the angular channel as created between and along the double sutures. For this reason the channel is expected to be permanent. (Fig. 1)

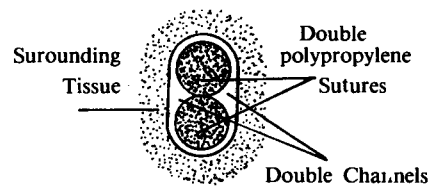


Figure 1 Showing the cross-section of the double polypropylene sutures the surrounding tissue, the double channels created along the sides of the double sutures.

Surgical procedure

Surgery was performed with an operating microscope. Under local anesthesia (O'Brien and retrobulbar injections), a bridle suture was placed in the superior rectus muscle. A conjunctival flap, 6 to 8 mm. from and parallel to the limbus superiorly was turned down over the cornea to expose the corneoscleral limbus. A 4×4 mm. scleral flap. one half to two third of the scleral thickness and hinged at the corneoscleral limbus, was made with blade

(No. 15). The lamella dissection was carried into the clear cornea where entry into the anterior chamber was performed by a keratome (No. 55 Beaver). This incision was parallel to the plane of the iris. Two double-arm 6-0 polypropylene twisted sutures were inserted as a loop into the keratome incision, about 2-3 mm. into the anterior chamber. Both distal ends of the looped sutures, lying on the scleral dissection bed where sutures were buried into the sclera, medially and laterally accordingly (Fig. 2-3) The scleral flap was reapproximated with interrupted 8-0 vicryl sutures. The conjunctival flap was closed with continuous 8-0 vicryl sutures.




Figure 2 Twisted double 6-0 polypropylene sutures.

Two patients with uncontrolled glaucoma.

Preoperative the two patients, both having twice failed at filtering surgery, were put on maximum medications to control the tension. Twisted 6-0 polypropylene double sutures were implanted into the two glaucoma eyes which had failed to respond medically and surgically.

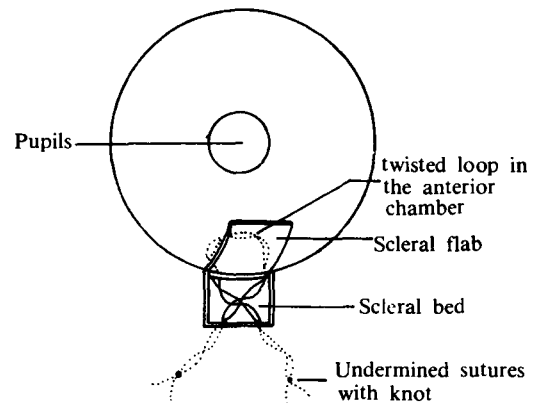


Figure 3 twisted double 6-0 polypropylene sutures implanted in the anterior chamber through the corneoscleral opening in filtering operation.

Case Report

Case 1-a 45 year-old Thai lady had traumatic recess angle glaucoma. She had an 8-ball traumatic hyphema which was cleared by paracentesis. Subsequently she developed a recess angle glaucoma which could not be controlled by medications nor two filtering operations. Pre-operatively she had a tension of 30-40 mmHg. Visual acuity and visual field could not be assessed because of some vitreous hemorrhage, and the fundus could not be clearly seen. A loop of two twisted 6-0 polypropylene sutures was inserted in the anterior chamber which brought the intraocular tension down to 16 mmHg. post operatively. The intraocular tension varied between 16-20 mmHg. during the post operative follow up of over twelve months without glaucoma medication. Slit lamp gonioscopy found no sign of iritis but minimal deposits on the suture loop.

Case 2

A 26 month old Thai girl had congenital glaucoma. The corneal diameters

were 14 mm. (right eye) and 11 mm. (left eye) with total opacities of the entire cornea; the anterior chamber could not be visualized. Intraocular tension was 30 mmHg. (right) and 16 mmHg. (left). Filtering operations were done twice on the right eye, but the intraocular pressure had not improved. A loop of twisted double polypropylene suture was inserted into the anterior chamber of the right eye about 2-3 mm. from the limbus in the third filtering operation. Post-operatively the corneal diameter came down to 11 mm. However, the haziness of the cornea remained the same despite a decrease in the ocular tension to below 18 mmHg. The corneal diameter of this eye had maintained the same size of 11 mm. for more than six months post-operatively and at the time of this report without glaucoma medications.

Discussion

Unfavorable results of glaucoma filtering operations in general are caused mostly by obliteration of the sclerotomy opening because of scar formation. However the twisted double 6-0 polypropylene suture loop implant provides, a not too large

and not too small, as well as expectingly permanent aqueous out-flow double channel from the anterior chamber. Tissue growth had not been found to obstruct the double channel. The implant was well tolerated with minimal sign of deposits on the loop in gonioscopy in the first case but not visualisable in the second case because of corneal opacity.

Summary

A twisted double 6-0 polypropylene suture loop implant can be inserted into the corneoscleral filtering opening in order to keep it as a permanent channel in a glaucoma patient who had failed to respond to several glaucoma surgeries. The implant was used in two cases of medically and surgically uncontrollable glaucoma. In the first case of traumatic recers-angle glaucoma, the intraocular pressure came down to within normal range for over one year. In the second case, a congenital glaucoma, the tension has been well controlled and the corneal diameter decreased to normal size for more than six months. Up to the time of this report.

References

1. Krupin T, Podos SM, Becker B. Valve implants in filtering surgery. *Am J Ophthalmol* 1976 Feb; 81 (2) : 232-235
2. MacDonald RK, Pierce HF. Silicone setons. *Am J Ophthalmol* 1965 Apr; 59 (4) : 635-646
3. Molteno ACB. New implant for drainage in glaucoma. *Br J Ophthalmol* 1969 Sep; 53 (9) : 606-615
4. Ellis RA. Reduction of intraocular pressure using plastics in surgery. *Am J Ophthalmol* 1960 Nov; 50 (5 pt 1) : 733-743
5. Zorab A. The Reduction of Tension in Chronic Glaucoma. *Ophthalmoscope* 1912; 10 : 258-261
6. Mayou MS. An operation for glaucoma : A preliminary note. *Ophthalmoscope* 1912; 10 : 254-257
7. Wood CA. Aqueoplasty : Or the Zorab operation for glaucoma. *Ophth Rec* 1915; 24 : 179-183
8. Vail DT, Sr. Retained silk-thread or

- “seton” drainage from the vitreous chamber to Tenon’s lymph channel for the relief of glaucoma. *Ophth Rec* 1915; 24 : 184-186
9. Stefansson J. An operation for glaucoma. *Am J Ophth* 1925; 8 : 681-693
 10. Troncoso UM. Cyclodialysis with insertion of a metal implant in the treatment of glaucoma : a preliminary report. *Arch Ophth* 1940 Feb; 23 : 270
 11. Bick MW. Use of tantalum for ocular drainage. *Arch Ophthalmol* 1949 Oct; 42 (4) : 373-388
 12. Muldoon WE, Ripple PH. Platinum implant in glaucoma surgery. *Arch Ophthalmol* 1951 Jan; 45 (1) : 666-672
 13. Haberberger. Einlegen einer Protoplastose bei fistelbildender Glaukoperation. *Wien Klin Wchnschr* 1951; 63 : 210
 14. Losche W. Vorschläge zue Verbesserung der Zyklodialyse. *Klin Monatsbl f. Augenh* 1952; 121 : 715-716
 15. Strampelli B. Ciclodialisi durature mediants filodi supramid in trazione permanente. *Ann Ottol Clin Ocul* 1956 Apr, 82 : 186-187
 16. Qadeer SA. Acrylic gonio-subconjunctival plates in glaucoma surgery. *Br J Ophthal* 1954 Jun; 38 : 353-358
 17. Teulieres MJ Cyclodialyse et filtration. *Bull Soc Ophth Franc* 1956; 10 : 942-943
 18. Laval J. The use of absorbable gelatin film (Gelfilm) in glaucoma filtration surgery. *Arch* 1955 Nor; 54 (5) : 677-682
 19. Barsky D, Schimek RA. Evaluation of absorbable gelatin film (Gelfilm) in cyclodialysis defts. *Arch Ophthalmol* 1958 Dec; 60 (6) : 1044-1052
 20. Lehman RN, McCaslin MF. Gelatin film used as a seton in glaucoma. *Am J Ophthalmol* 1959 May; 47 (5 pt 1) : 690-693
 21. Frados J ed. *Plastic Engineering Handbook*. New book : Van Nostrand Reinhold, 1976. 64