

## Isolated histoplasmosis of the tongue: A case report

Prattana Sittiwattanawong\*

Marisa Pongprutthipan\*

**Sittiwattanawong P, Pongprutthipan M. Isolated histoplasmosis of the tongue: A case report. Chula Med J 2018 Jan – Feb;62(1): 39 - 44**

*Histoplasmosis is an endemic, systemic mycosis caused by *Histoplasma capsulatum*. Clinical manifestations are various depending on immunity status. We reported a case of isolated histoplasmosis of the tongue. A 48-year-old Thai woman, steroid-dependence systemic lupus erythematosus, presented with rapid-growing, painful mass on the right lateral aspect of the tongue without systemic symptoms. Histologic examination confirmed the diagnosis of histoplasmosis and tissue culture identified *Histoplasma capsulatum*. The patient received oral itraconazole for 6 months until the lesion was completely healed. The oral lesions of histoplasmosis could be a part of localized form or disseminated form. We should investigate for possible dissemination or any pulmonary involvement due to different prognosis and treatment plan in the patient with oropharyngeal lesion presentation.*

**Keywords:** *Histoplasmosis of the tongue, oral histoplasmosis.*

Correspondence to: Pongprutthipan M. Department of Medicine, Faculty of Medicine,  
Chulalongkorn University and King Chulalongkorn Memorial Hospital,  
Bangkok 10330, Thailand.

Received for publication. September 28, 2017.

ปรารณา สิทธิวัฒนวงศ์, มาริษา พงศ์พฤตพันธ์. การติดเชื้อฮิสโตพลาสโมซิสเฉพาที่ลิ้น:  
รายงานผู้ป่วย 1 ราย. จุฬาลงกรณ์เวชสาร 2561 ม.ค. – ก.พ.;62(1): 39 – 44

ฮิสโตพลาสโมซิส (*Histoplasmosis*) คือ โรคที่เกิดจากการติดเชื้อรา *Histoplasma capsulatum* อาการแสดงทางคลินิกมีได้หลากหลายขึ้นกับภาวะภูมิคุ้มกันของผู้ป่วย รายงานนี้นำเสนอผู้ป่วยที่ติดเชื้อ ฮิสโตพลาสโมซิสเฉพาที่ลิ้น ผู้ป่วยหญิงไทยอายุ 48 ปี มีโรคประจำตัวเป็นลูปัส อิริทีมาโตซัส รักษาด้วยยาสเตรอยด์มาด้วยก้อนเจ็บโตเร็วที่บริเวณด้านขวาของลิ้นและไม่มีอาการผิดปกติอื่น ๆ ผลตรวจทางพยาธิวิทยาพบเซลล์อักเสบและยีสต์อยู่ในชั้นใต้เยื่อบุลิ้นผล เพาะเชื้อพบ *Histoplasma capsulatum* ได้รับการรักษาด้วยยา itraconazole รับประทานนาน 6 เดือน จนกระทั่งรอยโรคหายทั้งหมด รอยโรคฮิสโตพลาสโมซิสในช่องปากเป็นอาการแสดงของการติดเชื้อฮิสโตพลาสโมซิสได้ทั้งชนิดเฉพาที่และการติดเชื้อชนิดแพร่กระจาย การตรวจเพิ่มเติมเพื่อหาการแพร่กระจายของฮิสโตพลาสโมซิสโดยเฉพาที่ปอดหรืออวัยวะต่าง ๆ เป็นสิ่งสำคัญ เนื่องจากมีผลต่อพยากรณ์โรคและการรักษา

**คำสำคัญ :** ฮิสโตพลาสโมซิสที่ลิ้น, ฮิสโตพลาสโมซิสในช่องปาก.

Histoplasmosis is of high prevalence in Thailand especially in the symptoms of histoplasmosis depending on T-cell mediated immune status. There are 3 main forms of histoplasmosis that include acute pulmonary, chronic pulmonary and disseminated form. The oral form of histoplasmosis could be localized or a part of pulmonary or disseminated infection. This report presents a case of localized form of histoplasmosis, which is uncommon.

### Case Report

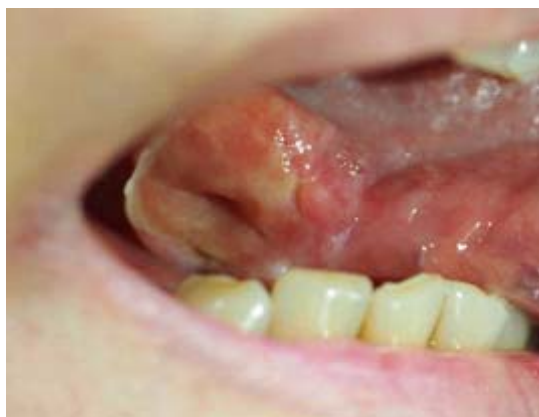A 48-year-old Thai woman, a housekeeper in Bangkok, presented with a progressive rapid-growing, painful mass on the right lateral aspect of the tongue for 2 months (Figure 1). She denied any fever, weight loss or other systemic symptoms. She has never experienced any trauma or surgery in the oropharynx. She was diagnosed with systemic lupus erythematosus with chronic polyarthritis and steroid dependence for 11 years and hypertension for 3 years. Her current medications were: prednisolone 7.5 mg/day, hydroxychloroquine 125 mg/day, enalapril 20 mg/day and atenolol 50 mg/day.

On physical examination, the patient was Cushingoid in appearance. Oral examination revealed a solitary, well defined, erythematous, fungating ulcer with elevated heaped-up margin, size 3.5 X1.0 cm, along right lateral aspect of the tongue. No lymphadenopathy or hepatosplenomegaly were detected. The lungs were clear.

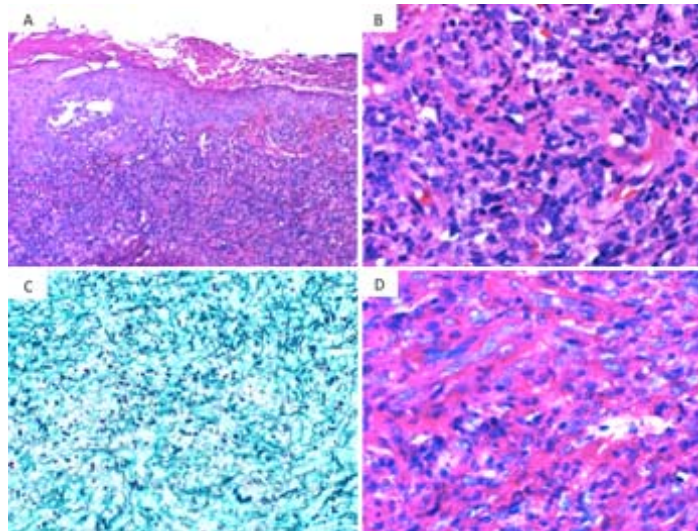
The complete blood count, liver function test, anti-HIV antibody test and chest X-ray were within normal limits. Hemoculture for fungus was negative.

The histologic examination from incisional biopsy showed mucosal epithelium with ulcer, hyperkeratosis and neutrophilic collection. There is dense inflammatory infiltrate, predominantly lymphohistiocytes in the entire submucosal layer. Periodic acid-Schiff (PAS) and Gomori's methenamine silver (GMS) stained sections reveal numerous intracellular yeast cells in the entire submucosal layer. Tissue culture was identified *Histoplasma capsulatum*.

The patient received oral itraconazole 400 mg per day for 6 months until the lesion was completely cured.



**Figure 1.** Clinical overview picture; A fungating ulcer on right lateral aspect of the tongue.



**Figure 2.** Representative photomicrographs of skin biopsy (A - D); A., B. Hematoxylin-eosin stain; C. Grocott-Gomori's methenamine silver (GMS) stain; D. Periodic acid-Schiff (PAS) stain (original magnification: A x 100, B x 400, C x 400, D x 400).

## Discussion

*Histoplasma capsulatum* is a dimorphic fungus, grow well in the bat or avian excreta and found in the contaminated soil.<sup>(1)</sup> Infection by *Histoplasma capsulatum* has been reported in many endemic areas around the world. The prevalence of histoplasmin skin test which demonstrated past infection range from 4.8 - 34.4% across Thailand which higher prevalence rate are shown in the central and southern areas.<sup>(2)</sup>

The portal of infection usually through the inhalation of the microconidia and change to pathogenic yeast form in alveolar macrophage. Initially during the pre-immune phase, the dissemination of fungus occurred in immunocompetent patient, symptoms may similar to influenza<sup>(3)</sup> or asymptomatic.<sup>(4)</sup> Once specific Th1-cell mediated immune response developed, the immunity restricts the infection into quiescent state. Once T-cell defect immune status occurs, the exacerbation of hidden infection is triggered and turn to dissemination.<sup>(4)</sup> The immunosuppressed state, well-known to associate

with histoplasmosis in Thailand, is HIV infection; the others immune suppressed conditions include organ transplantation patients with immunosuppressive therapy, autoimmune diseases and congenital T-cell are also the risk factors.<sup>(5)</sup>

Cutaneous manifestations of histoplasmosis are described into 3 forms. First, the lesions associated with the invasion of the pathogen can manifest as direct inoculation or disseminated infection. The direct inoculation usually presents as localized nodule, abscess or indurated ulcer with local lymphadenopathy. Cutaneous dissemination is observed in 38% to 85% of the cases,<sup>(6)</sup> it is more common among patients with acquired immune deficiency syndrome (AIDS).<sup>(7)</sup> The presence of oral and cutaneous lesions associated with histoplasmosis in AIDS patients is more frequent at the later stages of HIV infection and indicates poor prognosis.<sup>(8)</sup> The lesion is commonly found in disseminated form; it varies from papules, plaques, pustules, nodules, punch-out ulcer and molluscum-like lesion.<sup>(5, 8, 9)</sup> The

second form is the inflammatory reaction to the infection that manifest as erythema nodosum. The third presenting form is caused by the dissemination of histoplasmosis to the adrenal gland which would be presented as hypoadrenalism, i.e. Addisonian hyperpigmentation.

Theoropharyngeal histoplasmosis could manifest as a localized form and a part of disseminated form. Some publications suggested that oral histoplasmosis is the presenting sign of disseminated form and HIV infection especially non-healing ulcer<sup>(10-13)</sup> which may similar to skin neoplasm especially squamous cell carcinoma.<sup>(11, 14)</sup> Oral mucosal lesions are observed in 30% to 60% of patients with histoplasmosis, and some of them (25 - 45%) are local manifestations from the pulmonary or chronic disseminated form of the disease.<sup>(9)</sup> These lesions are nodular, ulcerative, granulomatous, plaque-like or vegetative lesions, which are commonly associated with pain.<sup>(12, 15)</sup> Predilection for oropharyngeal lesions are gingiva, tongue, palate, lips and the larynx.<sup>(16)</sup> Isolated oral fungating ulcer in non-HIV patient is considered uncommon, the similar lesion has been reported in immunocompetent patient by de Paulo LF.<sup>(17)</sup>

The diagnosis was made in this patient by histopathological exam and also the tissue culture for fungus, which identified *Histoplasma capsulatum* in a few weeks later. Other laboratories and chest X-ray showed no evident of dissemination.

*Histoplasma* yeasts are highly susceptible to itraconazole, with low minimum inhibitory concentration (<0.01 µg/mL) in all strains tested. Therefore, itraconazole is recommended in mild to moderate severity in the Infectious Diseases Society

of America latest guideline.<sup>(18)</sup> In our patient, 6-month of raconazole treatment was given until resolution of the lesion which longer than recommended 12-weeks periods. Even though, this patient is still concurrently taking prednisolone, she had no relapse after 1-year follow up. Prognosis is directly related to the severity and patient's health status which may vary.<sup>(19)</sup>

### Conclusion

Histoplasmosis is one of the common infection in Thailand, one of the endemic areas in the world. The oral presentation of oral mass or non-healing ulcer is more common in histoplasmosis than the other systemic mycoses. The presentation of oral lesion included non-healing ulcer, nodular and vegetative plaque could be a part of localized form or disseminated form of histoplasmosis infection. The patient should be examined for possible disseminated form or any pulmonary involvement.

### References

1. Norkaew T, Ohno H, Sriburee P, Tanabe K, Tharavichitkul P, Takarn P, et al. Detection of environmental sources of *Histoplasma capsulatum* in Chiang Mai, Thailand, by nested PCR. *Mycopathologia* 2013;176: 395-402.
2. Taylor RL, Duangmani C, Charoenvit Y. The geographic distribution of histoplasmin sensitivity in Thailand. *Am J Trop Med Hyg* 1968;17:579-83.
3. Folk GA, Nelson BL. Oral Histoplasmosis. *Head Neck Pathol* 2017 Feb 20. doi: 10.1007/s12105-017-0797-y.
4. Bahr NC, Antinori S, Wheat LJ, Sarosi GA.

- Histoplasmosis infections worldwide: thinking outside of the Ohio River valley. *Curr Trop Med Rep* 2015;2:70-80.
5. Kauffman CA. Histoplasmosis: a clinical and laboratory update. *Clin Microbiol Rev* 2007; 20:115-32.
  6. Moreno-Coutino G, Hernandez-Castro R, Toussaint-Caire S, Montiel-Robles M, Sanchez-Perez FS, Xicohtencatl-Cortes J. Histoplasmosis and skin lesions in HIV: a safe and accurate diagnosis. *Mycoses* 2015;58:413-5.
  7. Tobon AM, Agudelo CA, Rosero DS, Ochoa JE, De Bedout C, Zuluaga A, et al. Disseminated histoplasmosis: a comparative study between patients with acquired immunodeficiency syndrome and non-human immunodeficiency virus-infected individuals. *Am J Trop Med Hyg* 2005;73:576-82.
  8. Couppie P, Clyti E, Nacher M, Aznar C, Sainte-Marie D, Carme B, et al. Acquired immunodeficiency syndrome-related oral and/or cutaneous histoplasmosis: a descriptive and comparative study of 21 cases in French Guiana. *Int J Dermatol* 2002;41:571-6.
  9. Vidyanath S SP, Sudha S, Nair RG. Disseminated histoplasmosis with oral and cutaneous manifestations. *J Oral Maxillofac Pathol* 2013;17:139-42.
  10. Antonello VS, Zaltron VF, Vial M, Oliveira FM, Severo LC. Oropharyngeal histoplasmosis: report of eleven cases and review of the literature. *Rev Soc Bras Med Trop* 2011;44: 26-9.
  11. Iqbal F, Schifter M, Coleman HG. Oral presentation of histoplasmosis in an immunocompetent patient: a diagnostic challenge. *Aust Dent J* 2014;59:386-8.
  12. Klein IP, Martins MA, Martins MD, Carrard VC. Diagnosis of HIV infection on the basis of histoplasmosis-related oral ulceration. *Spec Care Dentist* 2016;36:99-103.
  13. Rocha MM, Severo LC. [Disseminated histoplasmosis in patients with acquired immunodeficiency syndrome (AIDS). Study of 25 cases]. *Rev Inst Med Trop Sao Paulo* 1994;36:167-70.
  14. Golda N, Feldman M. Histoplasmosis clinically imitating cutaneous malignancy. *J Cutan Pathol* 2008;35 Suppl 1:26-8.
  15. Patil K MV, Prathibha Rani RM. Oral histoplasmosis. *J Indian Soc Periodontol* 2009;13:157-9.
  16. Carrasco-Zuber JE, Navarrete-Dechent C, Bonifaz A, Fich F, Vial-Letelier V, Berroeta-Mauriziano D. Cutaneous involvement in the deep mycoses: A review. Part II -Systemic mycoses. *Actas Dermosifiliogr* 2016;107: 816-22.
  17. de Paulo LF, Rosa RR, Durighetto Junior AF. Primary localized histoplasmosis: oral manifestations in immunocompetent patients. *Int J Infect Dis* 2013;17:e139-40.
  18. Wheat LJ, Freifeld AG, Kleiman MB, Baddley JW, McKinsey DS, Loyd JE, et al. Clinical practice guidelines for the management of patients with histoplasmosis: 2007 update by the Infectious Diseases Society of America. *Clin Infect Dis* 2007;45:807-25.
  19. Marques SA. Fungal infections of the mucous membrane. *Dermatol Ther* 2010;23:243-50.