

**Diffuse Palmoplantar Keratoderma  
(Unna-Thost syndrome) with Postcricoid and  
cervical esophageal carcinoma**

Waiphot Chanvimalueng\*

**Chanvimalueng W. Diffuse Palmoplantar Keratoderma (Unna-Thost syndrome) with Postcricoid and cervical esophageal carcinoma. Chula Med J 1998 Sep; 42(9): 695-700**

*A case of postcricoid and cervical esophageal carcinoma associated with diffuse palmoplantar keratoderma (PPK) or Unna-Thost syndrome is described in a middle age women suffering from dysphagia. An association between PPK and postcricoid and cervical esophageal carcinoma has not been previously described, but PPK has been reported in association with a variety of internal malignancies. When PPK is associated with malignancy the prognosis is poor. Recognizing the lesions of PPK and dysphagia may lead to early diagnosis of pharyngo-esophageal carcinoma and improved prognosis.*

**Key words :** *Postcricoid, Esophageal carcinoma, Palmoplantar keratoderma, Unna-Thost syndrome.*

Reprint request : Chanvimalueng W. Department of Otolaryngology , Faculty of Medicine,  
Thammasat University, Pathumthani 12120, Thailand.

Received for publication. July 5, 1998.

**ไวพจน์ จันทรวิเมลีอง. มะเร็งหลังกระดูกไครคอยด์และหลอดอาหารส่วนคอสัมพันธ์กับโรค Diffuse Palmoplantar Keratoderma (Unna-Thost syndrome). จุฬาลงกรณ์เวชสาร 2541 ก.ย; 42(9):695-700**

รายงานผู้ป่วยสตรีวัยกลางคน มาด้วยอาการกลืนลำบากซึ่งได้รับการวินิจฉัยเป็นมะเร็งหลังกระดูกไครคอยด์และหลอดอาหารส่วนคอสัมพันธ์กับโรค Diffuse Palmoplantar Keratoderma (PPK) หรือ Unna-Thost syndrome ยังไม่เคยมีรายงานถึงความสัมพันธ์กันระหว่าง โรค PPK กับมะเร็งหลังกระดูกไครคอยด์และหลอดอาหารส่วนคอมาก่อน แต่เคยมีรายงานว่าโรค PPK มีส่วนสัมพันธ์กับโรคมะเร็งของอวัยวะภายใน ซึ่งเมื่อพบโรค PPK ร่วมกับโรคมะเร็ง การพยากรณ์โรคจะไม่ดี การพบลักษณะของโรค PPK ร่วมกับการกลืนลำบากอาจทำให้การวินิจฉัยโรคมะเร็งของหลอดคอและหลอดอาหาร รวดเร็วขึ้นยังผลให้การพยากรณ์โรคดีขึ้น

Postcricoid and cervical esophageal carcinoma usually presents late, with a downward spreading into the esophageal inlet, and this tumor may be extensive.<sup>(1)</sup> Symptoms initially tend to be mild and easily ignored, and it is only after significant narrowing has occurred that the patient seeks medical attention. The average time between onset of symptoms and diagnosis is roughly six months. When patients do present, dysphagia is the most common symptom.<sup>(2)</sup> Possible causes include hot liquids; hot, spicy and coarse foods; strong alcoholic beverages; cigarette, cigar and pipe smoking; and excessive ethanol intake. Predisposing conditions include achalasia, hiatus hernia, caustic and other strictures, and the Plummer-Vinson syndrome.<sup>(3,4)</sup> It is far more common in men than women, except that carcinoma of the cervical esophagus is more common in women than men.<sup>(3)</sup> The relationship of this tumor to sideropenic dysphagia, Paterson-Brown-Kelly or (Plummer-Vinson Syndrome) has been reported.<sup>(5)</sup>

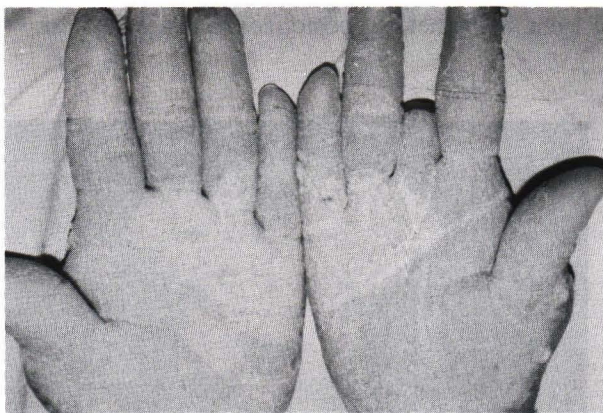
This case report, the author described here in

a case of squamous cell carcinoma of postcricoid and cervical esophagus in association with diffuse palmoplantar keratoderma (PPK) or Unna-Thost syndrome in a 48-year old woman. To the best of our knowledge, This is the first reported case of this entity.

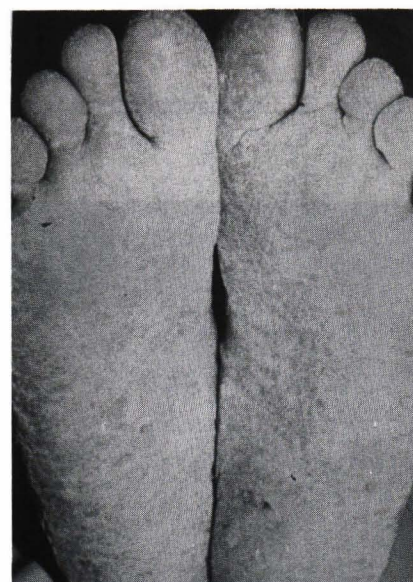
### Case report

A 48-year old Thai woman presented at the out-patient department of Thammasat University Hospital with a six-month history of progressive dysphagia.

She denied cigarette smoking or alcoholic intake but she had been diagnosed with PPK by a dermatologist about 4 years previously. She had only one son who was also diagnosed with PPK at age of 2 months. Physical examination revealed marked diffuse hyperkeratosis of the palms and soles with sharp margin, this lesion appears at the age of 3 months (Figure1). The nasal cavity and nasopharynx were within normal limit. Indirect laryngoscopic examination showed normal epiglottis, vocal cord and pyriform sinus.



A.



B.

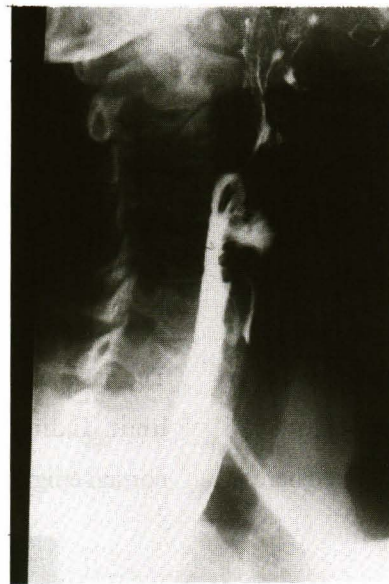**Figure 1.** A. mark diffuse hyperkeratosis of the palms.  
B. the lesion of the soles.

An esophagogram revealed a 1x1 cm. mass involving the postcricoid and anterior aspect of upper esophagus (Figure2).

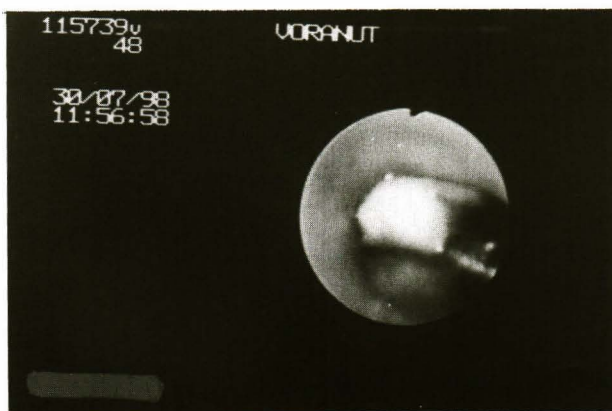A direct laryngoscope was done and revealed single smooth surface mass measuring 2-3 cm. in diameter at postcricoid and cervical esophagus, normal vocal cord function, pyriform sinus within normal limit and punch biopsies was performed (Figure3). The pathologic report was consistent with moderately differentiated, squamous cell carcinoma. A metastatic

work ups were performed. Chest x-ray, liver function test and bone scan findings were normal.

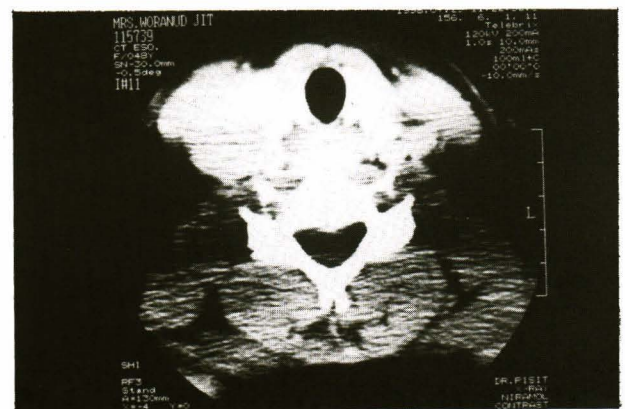
A computerized tomography scan (CT scan) demonstrated a soft tissue mass at the postcricoid invading the cervical esophagus measuring 2.5 x 3 cm. in diameter (Figure 4). The remaining esophagus was unremarkable. No lymph node enlargement was detected. Lung and mediastinum were within normal limits.



**Figure 2.** Esophagogram showed mass measuring 1 cm. in diameter at postcricoid and cervical



**Figure 3.** Direct laryngoscope showed smooth surface mass measuring 2-3 cm. in diameter.



**Figure 4.** CT scan showed soft tissue mass at postcricoid and cervical esophagus.



The patient was given an upper esophagectomy and free jejunum graft interposition with microvascular anastomosis.

## Discussion

PPK is inherited as an autosomal dominant trait and occurs equally in men and women of all races. PPK usually presents in early infancy. Only the hands or feet may be involved. Histologic sections of skin show only marked hyperkeratosis.<sup>(6)</sup>

PPK has been reported to be associated with congenital heart disease,<sup>(7)</sup> micropenis,<sup>(8)</sup> deafness,<sup>(9,10)</sup> internal malignancies such as carcinoma of the lung<sup>(11)</sup> and carcinoma of the esophagus.<sup>(6,12)</sup>

The sites of the esophageal lesion were in the lower third in half the cases and in the middle third in about 15 percent.

Skin lesions are commonly classified according to their origin as follows; skin lesions induced by internal malignancies, skin lesions as a part of a syndrome, nonspecific lesions and complications of internal malignancies, but with an unknown relationship, so-called Bowen's disease and Paget's disease.<sup>(13)</sup>

It is great importance to find out internal malignancies even in cases of mild and non-specific symptoms in the presence of skin lesion.

In this case, the correct diagnosis was postponed for six months because of a lack of awareness of the relationship between skin lesion (PPK) and the internal malignancy.

The author advised that physical examination by indirect laryngoscope alone in cases of PPK or other skin lesions who present with dysphagia is not enough for early diagnosis. Barium swallowing plays an important role in detecting esophageal tumors. Once

the presence of an esophageal tumor has been established and confirmed, cross-sectional imaging, such as CT or MRI, is needed for pretherapy staging.<sup>(14)</sup> In conclusion, recognizing lesions of PPK and dysphagia may lead to early diagnosis of postcricoid and cervical esophageal carcinoma which resulting in an improved prognosis.

## References

1. Haughey BH. Total laryngectomy and laryngopharyngectomy. In : Cummings CW, Schuller DE, eds. Otolaryngology Head and Neck Surgery. 2<sup>nd</sup> ed. St. Louis, Missouri: Mosby Year Book, 1993:2166-77
2. Seiden AM. Esophageal disorder. In : Paparella MM, Shumrick DA, Gluckman JL, Meyerhoff WL, eds. Otolaryngology. 3<sup>rd</sup> ed. Philadelphia; W.B. Saunders, 1991:2439-81
3. Snow JB, JR. Esophagology. In : Ballenger JJ, ed. Diseases of the Nose, Throat, Ear, Head and Neck. 14<sup>th</sup> ed. Pennsylvania; Lea & Febiger, 1991 : 1297-321
4. Jones KR. The esophagus. In : Lee KJ, ed. Essential Otolaryngology Head & Neck Surgery. 6<sup>th</sup> ed. Connecticut; Appleton & Lange, 1995:481-97
5. Harrison DFN. Tumors of the hypopharynx. In: Paparella MM, Shumrick DA, Gluckman JL, Meyerhoff WL, eds. Otolaryngology. 3<sup>rd</sup> ed. Philadelphia; W.B. Saunders, 1991:2199-214
6. Goldsmith LA, Thomas NE. Disorder of cornification. In : Moschella SL, Hurley HJ, eds. Dermatology. 3<sup>rd</sup> ed. Philadelphia; W.B. Saunders, 1992:1383-417
7. Hoeger PH, Yates RW, Harper JI. Palmoplantar keratoderma associated with congenital heart

- disease. *Br J Dermatol* 1998 Mar;138(3):506-9
8. Kurz KH, Steigleder GK. Keratosis palmoplantaris diffuse circumscripta (Thost-Unna) with micropenis. *Z Hautkr* 1988 Feb;63(2):91-3
9. Hatamochi A, Nakagawa S, Ueki H, et al. Diffuse palmoplantar keratoderma with deafness. *Arch Dermatol* 1982 Aug; 118(8): 605-7
10. Fitzperald DA, Verbov JL. Hereditary palmoplantar keratoderma with deafness. *Br J Dermatol* 1996 May; 134(5) : 939-42
11. Nomori H, Horio H, Iga R, et al. Squamous cell carcinoma of the lung associated with palmoplantar hyperkeratosis. *Nippon Shikkan Gakkai Zasshi* 1996 Jan;34(1):76-9
12. Schnyder UW. Inherited keratodermas of palms and soles. In : Fitzpatrick TB, Eisen AZ, Wolff K, Freedberg IM, Austen KF, eds. *Dermatology in General Medicine*. 4<sup>th</sup> ed. New York; Mc Graw-Hill, 1993 : 557-64
13. Ishihara K, Hayasaka K, Ikegawa S. Internal malignancies and skin lesion. *Gan To Kagaku Ryoho* 1986 Jan; 13(6): 2065-73
14. Singer J, Heiken JP. Diagnostic imaging of the esophagus. In : Cummings CW, Schuller DE, eds. *Otolaryngology Head and Neck Surgery*. 2<sup>nd</sup> ed. St. Louis, Missouri; Mosby Year Book, 1993:2258-87