

## MRI of pyogenic spondylitis: cases reports

Darunee Boonyeunwetwat\*

Linchong Phunchana\*

**Boonyeunwetwat D, Phunchana L. MRI of pyogenic spondylitis: cases reports. Chula Med J 1998 Mar;42 (3): 197-206**

*We report the MRI features of four cases of proven pyogenic spondylitis. Several studies have shown that the sensitivity of MRI for detection of osteomyelitis is equal to, or exceeds, 3-phase technitium-99m methylene diphosphonate (99mTc-MDP) and gallium-67 citrate (67 Ga) scintigraphy. MRI has been found to be better than CT scans for imaging spondylitis and vertebral osteomyelitis because of its ability to depict the anatomy, including the disc space, the spinal canal and its contents, and the paraspinal regions.(1) Early diagnosis and prompt treatment are essential to prevent permanent neurologic deficit and/or spinal deformity.*

**Key words :** *MRI of spondylitis, Imaging of spondylitis.*

Reprint request : Boonyeunwetwat D, Department of Radiology, Faculty of Medicine, Chulalongkorn University, Bangkok 10330, Thailand.

Received for publication. January 15,1998.

---

\* Department of Radiology, Faculty of Medicine, Chulalongkorn University.

ดรุณี บุญยืนเวทวัฒน์, ลินจง พันธุ์ชนะ. ลักษณะภาพ MRI ของโรคกระดูกสันหลังที่เกิดจากการติดเชื้อแบคทีเรีย. จุฬาลงกรณ์เวชสาร 2541 มี.ค;42 (3): 197-206

ผู้ป่วยจำนวน 4 ราย ที่ได้รับการวินิจฉัยเป็นโรคกระดูกสันหลังที่เกิดจากการติดเชื้อแบคทีเรีย ซึ่งได้รับการตรวจด้วย MRI พบว่ามีความผิดปกติของลักษณะภาพ MRI ที่เฉพาะเจาะจงตรงตำแหน่งที่มีการถูกทำลาย มักจะพบมีการทำลายที่บริเวณของกระดูกสันหลังและหมอนกระดูก ภาพของ MRI สามารถให้การวินิจฉัยโรคได้แม่นยำ ช่วยในการวินิจฉัยแยกโรคที่มีการทำลายของกระดูกจากสาเหตุอื่นได้แก่ วัณโรค การเสื่อมของกระดูกและหมอนกระดูก เนื้องอก และการกระจายของมะเร็ง นอกจากนี้ยังสามารถตรวจภาวะการแทรกซ้อนที่เกิดจากการกระจายของพยาธิสภาพไปบริเวณข้างเคียง เช่น ช่องไขสันหลังและเนื้อเยื่อบริเวณรอบ ๆ ว่ามีการกดทับของไขสันหลังหรือเส้นประสาทหรือการเกิดฝีร่วมด้วยซึ่งภาวะเหล่านี้ควรจะได้มีการวินิจฉัยได้อย่างรวดเร็ว ทำให้ได้รับการรักษาอย่างเร่งด่วนโดยการผ่าตัด เพื่อที่จะลดอัตราการตายและความพิการที่เกิดจากการกดทับของระบบประสาทและไขสันหลัง

## Cases reports

### Case 1

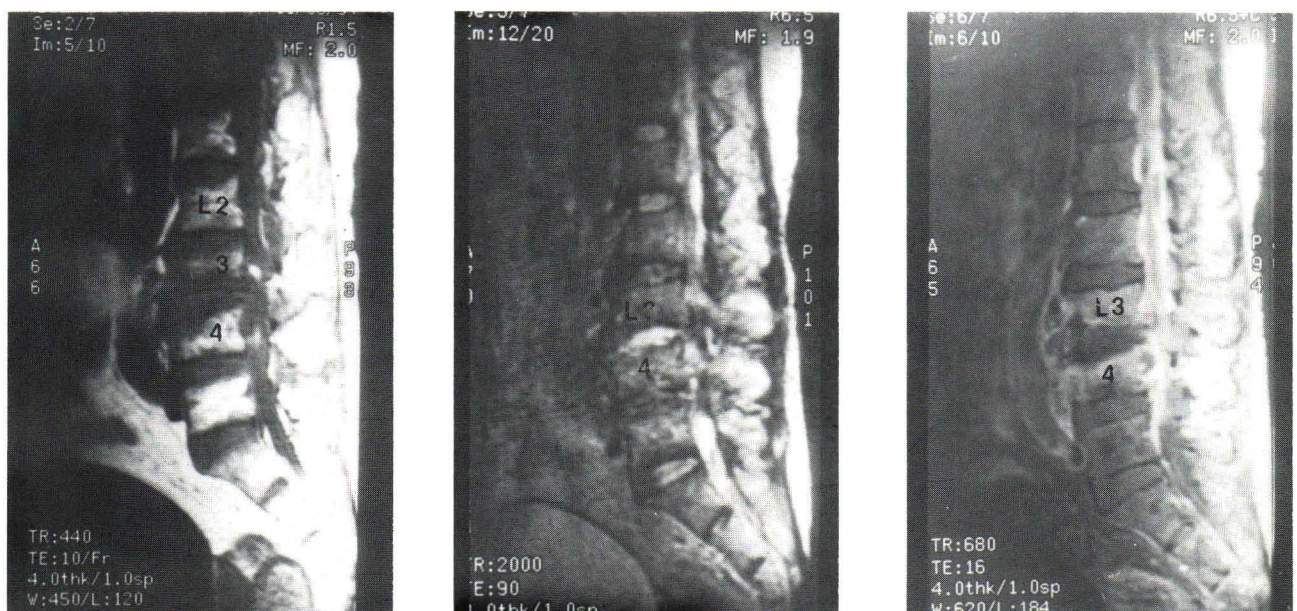
A 54-year-old female was admitted because of complaint of back pain radiating to both legs. Six weeks earlier, while lifting a heavy box, she had a sudden onset of severe back pain radiating into the left leg. Two weeks later, the back pain was also radiating into the right leg. Weakness of both legs then appeared and she found herself unable to urinate.

The patient was afebrile, and there were no signs of localized infection. Limited motion of the lumbar spine due to pain was observed. There was minimal (4/5) weakness of the left extensor hallucis longus muscle.

The WBC count was 20,720 cells/cu.mm. with 87% neutrophils and 7% lymphocytes.

MRI of the lumbosacral spine revealed

a decreased height of the L3 and L4 vertebral bodies with irregularity of the lower end plate of the L3 and upper end plate of the L4. These end plates showed low signal intensity on T1 weighted images and high signal intensity on PD and T2 weighted images. The L3/4 disc was enlarged with evidence of anterior and posterolateral herniation causing spinal canal and neural foramina stenosis. Increased signal intensity of the L3/4 disc on both PD and T2 weighted images was detected (Fig. 1A, B). After intravenous injection of Gadolinium-DTPA with the fat suppression technique there was abnormal enhancement at the L3 and L4 vertebral bodies, including posterior elements, and prevertebral and epidural soft tissues at the level of L3 to L4. Evidence of leptomeningeal enhancement from the level of T12 to L5 was also detected (Fig. 1C).



**Figure 1.** (A, B, C) Sagittal view of L-S spines showed low signal intensity of lower end plate of L3, upper end plate of L4 and L3-4 disc on T1WI (A), high signal intensity on T2WI (B) and enhancement of L3 and L4 bodies after contrast injection (C)

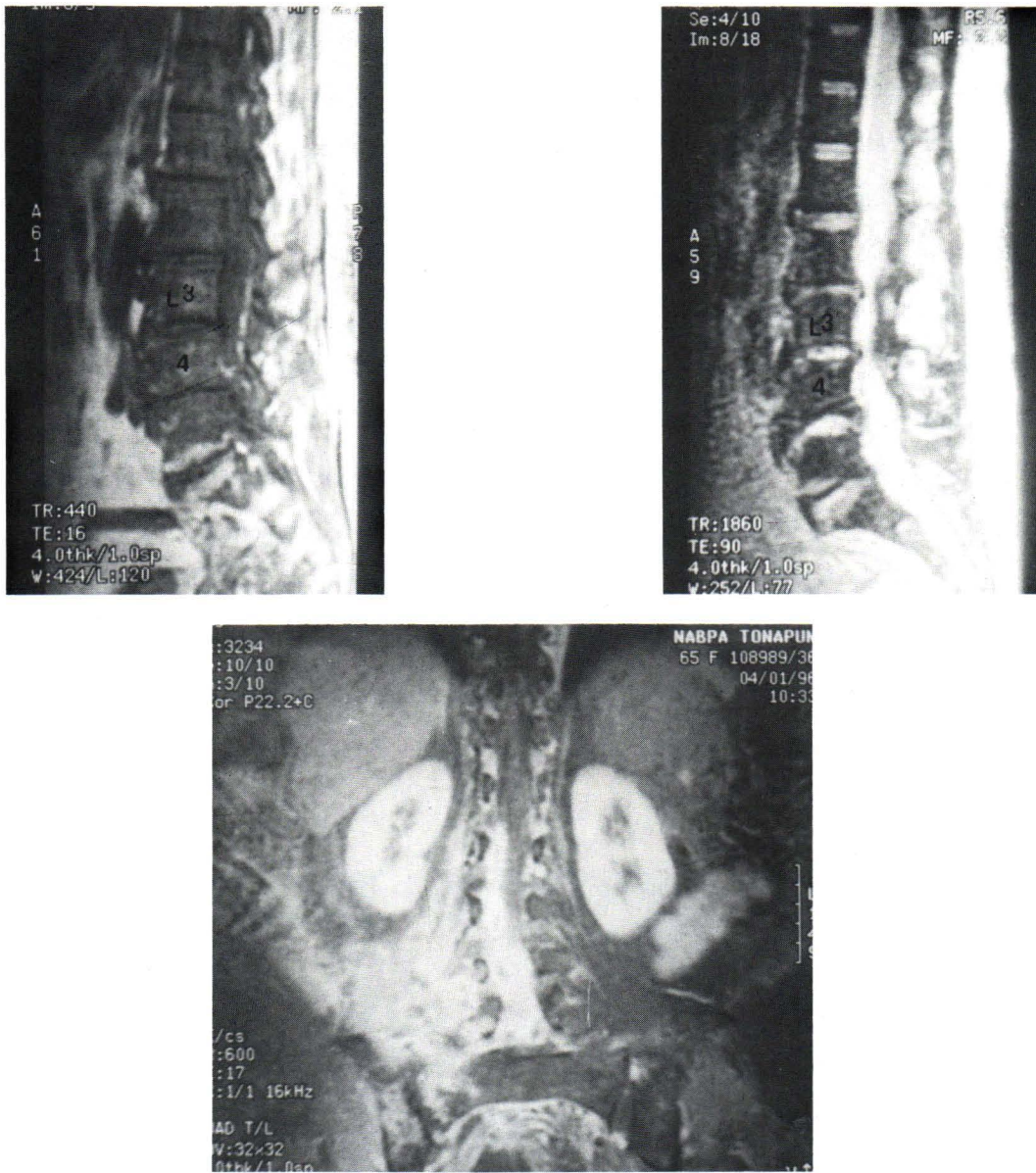
These MRI findings were suggestive of L3 and L4 spondylitis and epidural abscess with severe spinal canal and neural foramina stenosis. Partial L1, L2 and total L3 laminectomy with drainage of the epidural abscess were performed. Culture taken from the abscess grew *Streptococcus viridans*. Intravenous cloxacillin (4 gm. daily) was given for 6 weeks.

### Case 2

The second patient was a 65-year-old woman. Two weeks prior to admission she had right thigh pain but without history of trauma. On physical examination she had high fever and tenderness at the lower abdomen and right thigh with flexion and abduction of the right hip. The WBC count was 16,000 cells/cu.mm. with 90% neutrophils. MRI of the lumbosacral spine revealed a decrease in height of the L3/4 disc having low signal intensity on T1 weighted images and high signal intensity on PD and T2 weighted images (Fig .2 A, B). There was abnormally low signal intensity at the central region of the L3/4 disc on all pulse sequences which might represent abnormal air or calcification. Destruction of the lower end plate of L3 and the upper end plate of L4 were

detected, with low signal intensity on all pulse sequences. Bulging of the right psoas muscle was seen with intermediate signal intensity on T1 weighted images and high signal intensity on PD and T2 weighted images. After intravenous injection of Gd-DTPA, with the fat suppression technique, there was abnormal enhancement of the L3/4 disc including leptomeninges from the level of L2 to S1, the anterior and posterior epidural spaces, the right psoas and iliacus muscles as well as the ipsilateral back muscles (Fig. 2 C). All findings were suggestive of L3/4 discitis and spondylitis extending into the epidural space, and also right iliopsoas abscess involving the back muscles. An L2-L4 laminectomy was performed and the epidural abscess from the level of L2 to L4 was removed. Culture taken from the epidural abscess was negative. The pathology of L2-L4 epidural tissue revealed chronic and acute inflammation. The pus culture from the right psoas abscess and hemoculture grew *Staphylococcus aureus*. Intravenous cloxacillin was continued for 4 weeks and then changed to the oral form for an additional 2 weeks. At the time of discharge, she had no fever but still had paraparesis and back pain.





**Figure 2.** (A, B, C) Sagittal view of L-S spines showed narrowed L3-4 disc and adjacent end plate destruction having low signal intensity of T1WI (A), and high signal intensity on T2WI (B). Post Gd-DTPA coronal view with fat suppression showed enhancement of leptomeninges, epidural space of L2-S1 levels, and right iliopsoas muscle (C)

### Case 3

The third patient was a 59-year-old man who drank alcohol beverages for 40 years. Two weeks earlier he felt neck pain, especially whenever he extended his neck. One week later he developed a high grade fever and progressive

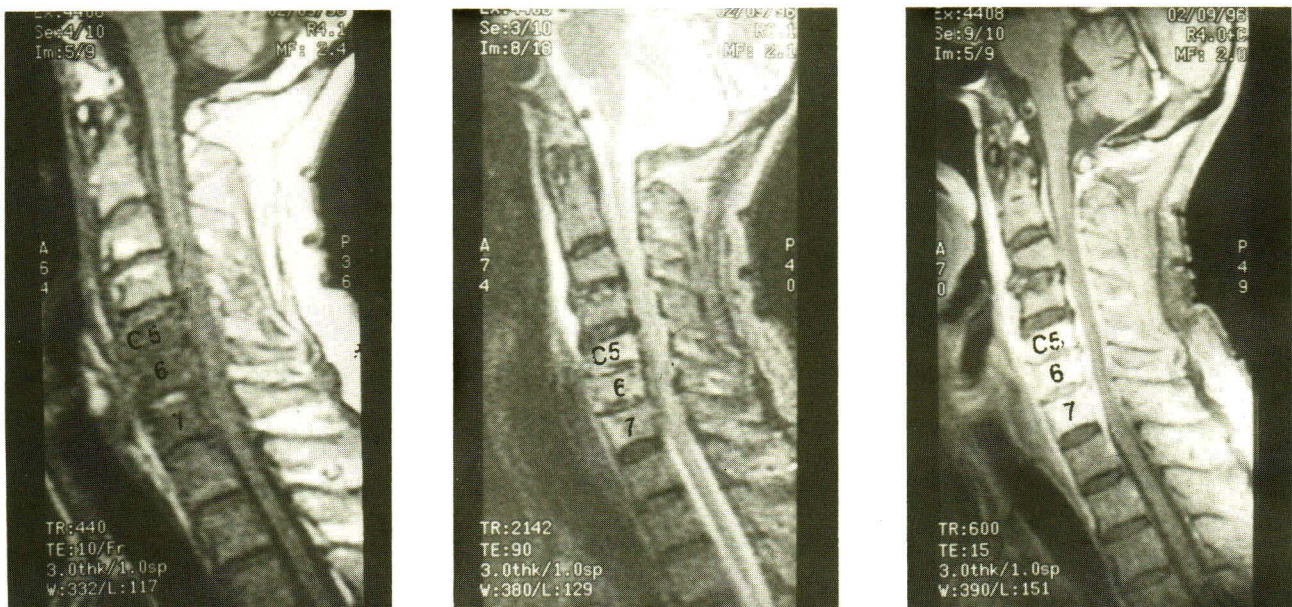
neck pain. Three days before admission he developed drowsiness and weakness of all extremities.

Physical examination revealed generalized spider nevi at the chest and abdominal walls, with palmar erythema. He was febrile and drowsy.



Tenderness and stiffness of the neck in all directions were detected. There was minimal (4/5) weakness of all extremities. The WBC count was 18,100 cells/cu.mm. with 68% neutrophils. Liver function tests showed evidence of chronic liver disease. Hemoculture grew beta streptococcus group B, sensitive to penicillin. MRI of the cervical spine showed low signal intensity of the C5-C7 bodies involving C5/6 and C6/7 discs on T1 weighted images which had high signal intensity on PD and T2 weighted images (Fig. 3 A, B). Widening of paravertebral soft tissue and anterior epidural space at the C2-T1 level were observed, with low signal intensity on T1 weighted images and high signal intensity on PD

and T2 weighted images. After intravenous injection of Gd-DTPA, with the fat suppression technique, there was enhancement of all lesions as described above and also leptomeninges from the level of the C1 to T1 causing spinal canal stenosis and spinal cord compression (Fig. 3 C). The findings were suggestive of spondylitis of C5-C7 with extension into the paravertebral and epidural spaces from C1-T1 with leptomeningeal involvement. Intravenous cloxacillin (12 gm. daily) was given for two weeks, followed by the oral route for 2 additional weeks. At discharge he still had minimal (4/5) weakness of all extremities but without evidence of neck pain or fever.



**Figure 3.** (A, B, C) Sagittal view of C-spine showed low signal intensity of bodies and discs of C5-7 levels on T1WI (A) and getting high signal intensity on T2WI (B). After contrast injection showed enhancement of C5-7 bodies and discs including leptomeninges from C2 to T1 levels (C)



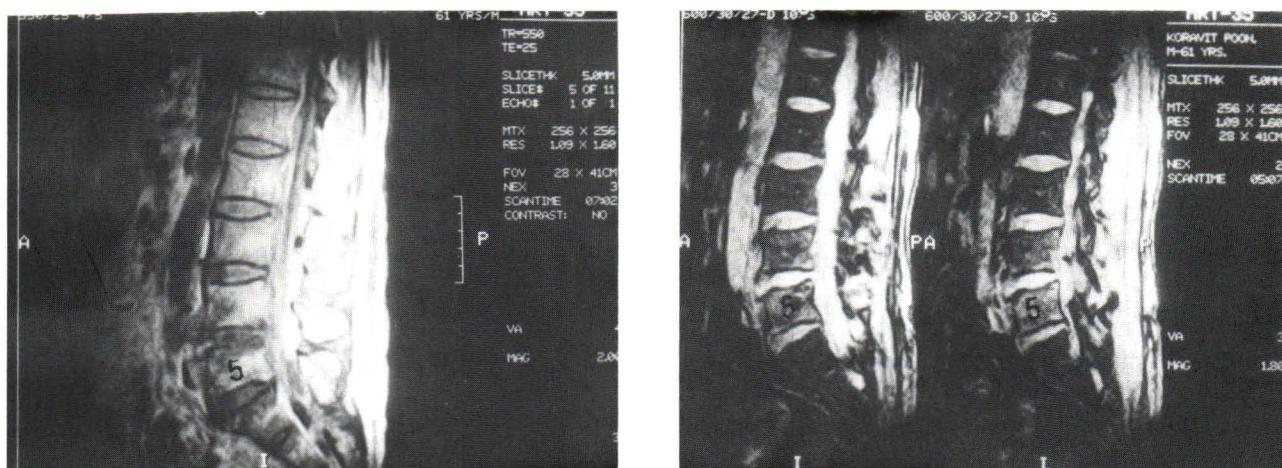
#### Case 4

The fourth case was a 61-year-old man presented with back pain radiating to both legs for the prior two weeks. He developed fever two days before admission. Physical examination revealed tenderness at the lower lumbar area. The deep tendon reflexes of both legs were decreased.

MRI of the lumbosacral spine revealed a narrowing of the L4/5 disc with evidence of irregularity of adjacent end plates of L4, 5 bodies which had low signal intensity on T1 weighted images and hypersignal intensity on T2 weighted images (Fig. 4 A, B). After intravenous injection

of Gd-DTPA enhancement of all lesions as described as well as L4 and L5 vertebral bodies was noted. Evidence<sup>1</sup> of leptomeningeal and epidural soft tissue enhancement from the level of S1 to T12 were observed. These MRI findings were suggestive of L3 and L4 spondylitis with epidural abscess.

The patient was operated on and found to have an epidural abscess at the L4-5 level with severe fibrosis of dura. Pus culture and hemoculture grew Salmonellosis group D. The patient was treated with choramphenical and recovered quite well.



**Figure 4.** (A, B) Sagittal view of L-S spines showed narrowed L4-5 disc with destruction of end plates of L4, 5 bodies, having low signal intensity on T1WI (A) and high signal intensity on T2WI (B)

#### Discussion

Infection of the spine is a major category of spinal disease that is difficult to differentiate clinically from degenerative disease, noninfective inflammatory lesions, and spinal neoplasms. The infection can effect the vertebrae, intervertebral

discs, paraspinal soft tissues, the epidural space, themeninges, and/or the spinal cord.<sup>(2)</sup> It can be caused by bacterial, fungal or parasitic infections. Infective spondylitis most frequently occurs as a result of hematogenous dissemination of bacteria. Less common causes include contiguous spread

of paravertebral infection and iatrogenic causes, particularly spinal surgery.<sup>(3)</sup> Back pain is a common early symptom, and it is frequently associated with localized tenderness and stiffness, with or without neurologic abnormality. The patient may or may not be febrile.<sup>(2-4)</sup>

Pyogenic spondylitis frequently presents in a relatively indolent manner. Symptoms tend to be present for days to months.<sup>(3,4)</sup> The laboratory findings often show leukocytosis. *Staphylococcus aureus* is the most common organism identified, and *Escherichia coli*, *Salmonella*, *Pseudomonas aeruginosa*, and *Klebsiella pneumoniae* have also been implicated.<sup>(2-4)</sup> The causative organisms of our 4 cases were *Streptococcus* in 2 cases, *Staphylococcus* in 1 case, and *Salmonella* in 1 case. Two major criteria are essential for establishing the diagnosis of pyogenic spondylitis: 1) the presence of characteristic imaging features of spinal infection and 2) the isolation of the offending organism from blood or the affected site.

MRI has been shown to be at least as sensitive as bone scintigraphy for detecting infections of the vertebrae and is more, valuable than CT for visualizing the extent of the disease. High contrast resolution, direct multiplanar imaging, usefulness in detecting marrow infiltration as well as intradural disease are definite advantages.<sup>(2-9)</sup> The suitability of MRI in evaluating spinal infection has been attributed to its sensitivity in the detection of increased amounts of water, as is presented in acute

inflammation cases. This increased water is demonstrated on MRI images by areas of low signal intensity on T1WI and high signal intensity on T2WI in the vertebrae, discs, epidural space, spinal cord, and/or paraspinal spaces due to the prolongation of T1 and T2 relaxation values. The ability of MRI imaging to enable discrimination of active viable inflammatory tissue is aided by the administration of gadolinium, which enhances images of discs and other tissues that are actively inflamed.<sup>(8-9)</sup> The paraspinal soft tissues are best assessed on multiscan, multiplanar T1WI after gadolinium enhancement with the fat suppression technique.<sup>(9)</sup>

Characteristic findings of spinal pyogenic infections on T1WI include a narrowed disc space, a low signal intensity in the marrow of adjacent vertebrae, erosion of the cortical bone, and paravertebral masses. On T2WI, the lesions generally exhibit a high signal intensity.<sup>(1)</sup> The most reliable findings are low signal intensity of the vertebral body, disc and end plate on T1WI and high signal intensity of discs on T2WI. The signal changes of the vertebral body on T2WI are less reliable, and can be low, intermediate, or high. Gadolinium enhancement of the vertebral body, disc, epidural and paraspinal spaces is also found to be a reliable finding.<sup>(5)</sup> Although the same features were found in our study, the height of some discs could be normal or even increased when compared to the uninvolved discs above or below (case 1). This is probably due to the time



of examination in relation to the inflammatory process. Epidural extension and associated meningeal inflammation are infrequent,<sup>(2)</sup> but in our study they were found in all cases.

Differentiation of pyogenic spondylitis from tuberculous spondylitis can sometimes be difficult. Clinical data in such cases are invaluable in suggesting the likely pathology, with a more insidious onset of signs and symptoms favoring tuberculous infection. The MRI features of pyogenic and tuberculous spondylitis show similar destruction of vertebral bodies. Tuberculosis can selectively affect part or all of a vertebral body (pedicle, lamina, posterior elements) without involving neighboring discs. The cause of intervertebral disc space preservation is due to the lack of proteolytic enzymes in mycobacteria. Skip lesions, large abscesses, epidural extensions, and subligamentous spread are seen more frequently in this disease than in any other spinal infections.<sup>(1-2)</sup> The sizes of the paraspinal masses have been noted to be generally larger in tuberculosis than in pyogenic infections.<sup>(6)</sup> Enhanced MRI studies are particularly useful for characterizing tuberculous spondylitis. Rim enhancement around intraosseous and paraspinal soft tissue abscesses had not been demonstrated in other spinal infections.<sup>(2)</sup> In our study, we found that the pyogenic spondylitis might have some findings similar to tuberculous spondylitis such as involving posterior elements (case 1), large paraspinal abscesses (case 2), and large epidural

abscesses with leptomeningeal involvement (all cases). Thus it is not possible to distinguish pyogenic from tuberculous spondylitis although the pattern of enhancement in tuberculous spondylitis is different from pyogenic infections.

Metastatic lesions can show similar MRI signal changes but can often be distinguished from spondylitis by the lack of associated disc space involvement. Severe degenerative changes can mimic spondylitis, in aspect of intervertebral disc involvement and similar vertebral signal changes. Degenerative changes can be differentiated by the presence of hypertrophic spurring and a lack of contrast enhancement and associated paraspinal extension.<sup>(3)</sup>

## References

1. Hovi I, Lamminen A, Salonen O, Raininko R. MR imaging of the lower spine. Differentiation between infectious and malignant disease. *Acta Radiologica* 1994 Nov; 35(6) : 532-40
2. Sharif HS. Role of MR imaging in the management of spinal infections. *AJR Am J Roentgenol* 1992 Jun; 158(6) : 1333-1345
3. Bates DJ. Inflammatory diseases of the spine. *Neuroimaging Clin North Am* 1991; 1(1) : 231-50
4. Smith AS, Blaser SI. Infectious and inflammatory process of the spine. *Radiol Clin North Am* 1991 Jul; 29(4):809-27

5. Dagirmanjian A, Schils J, McHenry M, Modic MT. MR imaging of vertebral osteomyelitis revisited. *AJR Am J Roentgenol* 1996 Dec; 168 (6) : 1539-43
6. Smith AS, Weinstein MA, Mizushima A, Coughlin B, Hayden SP, Lakin MM, Lanzieri CF. MR imaging characteristics of tuberculous spondylitis VS vertebral osteomyelitis. *AJR Am J Roentgenol* 1989 Aug; 153 (2) : 399-405
7. Bruns J, Maas R. Advantages of diagnosing bacterial spondylitis with magnetic resonance imaging. *Arch Orthop Trauma Surg* 1989; 108 (1) : 30-35
8. Post MJ, Quencer RM, Katz BH, Eismont FJ, Green BA. Spinal infection: evaluation with MR imaging and intraoperative US. *Radiology* 1988 Dec; 169 (3) : 765-771
9. Sharif HS, Morgan JL, al Shahed MS, al Thagafi MY. Role of CT and MR imaging in the management of tuberculous spondylitis. *Radiol Clin North Am* 1995 Jul; 33 (4) : 787-804