

Cardiac herniation following intrapericardial pneumonectomy in an advanced lung cancer patient with intractable lung abscess

Naplika Kongpolprom*

Kongpolprom N. Cardiac herniation following intrapericardial pneumonectomy in an advanced lung cancer patient with intractable lung abscess. Chula Med J 2014 Nov – Dec; 58(6): 629 - 36

This is a case report of cardiac herniation following right lower lobe lobectomy in a non-small-cell lung cancer patient who previously underwent right upper lobe and right middle lobe lobectomies. The patient presented with obstructive shock with refractory hypoxemia at the 8th hour after the lobectomy with radical removal of the tumor and complicated lung abscess via intrapericardial approach. Chest radiography showed cardiac displacement to the right hemithorax. Cardiac herniation was diagnosed. Consequently, emergency rethoracotomy was performed to explore the cause of this complication and reduce the heart to the normal position. A large pericardial defect was found and subsequently closed by pericardial patch.

Keywords: *Cardiac herniation, intrapericardial pneumonectomy, lung abscess, non-small-cell lung cancer, right lower lobe lobectomy.*

Reprint request: Kongpolprom N. Department of Medicine, Faculty of Medicine,
Chulalongkorn University, Bangkok 10330, Thailand.

Received for publication. January 23, 2014.

ฉบับผลิตกา กองพลพรหม. การเคลื่อนตำแหน่งของหัวใจจากการผ่าตัดปอดโดยวิธี intrapericardial approach ในผู้ป่วยมะเร็งปอดระยะลุกลามที่มีโพรงหนองจากการติดเชื้อในปอด. จุฬาลงกรณ์เวชสาร 2557 พ.ย. – ธ.ค.; 58(6): 629 – 36

บทความนี้เป็นรายงานผู้ป่วยมะเร็งปอดชนิด nonsmall-cell ที่มีการเคลื่อนตำแหน่งของหัวใจ (Cardiac herniation) ไปที่ช่องอกด้านขวาหลังการผ่าตัดปอดขวาเพื่อเอาก้อนเนื้อมะเร็งปอดที่ลุกลามในช่องอกและโพรงหนองจากการติดเชื้อแบคทีเรียแทรกซ้อนออก ผู้ป่วยมีภาวะความดันโลหิตและออกซิเจนในเลือดต่ำเกิดขึ้นหลังการผ่าตัด 8 ชั่วโมงจากการเคลื่อนตำแหน่งของหัวใจ โดยวินิจฉัยจากภาพรังสีปอดที่แสดงภาพหัวใจเคลื่อนตำแหน่งเข้าไปอยู่ที่ช่องอกขวา ซึ่งเป็นลักษณะเฉพาะของภาวะดังกล่าว ผู้ป่วยได้รับการผ่าตัดฉุกเฉิน เพื่อสืบค้นหาสาเหตุของการเคลื่อนตำแหน่งของหัวใจ และจัดตำแหน่งหัวใจให้อยู่ในช่องเยื่อหุ้มหัวใจตามปกติผลการผ่าตัดพบรูรั่วขนาดใหญ่ที่เยื่อหุ้มหัวใจ ซึ่งเป็นผลจากวิธีการผ่าตัดปอดชนิด intrapericardial approach โดยรูรั่วที่เยื่อหุ้มหัวใจดังกล่าวได้รับการผ่าตัดปิดซ่อมด้วยแผ่นเนื้อเยื่อหุ้มหัวใจ (pericardial patch)

คำสำคัญ : การเคลื่อนตำแหน่งของหัวใจ, การผ่าตัดปอดโดยวิธี intrapericardial approach, โพรงหนองในปอด, มะเร็งปอดชนิด nonsmall-cell, การผ่าตัดปอดกลีบขวาล่าง.

Cardiac herniation is one of the most serious and life threatening complications of intrapericardial pneumonectomy. It causes cardiopulmonary decompensation associated with high mortality rates ranging from 50 to 100%.⁽¹⁻³⁾ This complication should always be considered and promptly diagnosed in post-pneumonectomy patients who develop a superior vena cava syndrome or cardiogenic shock immediately after the operation. Several measures should be applied as prophylaxis of this potentially fatal complication.

Case report

A 61-year old male patient with non-small-cell lung cancer was admitted due to an intractable lung abscess, secondary to obstructive pneumonia at the right lower lung.

Three years before admission, the patient was diagnosed with stage IIA adenocarcinoma of the right upper lobe. As a result, right upper lobe lobectomy followed by right middle lobe lobectomy owing to postoperative right middle lobe twist, were performed, combined with adjuvant chemotherapy plus radiation. Unfortunately, the cancer only partially responded and gradually progressed despite a change of the treatment regimen.

Four months before admission, the patient developed low-grade fever and productive cough with hemoptysis. Chest radiography showed a new cavity in the right upper lung field (Figure 1B). Then, a lung abscess was diagnosed. The patient was hospitalized to receive a prolonged course of antibiotics, but the abscess was continuously expanding (Figure 1C). Chest CT and bronchoscopy were performed to evaluate the cause of the intractable abscess which revealed an obstructing tumor in the right main bronchus. Hence, external beam radiation was performed. However, it failed to reduce the tumor

size. Therefore, surgical removal of the abscess was scheduled. Consequently, intrapericardial pneumonectomy of the remaining right lung was successfully performed. In addition, a chest drain was left in the right hemithorax without negative pressure suction. The patient was transferred to the intensive care unit for postoperative care. Eight hours later, the patient developed sudden oxygen desaturation and hemodynamic instability (Table 1).

As seen in Table 1, the patient had transient hemodynamic improvement in the early postoperative period. Until the 8th postoperative hour, the patient developed refractory hypoxemia and shock with increased CVP despite no fluid resuscitation at that time.

Obstructive or cardiogenic shock was considered. Thus, a vasopressor agent, including intravenous fluid, was immediately administered, and the ventilator setting was adjusted, while the exact cause of shock and oxygen desaturation was evaluated. On physical examination, the point of maximal cardiac impulse appeared at the right 5th intercostal space, lateral to the midclavicular line and chest radiography showed heart displacement into the right hemithorax. (Figures 1D and 1E) . The patient was then diagnosed with cardiac herniation.

As a consequence, an emergency rethoracotomy was performed. The heart prolapsing through a pericardial defect into the right hemithorax was found and this 5-centimeter pericardial defect was considered the cause of the herniation. Subsequently, the heart was mobilized to the original position, and the defect was closed by a patch. After that, hemodynamics and oxygen saturation resumed to normal. The patient was extubated on the third postoperative day and later discharged from the intensive care unit.

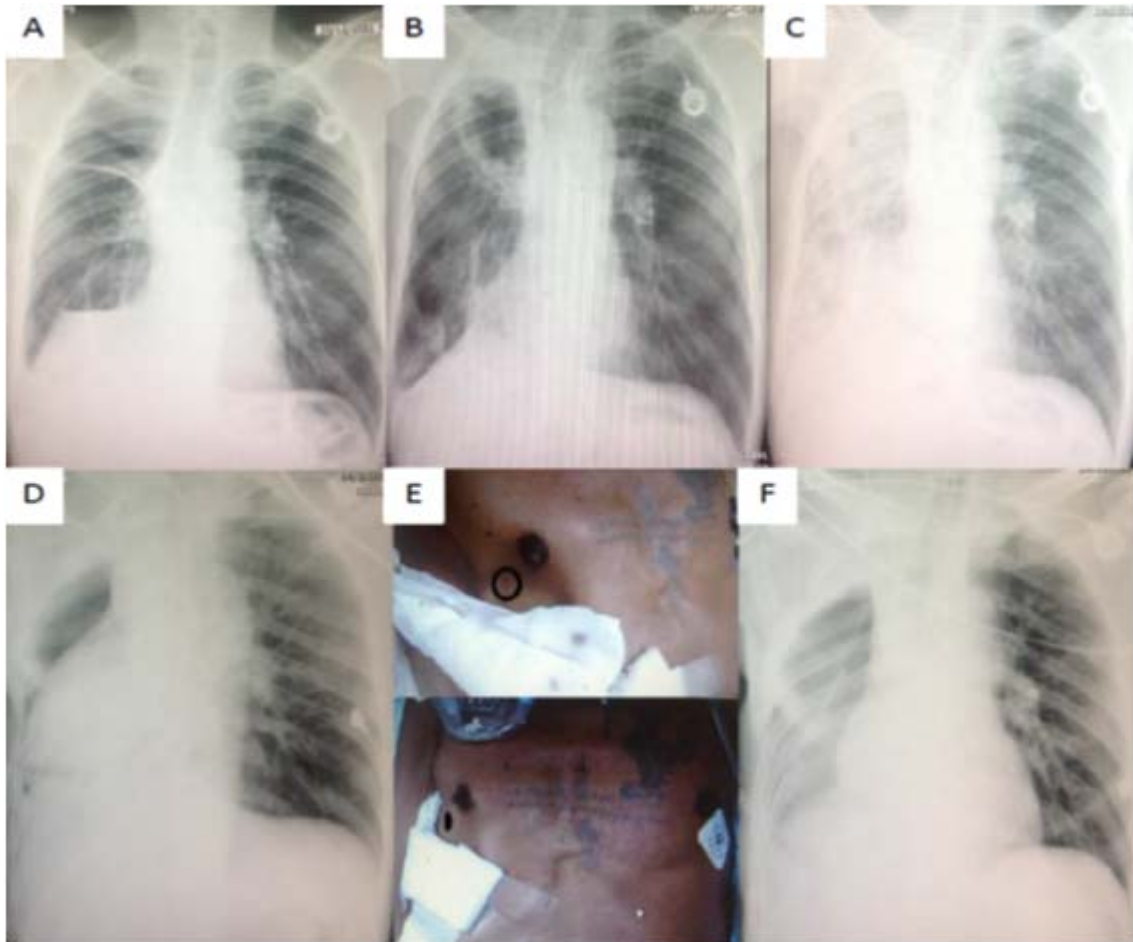


Figure 1. (1A) Chest radiography after right upper lobe and right middle lobe lobectomies 2 years before admission shows decreased volume of the right lung and right diaphragmatic elevation, (1B) Chest radiography 4 months before admission shows a cavity at right upper lung field, (1C) Chest radiography during the antibiotic treatment shows right lung infiltration with a large abscess, (1D) Immediate postoperative chest radiography shows the heart displaced into the right hemithorax, (1E) The point of maximum cardiac impulse (PMI) shifts to the right hemithorax (black circle demonstrates PMI.), (1F) Post-rethoracotomy chest radiography shows the heart has returned to the normal position.

Table 1. Postoperative records.

Time	Ventilator setting		Hemodynamic parameters		Arterial Blood gas				Treatment
	Mode	FiO2	CVP mmHg	BP	PaO2 mmHg	PaCO2 mmHg	pH	SpO2	
Immediate	PCV	0.8	6	90/60	307	35	7.45	100%	
Postoperation									
4 hours later	CPAP	0.4	10	85/60 → 100/70				100%	0.9% NSS IV 200 ml loading
8 hours later	CPAP	0.4	15	80/50	40	25	7.50	80%	Norepinephine
10 hours later	PCV	0.65	16	110/80	48	24	7.49	83%	Norepinephine
10.5hours later	PCV	1	16	110/80	73	20	7.30	95%	Norepinephine

Discussion

Cardiac herniation following intrapericardial pneumonectomy was first reported by Bettmann and Tannenbaum⁽⁴⁾ in 1948 although there had been a few earlier reports⁽⁵⁻⁷⁾ of cardiac herniation associated with a congenital pericardial defect and severe blunt chest trauma with pericardial previously torn. It is a rare catastrophic complication with high mortality rates.⁽¹⁻³⁾

This complication is related to: (1) intrapericardial pneumonectomy or lobar resection without reconstruction of a pericardial defect; (2) negative pressure suction via intercostal drainage connecting to empty pleural cavity; (3) positive pressure ventilation or hyperinflation of the remaining lung; (4) severe coughing; and, (5) repositioning of the patient with the vacant pneumonectomy space downwards.⁽⁸⁻¹⁷⁾

Cardiac herniation usually occurs before the end of an operation during repositioning the patient

to supine or within 24 hours after operation.⁽¹⁸⁾ Due to rapid adhesion between the heart and the pericardium, late herniation-beyond 24 hours is unlikely.⁽³⁾ Clinical manifestations depend upon the position of cardiac displacement. In case of right sided shift⁽¹⁹⁾, the torsion or kinking of the superior vena cava or inferior vena cava especially at the atriocaval junctions may subsequently present, leading to superior vena cava syndrome –swollen face and neck, elevated jugular venous pressure and increased central venous pressure. This reduces the cardiac preload. Moreover, dextroversion may cause ventricular outflow tract obstruction, resulting in decreased cardiac output and obstructive shock. Besides, the obstruction of the great vessels might decrease pulmonary blood flow or shift blood to the unventilated alveoli, resulting in severe hypoxemia from ventilation-perfusion mismatch and shunt. In the case of left- side shift^(17, 20), the heart might be compressed by the constricting pericardial

defect leading to cardiac strangulation, which causes arrhythmia, myocardial ischemia and shock. Surprisingly, the symptoms sometimes disappear spontaneously after the onset of cardiac herniation, but they usually relapse into profound shock within a short period of time. Furthermore, some patients have sudden cardiac arrest without any warning symptoms or signs except an abnormal chest image.

In the present case, because of severe adhesion from the necrotic tumor and infected tissues on the hilum and mediastinal pleura, an intrapericardial approach needed to be performed for radical resection of the tumor and abscess removal, which caused a large pericardial defect. As a result, the heart dislocated to the right empty hemithorax, leading to hemodynamic instability and refractory hypoxemia.

To explore the onset of cardiac herniation, intraoperative and initial postoperative records were reviewed. On physical examination, the point of maximal cardiac impulse at the right 5th intercostal space, lateral to midclavicular line, was first documented at the arrival time to the ICU. Additionally, the immediate postoperative chest radiography showed cardiac displacement to the right. Thus, the onset of the cardiac herniation might have been immediate on the return to ICU or before that time, including at the end of operation or in the recovery room. Unfortunately, although the patient had the pathognomonic signs of cardiac malposition on physical examination and the chest-image, this life-threatening complication was not diagnosed at the beginning, since the patient did not show any symptoms. Moreover, transient hypotension with dramatic response to 200 ml bolus of normal saline

was observed at the 4th postoperative hour. Owing to the relatively low CVP, hypovolemia and hemorrhage were first considered as the cause of shock, but bleeding was then not detected, however. At the time, the patient still had positive fluid balance of approximately 1,500 ml, including intraoperative blood loss of 5,000 ml, with stable hematocrit; there was no need of further fluid resuscitation. Furthermore, the patient's condition remained stable for a few hours until the patient developed shock and refractory hypoxemia again at the 8th postoperative hour. It could be explained that the herniation might have caused right ventricular outflow tract obstruction or superior vena cava (SVC) torsion or kinking which subsequently reduced the venous return and suddenly increased the CVP. In addition, this obstruction might have reduced pulmonary blood flow and shifted blood to unventilated alveoli, resulting in refractory hypoxemia. Left ventricular outflow tract obstruction might have been a less likely mechanism of decreased cardiac filling and cardiac output because there were no signs of pulmonary congestion on physical examination and the chest image.

Because of the possibility of a fatal outcome, cardiac herniation should be highly considered in post pneumonectomy conditions. Its presentations vary from no signs and symptoms to cardiopulmonary decompensation and sudden cardiac arrest, associated with the degree of the great vessels' torsion and the cardiac compression. Furthermore, prophylactic strategies against the catastrophic complication should be applied in all patients with pericardial defects created from the operations. The reconstruction of a pericardial defect from

intrapericardial pneumonectomy is strongly recommended to prevent cardiac dislocation, regardless of the defect size.⁽²¹⁾ Even though a medium or large pericardial defect mostly causes cardiac prolapse, there are a few reports⁽²²⁾ of the herniation from a small defect, particularly close to the atriocaval junctions. Importantly, direct suturing to close a pericardial defect should be limited to be performed only in cases with a very small defect. Due to the loose suturing to reduce tissue tension for prevention of postoperative cardiac tamponade, the procedures leading to a sudden increasing in intrathoracic pressure, including positive pressure ventilation, coughing from airway suctioning and so on, can trigger the heart protusion. Therefore, a medium or large defect should be repaired or closed by an autologous tissue patch, namely, fascia lata and pleura flap, or a synthetic patch, namely, Teflon graft, Dacron patch and expanded polytetrafluoroethylene (EPTFE) patch. However, if cardiac herniation presents, the reduction of the heart to its normal position and pericardial reconstruction should be performed immediately. In this case, the swollen heart resulting from pericardial retraction was found at the 8th postoperative hour. Nevertheless, the kinking of the outflow tract of the heart or the great vessels was not mentioned in the operative finding. Therefore, due to the swollen heart, after the heart reduction, the defect was closed by a patch instead of direct suturing to prevent cardiac tamponade.

In conclusion, cardiac herniation is a life-threatening complication of intrapericardial pneumonectomy, leading to cardiopulmonary decompensation. It is therefore mandatory to recognize and rapidly manage the complication

as early as possible to save the patient's life. Prophylactic measures should be applied to all patients undergoing pneumonectomy; for example, closure of the pericardial defect, avoidance of using negative pressure suction and avoidance of repositioning the patient to surgical side down.

References

1. Takita H, Mifares WS. Herniation of the heart following intrapericardial pneumonectomy. Report of a case and review. *J Thorac Cardiovasc Surg* 1970 Mar; 59(3): 443 - 6
2. Beltrami V, Catenacci N. Cardiac herniation following intrapericardial pneumonectomy. *Acta Chir Belg* 1977 May; 76(3): 293 - 5
3. Deiraniya AK. Cardiac herniation following intrapericardial pneumonectomy. *Thorax* 1974 Sep; 29(5): 545 - 52
4. Bettman RB, Tannenbaum WJ. Herniation of the Heart: Through a Pericardial Incision. *Ann Surg* 1948 Nov; 128(5): 1012 - 4
5. Boxall R. Incomplete pericardial sac; escape of heart into the left pleural cavity. *Transactions: Obstetrical Society of London* 1886; 28: 209
6. Bruning EG. Congenital defect of the pericardium. *J Clin Pathol* 1962 Mar; 15: 133 - 5
7. Warburg R. Subacute and Chronic Pericardial and Myocardial Lesions Due to Non Penetrating Traumatic Injuries. London: Oxford University Press, 1938
8. Kimura T, Chiba Y, Ihaya A, Sasaki M, Taniguchi T, Hiramatsu Y. A case of acute right coronary artery occlusion with cardiac herniation following right pneumonectomy. *J Jpn Assoc Chest Surg* 1999; 13: 660 - 4

9. Ohri SK, Siddiqui AA, Townsend ER. Cardiac torsion after lobectomy with partial pericardectomy. *Ann Thorac Surg* 1992 Apr; 53(4): 703 - 5
10. Baaijens PF, Hasenbos MA, Lacquet LK, Dekhuijzen PN. Cardiac herniation after pneumonectomy. *Acta Anaesthesiol Scand* 1992 Nov; 36(8): 842 - 5
11. Self RJ, Vaughan RS. Acute cardiac herniation after radical pleuropneumonectomy. *Anaesthesia* 1999 Jun; 54(6): 564 - 6
12. Gates GF, Sette RS, Cope JA. Acute cardiac herniation with incarceration following pneumonectomy. *Radiology* 1970 Mar; 94(3): 561 - 2
13. Tschersich HU, Skorapa V, Fleming WH. Acute cardiac herniation following pneumonectomy. *Radiology* 1976 Sep; 120(3): 546
14. Arndt RD, Frank CG, Schmitz AL, Haveson SB. Cardiac herniation with volvulus after pneumonectomy. *AJR Am J Roentgenol* 1978 Jan; 130(1): 155 - 6
15. Yacoub MH, Williams WG, Ahmad A. Strangulation of the heart following intrapericardial pneumonectomy. *Thorax* 1968 May; 23(3): 261 - 5
16. Patel DR, Shrivastav R, Sabety AM. Cardiac torsion following intrapericardial pneumonectomy. *J Thorac Cardiovasc Surg* 1973 Apr; 65(4): 626 - 8
17. Hidvegi RS, Abdalnour EM, Wilson JA. Herniation of the heart following left pneumonectomy. *J Can Assoc Radiol* 1981 Sep; 32(3): 185 - 7
18. Wright MP, Nelson C, Johnson AM, McMillan IK. Herniation of the heart. *Thorax* 1970 Nov; 25(6): 656 - 64
19. Vanoverbeke HM, Schepens MA, Knaepen PJ. Acute cardiac herniation following intrapericardial pneumonectomy. *Acta Chir Belg* 1998 Mar; 98(2): 98 - 100
20. Cassorla L, Katz JA. Management of cardiac herniation after intrapericardial pneumonectomy. *Anesthesiology* 1984 Apr; 60(4): 362 - 4
21. Veronesi G, Spaggiari L, Solli PG, Pastorino U. Cardiac dislocation after extended pneumonectomy with pericardioplasty. *Eur J Cardiothorac Surg* 2001 Jan; 19(1): 89 - 91
22. Sasidharan B, Moideen I, Warriar G, Prabhu A, Koshy S, Nair SG, Gururaja RS, Shivaprakasha K. Cardiac herniation following closure of atrial septal defect through limited posterior thoracotomy. *Interact Cardiovasc Thorac Surg* 2006 Jun; 5(3): 272 - 4