

Suprascapular nerve entrapment : a case report of an uncommon site and uncommon pathology of the lesion

Somsak Kuptniratsaikul* Vilai Kuptniratsaikul**
Songpoj Tanprasert*** Ittee Chonmaitri****

Kuptniratsaikul S, Kuptniratsaikul V, Tanprasert S, Chonmaitri I. Suprascapular nerve entrapment : a case report of an uncommon site and uncommon pathology of the lesion. Chula Med J 2002 Feb; 46(2): 155 - 62

The authors report a case of entrapment neuropathy of the suprascapular nerve with an uncommon pathology, and clinically manifested as a frozen shoulder. A 56-year-old man with right shoulder pain was referred to the orthopaedic clinic. He was shown to have a suprascapular nerve lesion without seriously acute shoulder injury. The neuropathy was a result of a mass posterior to the coracoid process, between the suprascapular and the spinoglenoid notches. The space had never been reported before as a site of suprascapular nerve entrapment. The pathology of the specimen from the patient was fibrolipoma, one of a solid tumor, uncommon cause of the suprascapular nerve compression. The precipitating cause was probably due to the patient's occupation, which was a kind of labor which exposed him to repetitive trauma. overhead lifting a 10-pounds hammer and to smash sticky bean into flat pancake for 5 hours every day. The mechanism seemed similar to repetitive micro-trauma of the gleno-humeral joint of volleyball players that were reported to be prone to suprascapular nerve entrapment, caused by glenoid labral cyst extending from the coraco-glenoid to the scapular notch.

Key words : *Suprascapular nerve, Entrapment, Base of coracoid process, Fibrolipoma, Occupation.*

Reprint request : Kuptniratsaikul S, Department of Orthopaedics, Faculty of Medicine, Chulalongkorn University, Bangkok 10330, Thailand.

Received for publication. December 15,2001.

* Department of Orthopaedics, Faculty of Medicine, Chulalongkorn University

** Department of Rehabilitation Medicine, Faculty of Medicine, Mahidol University

*** Department of Rehabilitation Medicine, Faculty of Medicine, Chulalongkorn University

**** Department of Pathology, Faculty of Medicine, Chulalongkorn University

สมศักดิ์ คุปต์นิรติศัยกุล, วิไล คุปต์นิรติศัยกุล, ทรงพจน์ ต้นประเสริฐ, อิตถี ชนไมตรี. การกดทับเส้นประสาท *suprascapular* ในตำแหน่งและพยาธิสภาพที่พบบ่อย: รายงานผู้ป่วย. *จุฬาลงกรณ์เวชสาร* 2545 ก.พ; 46(2): 155 - 62

คณะผู้วิจัยได้รายงานผู้ป่วย 1 ราย ที่มีอาการของเส้นประสาท *suprascapular* ถูกกดทับ โดยอาการนำที่มาพบแพทย์คือหัวไหล่ติด ผู้ป่วยไม่มีประวัติบาดเจ็บข้อไหล่มาก่อน ได้รับการยืนยันโดยเครื่องตรวจเส้นประสาทและกล้ามเนื้อด้วยไฟฟ้า จากการผ่าตัดพบว่าก้อนที่กดเส้นประสาทมีพยาธิสภาพเป็นก้อน *fibrolipoma* ซึ่งมีรายงานไม่บ่อย และตำแหน่งที่พบเป็นตำแหน่งที่ไม่เคยมีรายงานมาก่อนเลย คือ บริเวณด้านหลังต่อโคนของ *coracoid process* ระหว่าง *suprascapular notch* และ *spinoglenoid notch* ปัจจัยเสี่ยงในผู้ป่วยรายนี้คือมีอาชีพทำถั่วตัด ซึ่งต้องใช้กำลังแขนยกหม้อหนักทูนน้ำตาลที่เคี่ยวนเหนียวขึ้นเป็นประจำทุกวัน ๆ ละ 5 ชั่วโมง ซึ่งมีกลไกคล้ายการบาดเจ็บสะสมที่บริเวณข้อ *glenohumeral* ในนักกีฬาบอลเลย์บอลล์ ที่มักพบการกดทับเส้นประสาท *suprascapular* จากการฉีกขาดบริเวณหมอนรองกระดูกข้อไหล่ (*glenoid labral*) แล้วมีการดำเนินโรคต่อไปเป็น *ganglion cyst* จึงมักพบพยาธิสภาพนี้บริเวณ *spinoglenoid notch* ของกระดูก *scapula*

Reports about suprascapular nerve entrapments are increasing, mostly concerned the spinoglenoid notch.⁽¹⁻⁷⁾ The site of the lesion causes isolated atrophy of the infraspinatus muscle, innervated by the infraspinatus branch of the suprascapular nerve. A common pathology of nerve compression at the location is a ganglion cyst, originated from a glenoid labral tear that extended periarticularly into a ganglion cyst.^(1,5-14)

There were two common sites of entrapment reported in many literatures one was the classical description of the superior transverse scapular ligament as a completely modified single band (the suprascapular notch), and the other, the spinoglenoid notch, the true incidence of the latter is still unknown.⁽²⁾

As for the pathology, a partial or a complete ossification and anomalous band of the superior transverse scapular ligament or a ganglion cyst along the course of the scapular nerve may be encountered.⁽⁷⁾

In 1998 Ticker et al.⁽⁵⁾ examined seventy-nine shoulders of 41 cadavers for anatomical variations and for ganglion cyst formation, in the suprascapular notch, and the superior transverse scapular ligament. In 23 % of the shoulders, a variation of the superior transverse scapular ligament was demonstrated. A ganglion cyst was identified with an incidence of 1 %. The mass was located in the suprascapular fossa, adjacent to the superior transverse scapular ligament. In 1998, Demirhan et al.⁽¹⁵⁾ described isolated infraspinatus muscle atrophy and denervation, attributed to a compression of the muscle's motor branch at the spinoglenoid notch. The role of the spinoglenoid ligament in entrapment neuropathy of the infraspinatus was presented in 60.8 % of the samples.

The authors report a case of suprascapular nerve entrapment that was not common on several accounts; it was associated with the type of the patient's labor work, solitary tumor cause, and the location of the mass.

Case report

A 56-year-old man with a right shoulder pain was referred to our orthopedic clinic with an atrophy of the supraspinatus and the infraspinatus muscles of his right shoulder. He had formerly noticed his right shoulder pain for 5 months, when there was no weakness of the muscles. A physiatrist had diagnosed him of a frozen right shoulder on his first visit, and later suprascapular nerve entrapment of the right shoulder. After a thorough physical examination and investigation and he was referred to us in June 2001. He was earlier admitted into the Department of Psychiatry with a diagnosis of bipolar manic depressive. The condition was well controlled with lithium salt and monitored by lithium blood level periodically. The patient remembered no significant trauma to his right shoulder.

His physical examination revealed a significant atrophic change of the infraspinatus muscle with some degree of atrophy of the supraspinatus. The manual muscle tests of the right infraspinatus and the supraspinatus muscles were grade III/V and grade IV/V respectively. On palpation, there was no abnormal mass nor trigger point at the affected area. The range of motion of the glenohumeral joint were limited, by a deep dull aching pain on passive movement.

Active range of motion of the glenohumeral joint was markedly limited in external rotation, due to a weakness of the infraspinatus (Figure 1) and initial

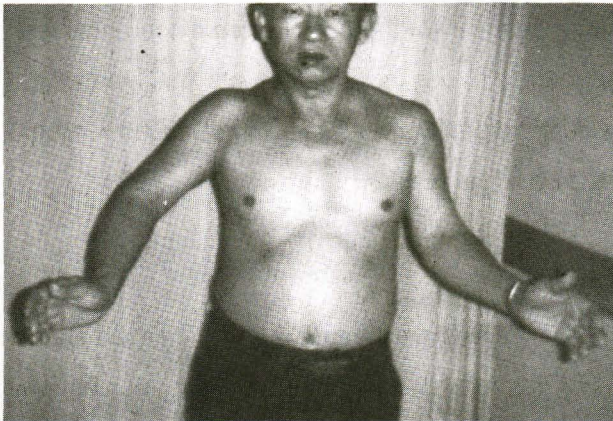

Figure 1. The patient tried to abduct right shoulder in compensation with the weakness of right infraspinatus muscle.

abductor had 60° abduction, due to a weakness of supraspinatus. Other muscle power around the right shoulder girdle was grade V/V. No significant fasciculation was found, neither with the supraspinatus nor the infraspinatus muscles. Also, there was no area of decreased pinprick sensation noted.

His electrodiagnosis (EMG) revealed 3+ fibrillation with 2+ positive sharp wave of the right infraspinatus muscle and polyphasic motor unit including incomplete recruitment; 1+ fibrillation with 1+ positive sharp wave of the right supraspinatus muscle and polyphasic motor unit including incomplete recruitment. The EMG evidences of other muscles were normal (Table 1). The results of essential blood chemistry were normal.

Plain radiographs of the right shoulder showed no abnormality. MRI in the case was not performed due to financial limitation.

From the information mentioned we concluded that this patient suffered from suprascapular nerve entrapment between the suprascapular and the spinoglenoid notches; however, the nature of the lesion that caused the clinical manifestation was still in doubt, before the outcome of tissue histopathology was reported.

An excision was performed. We did the suprascapular approach. According to the EMG outcome, the location of the lesion was just above the

Table 1. The EMG of right infraspinatus and supraspinatus muscles.

Needle EMG Examination					
Muscles	IA*	Fib**	PSW***	Motor Unit	Recruitment
Infraspinatus	Increase	3+	2+	Polyphasic	Incomplete
Supraspinatus	Increase	1+	1+	Polyphasic	Incomplete
Deltoid	Normal	No	No	Normal	Complete
Biceps Brachii	Normal	No	No	Normal	Complete
Triceps Brachii	Normal	No	No	Normal	Complete
C5-6 Paraspinal	Increase	No	1+	Normal	-
Serratus anterior	Normal	No	No	Normal	Complete

* IA = Insertional activity, ** Fib = Fibrillation, *** PSW = Positive sharp wave

spinoglenoid notch. The mass was located posterior to the base of the coracoid process, between the suprascapular and the infrascapular notches. It was a small area where we normally identify the suprascapular vessels, medial to the superior transverse scapular ligament, which concealed the suprascapular nerve lying underneath. After the suprascapular nerve properly passed the suprascapular notch, it turned laterally to the spinoglenoid notch. At the fossa, the mass appeared to compress and alter the course of the suprascapular nerve. Both the suprascapular and the spinoglenoid notches were space-limited boundaries with firm structure (upper border scapular with transverse scapular ligament, and spine of scapular with glenoid rim). But the tumor was located between the two areas bounded by the posterior of the coracoid process, the spinoglenoid rim and spine of the scapular. It was just infero-lateral to the suprascapular notch and, superomedial to the spinoglenoid notch.

The tumor was ovoid shaped soft tissue mass with whitish, well-circumscribed outer surface capsule. There was neither villous proliferation on the surface



Figure 2. Histopathology of the tumor mass: fibrolipoma.

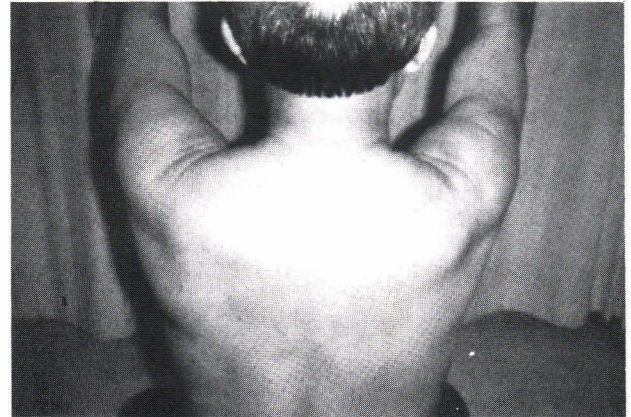


Figure 3. Improved muscle power of supraspinatus and infraspinatus muscles three months after surgery.

nor definite stalk. It was not directly adhered to the glenohumeral joint capsule. The lesion was easily and completely removed. The cut surface of the mass showed lipomatous tissue. Its histological examination revealed a proliferation of benign lipocytes (Figure 2). Collagen bundles were seen between the areas of tumor cells, which were relatively thick, compared with those seen in most lipomas. Mitotic activity was absent; a careful searching failed to reveal lipoblasts or malignant cells. The capsule of the tumor was composed of thin collagenous tissue. Synovial lining cells were absent on the surface of the capsule.

The postoperative course was uneventful three months after the surgery. The patient gained more power of the supraspinatus and the infraspinatus muscles (Figure 3). The degree of his dull aching pain of the shoulder was decreasing with time.

Discussion

Many reports located suprascapular nerve entrapment at the spinoglenoid notch.⁽¹⁻⁷⁾ In this report, however, we found that the entrapment at a fossa posterior to the coracoid process, between the suprascapular and the spinoglenoid notches. The location had never been reported before as a site of suprascapular nerve entrapment. Clinically, our patient presented with his right shoulder pain, and a definite atrophy of the infraspinatus muscle and a mildly atrophy of the supraspinatus muscle. The EMG findings were compatible with right suprascapular nerve entrapment, involving branches to both the supraspinatus and the infraspinatus muscles, but it was more prominent at the [nerve?] branches to the infraspinatus muscle.

The patient also had a history of deep aching pain which was similar to some reports^(4,7,8,12,13,16) even the classic teaching regarded the suprascapular nerve had no cutaneous branches. In particular, he had weakness of the infraspinatus muscle predominated to the supraspinatus weakness, which was corresponding to the EMG findings.

The pathology of the condition was usually attributed to a ganglion cyst. The cystic lesions were hypothesized to be generated from a glenoid labral tear with its chronic progression into a ganglion cyst at the spino-glenoid notch, common cause of suprascapular nerve entrapment from ganglion cysts was reported in many literatures.^(5,13,17) Moore et al⁽¹⁸⁾ reported twenty-two ganglion cysts in twenty-one patients. Sixteen of the shoulders were operated by three surgeons. Five of the shoulders were treated with open resection alone; six with a combined arthroscopic and open procedure, and five with

arthroscopic decompression of the cyst. The operative technique was chosen according to the preference of the operating surgeons. Fifteen of the sixteen patients had a good or excellent result. The results were not separated according to the type of operative treatment. Unlike many reports mentioned above, the pathology of specimen from our patient was fibrolipoma, which was a type of solid tumor that was uncommon cause of suprascapular nerve compression. The mass was solitary, round and well- capsulated fat tissue. The sections revealed its nature; adipose tissue enclosed by a thin fibrous capsule, fibrolipoma of soft tissue. The lesion had no essentially distinctive vascular stalk. The tumor mass showed a well-demarcated border and was composed of mature lipocytes and fibrous tissue.

As for the pathogenesis, most patients were often related to sports particularly overhead smashing activity, such as a volleyball and baseball. The patient's occupation was kind of labor which exposed him to repetitive trauma. His activity was over head lifting 10 pounds hammer and smashing sticky bean to be flat pancake for 5 hours every day. [You should add for the number of years he had been doing this job] the incidence was similar to repetitive micro-trauma of the gleno-humeral joints in volleyball players that were reported associated to suprascapular nerve entrapment caused by glenoid labral cysts extended from the coraco-glenoid to the scapular notch.

Antoniou J, et al,⁽¹⁾ reported functional outcomes of operative and non-operative treatments of suprascapular neuropathy. Fifty-three patients were evaluated at least for 1 year from the time of the operative and the non-operative treatments. A modified American shoulder and elbow surgeon self-

assessment score was obtained at presentation and at the first follow-up. Overall, the treatment resulted in significant functional improvement, but it also varied according to the etiology of the injury. A spinoglenoid notch cyst significantly responded to the operative treatment. In addition, a compression lesion, attributed to suprascapular notch entrapment, had the best improvement with surgical decompression. A traumatized lesion, including traction and direct closed injuries, equally responded to operative and non-operative treatments. The outcome of treatment depended on the severity and etiology of the nerve injury, and the method of treatment.

The postoperative course of the patient was uneventful; three months after the surgery, the patient was doing well with improving muscle power of the supraspinatus and the infraspinatus. The degree of his dull aching pain of the shoulder was also decreasing. He regained the strength of his shoulder abduction dramatically, followed by a gradual recovery of the strength of external rotation. Also, the residual muscle atrophy had a trend of strength recovery.

In summary, the authors reported a case of suprascapular nerve neuropathy, which manifested as a frozen shoulder. The entrapment neuropathy had an unusual site and uncommon pathology. The lesion was posterior to the coracoid process, between the suprascapular and the spinoglenoid notches. The location had never been reported before as a site of suprascapular nerve entrapment. The pathology was fibrolipoma, a solid tumor that was uncommon cause of a suprascapular nerve compression. The cause was attributed to the patient's occupation, a labor with repetitive trauma.

References

1. Antoniou J, Tae SK, Williams GR, Bird S, Ramsey ML, Iannotti JP. Suprascapular neuropathy. Variability in the diagnosis, treatment, and outcome. *Clin Orthop* 2001 May (386): 131-8
2. Cummins CA, Bowen M, Anderson K, Messer T. Suprascapular nerve entrapment at the spinoglenoid notch in a professional baseball pitcher. *Am J Sports Med* 1999 Nov-Dec; 27 (6):810 - 2
3. Van Zandijcke M, Casselman J. Suprascapular nerve entrapment at the spinoglenoid notch due to a ganglion cyst. *J Neurol Neurosurg Psychiatry* 1999 Feb; 66(2): 245
4. Ferretti A, De Carli A, Fontana M. Injury of the suprascapular nerve at the spinoglenoid notch. The natural history of infraspinatus atrophy in volleyball players. *Am J Sports Med* 1998 Nov-Dec; 26(6): 759 - 63
5. Ticker JB, Djurasovic M, Strauch RJ, April EW, Pollock RG, Flatow EL, Bigliani LU. The incidence of ganglion cysts and other variations in anatomy along the course of the suprascapular nerve. *J Shoulder Elbow Surg* 1998 Sep-Oct; 7(5): 472 - 8
6. Chochole MH, Senker W, Meznik C, Breitenseher MJ. Glenoid-labral cyst entrapping the suprascapular nerve: dissolution after arthroscopic debridement of an extended SLAP lesion. *Arthroscopy* 1997 Dec; 13(6): 753 - 5
7. Levy P, Roger B, Tardieu M, Ghebontni L, Thelen P, Richard O, Grenier P. Cystic compression of the suprascapular nerve. Value of imaging. Apropos of 6 cases and review of the literature. *J Radiol* 1997 Feb; 78(2): 123 - 30

8. Antoniadis G, Richter HP, Rath S, Braun V, Moese G. Suprascapular nerve entrapment: experience with 28 cases. *J Neurosurg* 1996 Dec; 85(6):1020 - 5
9. Padua L, LoMonaco M, Padua R, Gregori B, Valente EM, Tonali P. Suprascapular nerve entrapment. Neurophysiological localization in 6 cases. *Acta Orthop Scand* 1996 Oct; 67(5): 482 - 4
10. Biedert RM. Atrophy of the infraspinatus muscle caused by a suprascapular ganglion. *Clin J Sport Med* 1996 Oct; 6(4): 262 - 4
11. Wang DH, Koehler SM. Isolated infraspinatus atrophy in a collegiate volleyball player. *Clin J Sport Med* 1996 Oct; 6(4): 255 - 8
12. Bousquet JC, Denjean S, Faure C, Venin B, Bochu M. Synovial cyst involving isolated paralysis of the infraspinatus muscle. Ultrasonographic diagnosis and MRI. *J Radiol* 1996 Apr; 77(4): 275 - 7
13. Rachbauer F, Sterzinger W, Frischhut B. Suprascapular nerve entrapment at the spinoglenoid notch caused by a ganglion cyst. *J Shoulder Elbow Surg* 1996 Mar-Apr; 5(2 Pt 1):150 - 2
14. Uppal GS, Uppal JA, Dwyer AP. Glenoid cysts mimicking cervical radiculopathy. *Spine* 1995 Oct 15; 20(20): 2257 - 60
15. Demirhan M, Imhoff AB, Debski RE, Patel PR, Fu FH, Woo SL. The spinoglenoid ligament and its relationship to the suprascapular nerve. *J Shoulder Elbow Surg* 1998 May-Jun; 7(3): 238 - 43
16. Harbaugh KS, Swenson R, Saunders RL. Shoulder numbness is a patient with suprascapular nerve entrapment syndrome: cutaneous branch of the suprascapular nerve: case report. *Neurosurgery* 2000 Dec; 47(6): 1452 - 6
17. Iannotti JP, Ramsey ML. Arthroscopic decompression of a ganglion cyst causing suprascapular nerve compression. *Arthroscopy* 1996 Dec; 12(6): 739 - 45
18. Moore TP, Fritts HM, Quick DC, Buss DD. Suprascapular nerve entrapment caused by supraglenoid cyst compression. *J Shoulder Elbow Surg* 1997 Sep-Oct; 6(5): 455 - 62