

## Middle fossa approach for removal of acoustic neuroma: case reports and literature review

Permsarp Isipradit\* Chopeow Taecholarn\*\*

Kanate Vaewichit\* Saowaros Asawavichianginda\*

**Isipradit P, Taecholarn C, Vaewichit K, Asawavichianginda S. Middle fossa approach for removal of acoustic neuroma: cases reports and literature review. Chula Med J 2003 Sep; 47(9): 567 - 75**

*There are 3 approaches for the surgical treatment of acoustic neuroma namely: 1) translabyrinthine approach 2) retrosigmoid approach, and 3) middle fossa approach. The middle fossa approach was used for the removal of small or intracanalicular tumors, with or without serviceable hearing. The first case presented with severe right sensorineural hearing loss and facial palsy; the second with progressive sensorineural hearing loss. MRI showed an intracanalicular acoustic tumor without cerebellopontine angle extension. The middle fossa approach for tumor removal was done in both cases without any serious complication. In the first case, the function of the facial nerve returned from grade V to grade III (House-Brackmann grading system), and the hearing of the second case was preserved. This is the first report which shows that the middle fossa approach is safe in selected case for surgical removal of acoustic neuroma.*

**Keywords:** Middle fossa, acoustic neuroma, approach.

Reprint request: Isipradit P. Department of Otolaryngology, Faculty of Medicine,  
Chulalongkorn University, Bangkok 10330, Thailand.

Received for publication: June 15, 2003.

\* Department of Otolaryngology, Faculty of Medicine, Chulalongkorn University

\*\* Department of Surgery, Faculty of Medicine, Chulalongkorn University

เพิ่มทรัพย์ อธิประวัติ, ช่อเพ็ญ เตโชสาร, คณศร์ แวรวิจิต, เสาวรส อัครวิเชียรจินดา. การผ่าตัดรักษาเนื้องอกของเส้นประสาทสมองคู่ที่ 8 โดยวิธี middle fossa : รายงานผู้ป่วยและ ทบทวนวารสาร. จุฬาลงกรณ์เวชสาร 2546 ก.ย; 47(9): 567 - 75

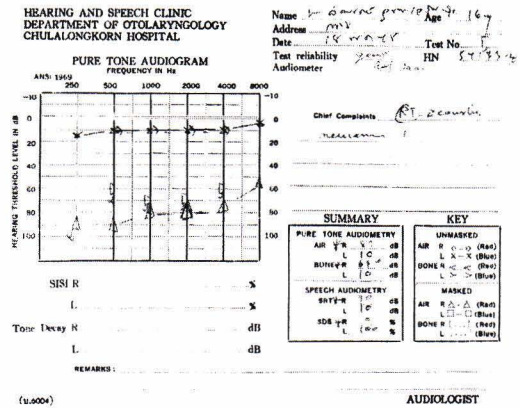
การผ่าตัดรักษาเนื้องอกของเส้นประสาทสมองคู่ที่ 8 มีอยู่ 3 วิธีคือ 1. translabyrinthine 2. retrosigmoid 3. middle fossa ซึ่งวิธีการผ่าตัดโดยวิธี middle fossa จะเลือกใช้ในกรณีที่เนื้องอก มีขนาดเล็กและอยู่ในช่องหูส่วนใน ส่วนการได้ยินอาจจะปกติหรือมีการสูญเสียการได้ยินก็ได้ ผู้ป่วย รายแรกมีอาการสูญเสียการได้ยินอย่างรุนแรงร่วมกับอาการอัมพาตของเส้นประสาทที่เลี้ยงใบหน้า ด้านขวา ผู้ป่วยรายที่ 2 มีอาการประสาทหูเสื่อมอย่างต่อเนื่อง การตรวจทางคลื่นแม่เหล็กพบก้อน เนื้องอกของเส้นประสาทสมองคู่ที่ 8 ขนาดเล็กอยู่ภายในช่องหูส่วนใน ไม่มีการยื่นออกมาบริเวณช่อง ระหว่างสมองน้อยและก้านสมอง ผู้ป่วยทั้งสองรายได้รับการผ่าตัดโดยวิธี middle fossa และไม่มี ภาวะแทรกซ้อนที่รุนแรง รายแรกมีการกลับคืนการทำงานของกล้ามเนื้อใบหน้าจากชั้นที่ 5 เป็นชั้นที่ 3 (โดยระบบของ House-Brackmann) รายที่ 2 สามารถรักษาระดับ การได้ยินไว้ได้ใกล้เคียงกับก่อน การผ่าตัด รายงานนี้เป็นรายงานฉบับแรกและบ่งบอกว่าการผ่าตัดโดยวิธี middle fossa มีความ ปลอดภัยในรายที่คัดเลือกแล้ว

Acoustic neuroma is benign schwannoma that arises from the eight cranial nerve in the internal acoustic canal and cerebellopontine angle. The priorities in the surgery of acoustic neuroma are, namely: 1) complete removal of the tumor, 2) preservation of the function of the facial nerve, 3) avoiding injury to the brain, and 4) preservation of hearing (if possible).<sup>(1-4)</sup> There are three surgical approaches for the resection of acoustic neuroma, namely: 1) translabyrinthine approach, 2) retrosigmoid approach, and 3) middle fossa approach.<sup>(5)</sup> The criteria for the selection of the appropriate surgical approach depends on the following conditions, namely: the age of the patient, general health of the patient, pre-operative hearing disease and the condition of the contralateral ear, the size of the tumor, etc. We hereby present two cases of intracanalicular acoustic neuroma that were successfully removed by middle fossa approach.

**Case reports**

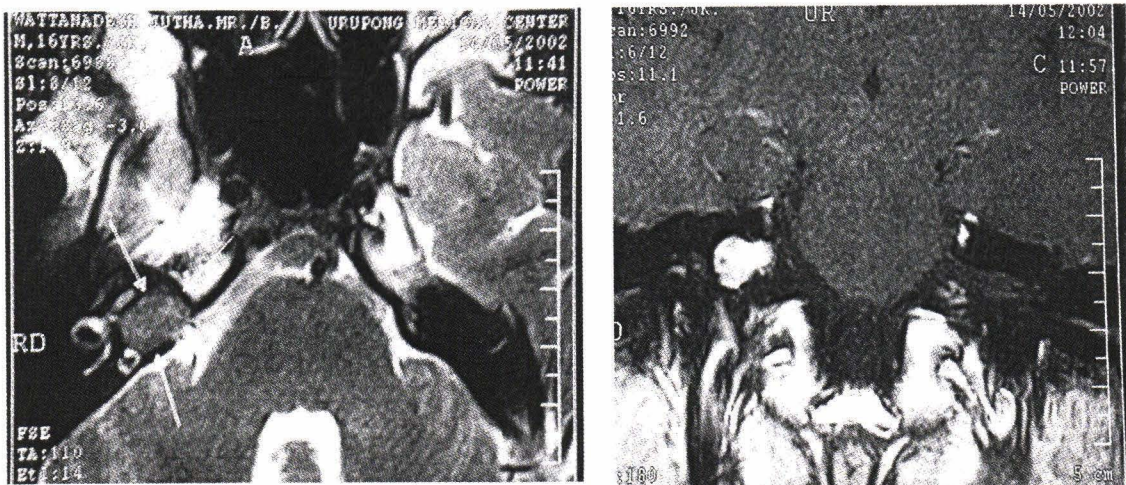**Case 1.**

A 16-year-old man presented with progressive right sensorineural hearing loss with tinnitus for 8 months and a sudden onset of right facial palsy



**Figure 1.** Audiogram in case 1.

for one week. Examination showed right deafness and complete facial palsy of lower motor neurone type; other neurological and vestibular examination were normal. Audiogram showed right deafness (Figure 1). The magnetic resonance imaging (MRI) showed a round mass in the right internal acoustic canal (IAC) size 1.2 cm in diameter, obliterating the visualization of right cranial nerve 7-8 complex in the internal acoustic canal (Figure 2). The signal of the tumor was isosignal to the brainstem on both T1w, T2w. The provisional diagnosis was schwannoma of cranial nerve 8. The patient underwent middle fossa approach for surgical removal of the tumor.



**Figure 2.** MRI in case 1.

Case 2.

A 52-year-old Thai female presented with left progressive sensorineural hearing loss for one month. She had normal physical examination except left sensorineural hearing loss. The audiometric finding was left high frequency sensorineural hearing loss with speech reception threshold (SRT) = 40 dB and speech discrimination score = 60 % (Figure 3). The results of auditory brainstem response (Figure 4) showed delayed absolute wave V latency of the left when compared to the right ear (7.07; 5.41 msec).

MRI (Figure 5) showed a small lesion at cranial nerve 7-8 complex in the internal acoustic canal that occupied the entire IAC; no cerebelloponine angle extension was detected. The provisional diagnosis was acoustic neuroma. The management options were discussed and the final solution was middle fossa approach for surgical removal of the tumor with concerns for the preservation of the facial nerve function and hearing. The surgical approach was the same as in the first case.

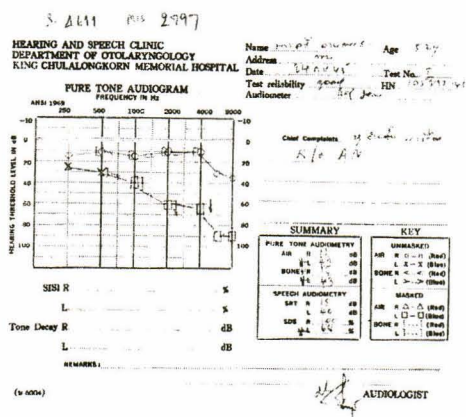


Figure 3. Audiogram in case 2.

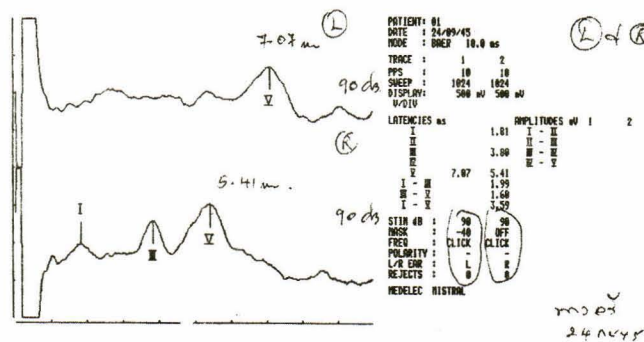


Figure 4. Auditory brainstem response in case 2.

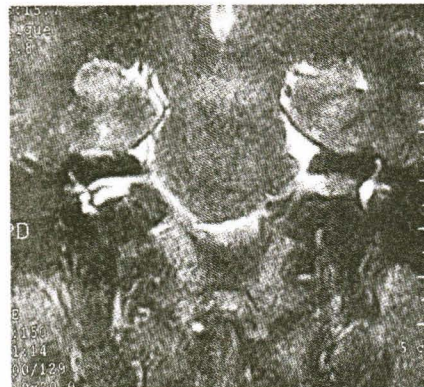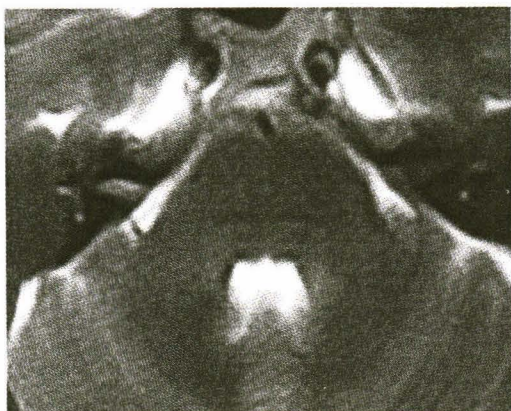
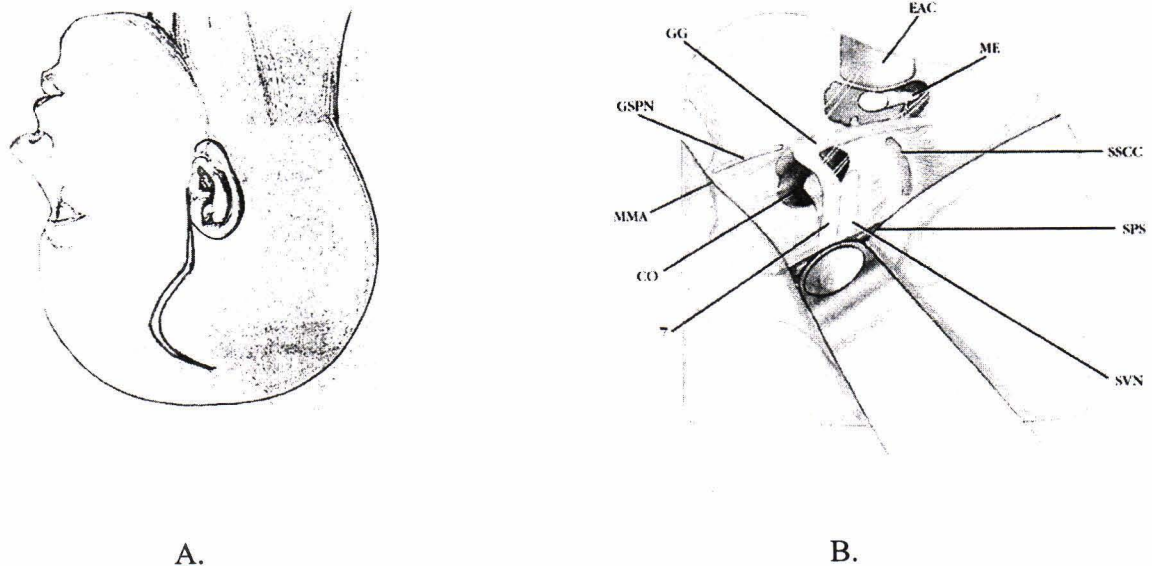


Figure 5. MRI in case 2.



**Figure 6.** A. preauricular skin incision

B. surgical landmark GSPN = greater superficial petrosal nerve, GG = geniculate ganglion, MMA = middle meningeal artery, CO = cochlea, 7 = facial nerve, SVN = superior vestibular nerve, SPS = superior petrosal sinus, SSCC = superior semicircular canal, ME = middle ear, EAC = external auditory canal.

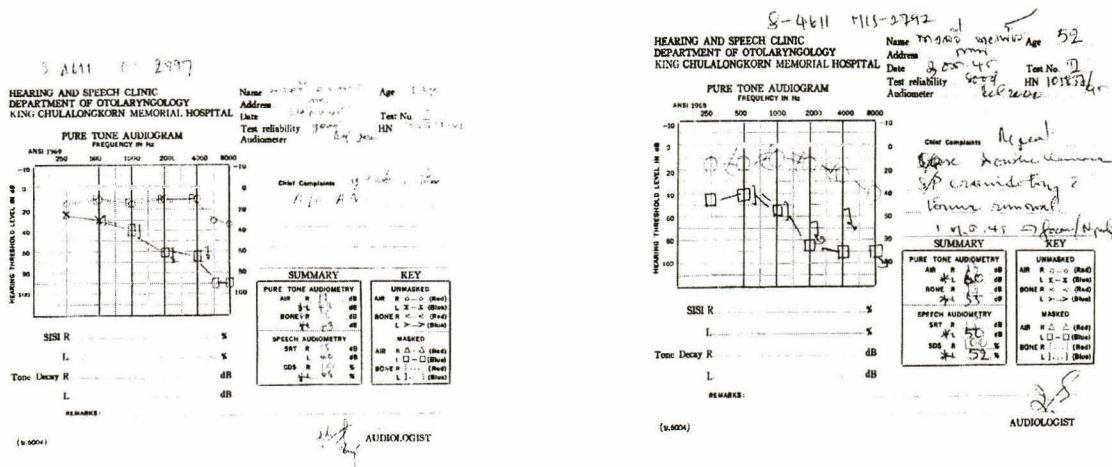
### **Surgical approach** <sup>(2,6,7)</sup> (Figure 6)

A pre-auricular skin incision was made and extended along the temporal region and then curved from anterior to posterior. The temporalis muscle was reflected anterior-inferiorly. A 5 x 5 cm craniotomy was developed, just superior to the zygomatic root and two-thirds anterior to the external auditory canal. The temporal lobe was retracted and the floor of the middle cranial fossa was exposed by dissecting posterior to anterior direction, to identify middle meningeal artery and greater superficial petrosal nerve (GSPN), but the arcuate eminence could not be seen clearly. The IAC was located by tracing back along the GSPN in the first case and making a 60 degree angle anterior to SSCC in the second case. Then the bone around the porus was widely removed at an arc of approximately 270 degree and at the

fundus was at 90 degree, with diamond burrs, burring with continuous suction irrigation. The tumor originated from vestibular nerve. The facial nerve was then separated from the tumor, and the cochlear nerve was anatomical preserved. The IAC was sealed with a piece of muscle and the flap was replaced.

### **Results**

Postoperatively, the patients had no evidence of meningitis, cerebrospinal fluid leakage or other intracranial complication. In the first case, the preoperative facial nerve function test (according to House-Brackmann grading system) was grade V, which returned to grade III at 12 month postoperatively; in the second case, the facial nerve function was normal preoperatively, grade VI when tested immediately after the operation, and grade III at



A.

B.

Figure 7. Audiogram in case 2 A. preop B. postop

6 month postoperatively. Concerning the hearing, in the second cases it was preserved at a serviceable hearing level (Figure 7).

**Discussion**

Acoustic neuroma is the most common tumor of the cerebellopontine angle. Its annual incidence is approximately 1 per 100,000 population. The treatment of choices are, namely: 1) microsurgery, 2) radiosurgery, 3) observation, depending on age, size, general condition, compressive symptoms, etc.<sup>(8)</sup>

There are 3 surgical approaches employed in the surgical removal of acoustic neuroma, namely: 1) translabyrinthine approach, 2) retrosigmoid approach, and 3) middle fossa approach. The priorities of the surgical operations are as follows: 1) complete remove the tumor, 2) preservation of the facial nerve function, 3) avoiding injury to the brain, 4) preservation of hearing (if possible).<sup>(1-4)</sup>

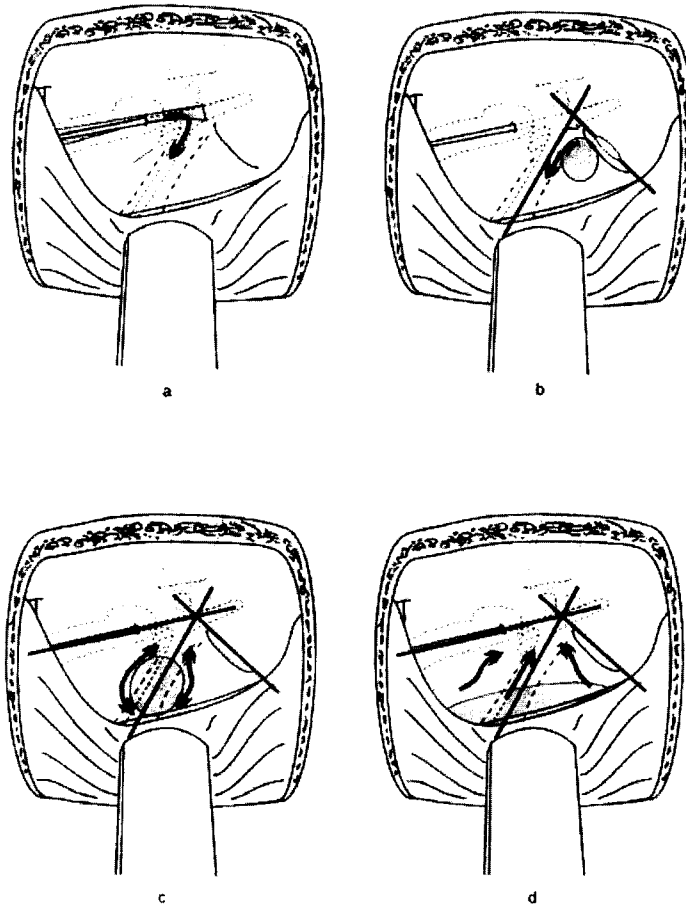
The middle fossa approach offers only limited exposure in the posterior fossa, therefore it is suitable

for intracanalicular tumor that extends less than 1 cm beyond the *porus acoussticus* into the posterior fossa. This approach is not usually recommended for patients who are older than 65 years because the dura of these patients is more adherent and fragile. There are 3 techniques (Figure 8) for identification of internal acoustic canal in the middle fossa approach.<sup>(2,7,9,10)</sup>

**1. House technique:** By tracing the greater superficial petrosal nerve (GSPN) back to the facial hiatus and to the geniculate ganglion, the facial nerve is then traced retrograde into the IAC and further exposure of the IAC is accomplished.

**2. Fisch technique:** The arcuate eminence is drilled until the blue line of the superior semicircular canal is seen, and then traced toward the ampulla. The relation of superior vestibular nerve to the ampulla is used to identify the IAC (about 60 degree angle).

**3. Garcia-Ibanez technique:** The IAC location is on the plane even to the EAC and bisecting at an angle formed by the GSPN and arcuate eminence (dome of SSCC). First drilling at the medial aspect



**Figure 8.** Technique for identification of IAC in middle fossa approach  
a. House technique b. Fisch technique c,d. Garcia – Ibanez technique.

of this line gives an additional exposure which offers significant advantage for the tumor resection.

### Hearing result

There are 2 surgical approaches which preserve hearing in the resection of acoustic neuroma: 1) middle fossa approach, and 2) retrosigmoid approach. <sup>(2,4,6,11)</sup> The cochlear nerve integrity after the surgery is 69–100 %, but the measurable hearing is only 36.4 – 68 % in the middle fossa approach. For serviceable hearing (50 dB SRT/50 % SDS) is only 21 – 47 % in the middle fossa approach, but

6.6–54% in the retrosigmoid approach. <sup>(1,3,12)</sup> Therefore hearing loss despite auditory nerve preservation is likely from direct injury to the otic capsule or devascularization of the nerve. <sup>(2,3,13,14)</sup> There are many techniques that enhance the hearing preservation by using intraoperative auditory monitoring such as otoacoustic emissions (OAEs), auditory brainstem response (ABR), or direct cochlear nerve monitoring to detect injury as soon as possible. <sup>(1,7,15)</sup> It is very difficult to compare the hearing result given in each paper because the criteria of the hearing results are different.

### Facial nerve result

In the past, the facial nerve function for the middle fossa approach is less favorable than that of the translabyrinthine or the retrosigmoid approaches, since the facial nerve lies anterior to the tumor, so the nerve is manipulated more than in other techniques. Now reports of many series demonstrated excellent results (grade I-II, House-Brackmann system) even to 89-96 % which is very similar to other approaches.<sup>(1-3,12,16,17)</sup>

### Degree of tumor removal

The middle fossa approach allows a complete exposure of the lateral end of IAC which not only makes the blind dissection of the lateral end of the IAC unnecessary, but it also ensure the total removal of the tumor. In the retrosigmoid approach, hearing preservation is not attempted, unless the labyrinth is violated; 2 – 3 mm of the fundus cannot be exposed in the vast majority of the cases, therefore a small tumor may be left at the fundus.<sup>(1-5,7,18)</sup>

### Conclusion

The middle fossa craniotomy for surgical removal of acoustic tumor is suitable in selected case when the tumor is in the IAC or when it has extended into the cerebellopontine angle less than 1 cm, and the patient's age is under 65, and hearing preservation is attempted. The main advantage of the approach is complete exposure of the content of the internal acoustic canal that allows positive identification of the facial nerve and total removal of the tumor under direct vision.

### References

1. Slattery WH 3<sup>rd</sup>, Brackmann DE, Hitselberger W. Middle fossa approach for hearing preservation with acoustic neuromas. *Am J Otol* 1997 Sep; 18(5): 596 - 601
2. Weber PC, Gantz BJ, Results and complications from acoustic neuroma excision via middle cranial fossa approach. *Am J Otol* 1996 Jul; 17(4): 669 - 75
3. Shelton C, Brackmann DE, House WF, Hitselberger WE. Middle fossa acoustic tumor surgery: results in 106 cases. *Laryngoscope* 1989 Apr; 99(4): 405 - 8
4. Sanna M, Zini C, Mazzoni A, Gandolfi A, Pareschi R, Pasanisi E, Gamoletti R. Hearing preservation in acoustic neuroma surgery: middle fossa versus suboccipital approach. *Am J Otol* 1987 Nov; 8(6): 500 - 6
5. Haberkamp TJ, Meyer GA, Fox M. Surgical exposure of the fundus of the internal auditory canal: anatomic limits of the middle fossa versus the retrosigmoid transcanal approach. *Laryngoscope* 1998 Aug; 108(8 Pt 1): 1190 - 4
6. Glasscock ME, McKennan KX, Levine SC. Acoustic neuroma surgery: the results of hearing conservation surgery. *Laryngoscope* 1987 Jul; 97(7 Pt 1): 785 - 9
7. Brackmann DE, House JR 3<sup>rd</sup>, Hitselberger WE. Technical modifications to the middle fossa craniotomy approach in removal of acoustic neuromas. *Am J Otol* 1994 Sep; 15(5): 614 - 9
8. Isipradit P, Vaewvichit K, Taecholarn C, Asawavichianginda S, Aeumjaturapat S. Result of the translabyrinthine approach for acoustic neuroma removal. *Chula Med J* 2002 Aug; 46(8): 631 - 8
9. Tsunoda A, Komatsuzaki A, Kobayashi M, Suzuki Y. Three dimensional image for the middle fossa approach and its anatomical considera-



- tions. *Laryngoscope* 2001 Jun; 111(6): 1048 - 52
10. Sargent EW, Bucholz RD, Middle cranial fossa surgery with image-guided instrumentation. *Otolaryngol Head Neck Surg* 1997 Jul; 117(1): 131 - 4
11. Haines SJ, Levine SC. Intracanalicular acoustic neuroma: early surgery for preservation of hearing. *J Neurosurg* 1993 Oct;79(4):515 - 20
12. Satar B, Jackler RK, Oghalai J, Pitts LH, Yates PD. Risk – benefit analysis of using the middle fossa approach for acoustic neuromas with > 10 mm cerebellopontine angle component. *Laryngoscope* 2002 Aug;112 (8 Pt 1): 1500 - 6
13. Molony TB, Kwartler JA, House WF, Hitselberger WE. Extended middle fossa and retro-labyrinthine approaches in acoustic neuroma surgery: case reports. *Am J Otol* 1992 Jul; 13(4): 360 - 3
14. Friedman RA, Brackmann DE, Mills D. Auditory-nerve integrity after middle-fossa acoustic-tumor removal. *Otolaryngol Head Neck Surg* 1998 Dec; 119(6): 588 - 92
15. Roberson J, Senne A, Brackmann DE, Hitselberger WE, Saunders J. Direct cochlear nerve action potentials as an aid to hearing preservation in middle fossa acoustic neuroma resection. *Am J Otol* 1996 Jul; 17(4): 653 - 7
16. Kobayashi M, Tsunoda A, Komastuzaki A, Yamada I. Distance from acoustic neuroma to fundus and a postoperative facial palsy. *Laryngoscope* 2002 Jan; 112(1): 168 - 71
17. Arriaga MA, Luxford WM, Berliner KI. Facial nerve function following middle fossa and translabyrinthine acoustic tumor surgery: comparison. *Am J Otol* 1994 Sep;15(5): 620 - 4
18. Wackym PA, King WA, Poe DS, Meyer GA, Ojemann RG, Barker FG, Walsh PR, Staecker H. Adjunctive use of endoscope during acoustic neuroma surgery. *Laryngoscope* 1999 Aug; 109(8): 1193 - 201