

Histopathologic diagnosis of Pulmonary Actinomyces

Yavarace Vongsivavilas*

Saowanee Yenrudi**

Vongsivavilas Y, Yenrudi S. Histopathologic diagnosis of Pulmonary Actinomyces.
Chula Med J 2005 Jul; 49(7): 387 - 99

- Background** : *Pulmonary Actinomyces (PAM) is a relatively rare but treatable and curable disease, thus early diagnosis is mandatory. The key to correct diagnosis should be based on histologic examination.*
- Objective** : *To facilitate early diagnosis of PAM.*
- Settings** : *Chest Disease Institute, the largest national referral center for the treatment of heart and lung diseases in Thailand.*
- Research Design** : *Retrospective review between January 1, 1999 and December 31, 2003.*
- Materials and Methods** : *Two lobectomies and 7 transbronchial lung biopsies (TBLB) from 6 patients with PAM were available for microscopic examination. Tissue slides were stained with Hematoxylin & Eosin (H&E), Gram stain, modified Ziehl-Neelsen stain (Fite's stain) and Gomori's Methenamine Silver. Their medical records were also reviewed in search for clues that would lead the clinician to obtain tissue for pathologic examination.*

* Department of Pathology, Chest Disease Institute, Department of Medical Services, Ministry of Public Health Nonthaburi, Thailand

** Consulting Pathologist, Department of Pathology, Faculty of Medicine, Chulalongkorn University

Results : *Detection of 'sulfur granules' within inflammatory tissue established the diagnosis of PAM. After the correct diagnosis was made, all patients were given long term penicillin type of antibiotic with satisfactory result. No recurrence was observed in any cases during the follow-up period ranging from 1 to 36 months (mean, 11.25 months).*

Conclusions : *Prompt diagnosis of PAM requires an awareness of its natural history and a high level of suspicion on the part of the attending physician, thus lead them to perform FOB and TBLB. This diagnostic technique should be utilized whenever clinical and radiographic features fail to establish the diagnosis.*

Keywords : *Pulmonary Actinomycosis, Sulfur granules, Pneumonia, Lung infection, Lung pathology.*

Reprint request : Vongsivavilas Y. Department of Pathology, Chest Disease Institute,
Department of Medical Services, Ministry of Public Health Nonthaburi,
Thailand

Received for publication. April 20, 2005.

เขาวเรศ วงศ์ศิระวิลาส, เสาวณีย์ เย็นฤดี. การวินิจฉัยทางพยาธิวิทยาของโรคปอดอักเสบแอกติโนไมโคซิส. จุฬาลงกรณ์เวชสาร 2548 ก.ค; 49(7): 387 - 99

ความเป็นมาของการทำวิจัย : โรคปอดอักเสบแอกติโนไมโคซิส เป็นโรคที่พบได้น้อยมาก แต่ทว่าเป็นโรคที่รักษาให้หายขาดได้ ดังนั้นการวินิจฉัยให้ได้แต่เนิ่น ๆ ทันทีที่จึงเป็นสิ่งที่จะต้องกระทำ

วัตถุประสงค์ : เพื่อช่วยส่งเสริมให้ทำการวินิจฉัยโรคนี้ให้ได้แต่เนิ่น ๆ ทันทีที่

ประเภทโรงพยาบาล : สถาบันโรคทรวงอกเป็นศูนย์ตติยภูมิที่ให้การรักษาผู้ป่วยโรคหัวใจและโรคปอดที่ใหญ่ที่สุดในประเทศไทย

รูปแบบการวิจัย : การตรวจชันสูตรย้อนหลังตั้งแต่วันที่ 1 มกราคม 2542 ถึง 31 ธันวาคม 2546

สิ่งตรวจและวิธีการทำวิจัย : ตรวจวินิจฉัยชันเนื้อปอดด้วยกล้องจุลทรรศน์จากผู้ป่วย 6 ราย ซึ่งมีโรคปอดอักเสบแอกติโนไมโคซิส สไลด์ได้ถูกย้อมสี Hematoxylin & Eosin (H&E), Gram stain, modified Ziehl-Neelsen stain (Fite's stain) และ Gomeri's Methenamine Silver รวมทั้งได้ทบทวนเวชระเบียนผู้ป่วยเพื่อค้นหาแบะแสที่จะช่วยชักนำให้แพทย์ทำการตัดชิ้นเนื้อเพื่อส่งตรวจชันสูตรทางพยาธิวิทยา

ผลการศึกษา : การพบ 'sulfur granules' ในเนื้อเยื่ออักเสบ ยืนยันการวินิจฉัยโรคปอดอักเสบแอกติโนไมโคซิส หลังจากวินิจฉัยโรคถูกต้องแล้วผู้ป่วยได้รับการรักษาด้วยยาในกลุ่มของ Penicillin ในระยะยาวซึ่งก็ได้ผลเป็นอย่างดี ไม่มีผู้ป่วยรายใดเกิดโรคกลับซ้ำอีกในช่วงเวลาที่ได้ติดตามรักษาจาก 1 ถึง 36 เดือน (ค่าเฉลี่ย 11.25 เดือน)

สรุป : การวินิจฉัยโรคได้ทันเวลาที่ต้องอาศัยว่าแพทย์ผู้รักษานั้นมีความตื่นตัวรู้เรื่องเกี่ยวกับการดำเนินโรคและตั้งข้อสงสัย อันจะนำมาซึ่งการตรวจด้วยกล้องส่องหลอดลม และตัดชิ้นเนื้อชันสูตรทางพยาธิวิทยา เทคนิคการวินิจฉัยนี้ควรจะนำมาใช้เมื่อไรก็ตามที่ไม่สามารถให้การวินิจฉัยโรคจากลักษณะทาง คลินิก และภาพถ่ายทางรังสี

คำสำคัญ/ดัชนีเรื่อง : โรคปอดอักเสบแอกติโนไมโคซิส, ซัลเฟอร์แกรนูล, ปอดอักเสบ, โรคติดเชื้อในปอด, พยาธิสภาพในปอด

Pulmonary actinomycosis (PAM) is an indolent, slowly progressive infection of the lung caused by anaerobic bacteria, primarily of the genus *Actinomyces*,⁽¹⁾ Even though, it is a relatively rare disease, an accurate diagnosis is utmost important since it is a treatable and curable disease. It is highly responsive to long-term penicillin treatment but could be fatal if delayed treated or untreated.

Clinical, laboratory and radiographic findings are often non-specific. PAM can mimic a wide variety of pulmonary diseases⁽²⁻¹⁵⁾, and frequently resulting in long diagnostic delays.⁽¹⁶⁻¹⁹⁾ It is notoriously known as 'a master of disguise.'⁽²⁰⁾ In most of the reported cases, the correct diagnosis was made either from lobectomy or pneumonectomy specimens.^(3, 9, 16, 20)

Culture from sputum, bronchoalveolar lavage (BAL) or transbronchial lung biopsy (TBLB) is the most definitive means for organism identification, however, the discovery of *Actinomyces* species from such specimens does not establish the diagnosis of actinomycosis. For a long time, it has been well recognized that *Actinomyces* species is a normal inhabitant in the oropharynx, airways, and gastrointestinal tract.⁽²¹⁻²³⁾ The organisms can easily contaminate sputum, BAL, or TBLB, thus rendering cultures unreliable. *Actinomyces* species is a fastidious anaerobic organism and cultures of the lesions are positive in less than 60 % of cases due to overgrowth of coexisting bacteria, improper anaerobic culture or prior partial antibiotic administration.^(16, 17, 24) Culture is a time consuming procedure. Final microbiologic identification after obtaining the culture may delay specific treatment for 10 to 14 days.⁽²⁵⁾ Moreover, with the lack of suspicion by the attending physicians, tissue culture is oftentimes not done at all or

incorrectly done without special attention to the anaerobic requirement of the organisms.⁽³⁾

Given the above scenario, the key to the definitive diagnosis of PAM should be based on histopathologic examination. We decided to review the cases of PAM diagnosed by microscopic examination of tissue with the aim to facilitate early diagnosis. To be successful in this endeavor, the medical records were also reviewed in search for clues that would lead the clinician to obtain tissue for pathologic examination.

Materials and Methods

A retrospective review was conducted at Department of Pathology, Chest Disease Institute, Department of Medical Services, Ministry of Public Health, Nonthaburi 11000, Thailand. Chest Disease Institute is a 500-bed tertiary care center located in Bangkok Metropolitan. It is the largest national referral center for the treatment of heart and lung diseases in Thailand. It serves the nation's population of 65 million. Surgical pathology files of Department of Pathology were reviewed to identify the cases of PAM, diagnosed from the period of January 1, 1999 through December 31, 2003. One specimen of lobectomy from one patient was identified in the year 1999. In the year 2000, one lobectomy specimen and 7 TBLB specimens from 5 patients were diagnosed with PAM. There was no case of PAM detected from our surgical pathology file during the year 2001 to 2003. Each TBLB specimen was composed of 3 to 7 biopsies. An average of 8 to 10 representative sections was obtained from each lobectomy specimen.

All surgical specimens were processed in tissue processor and embedded in paraffin blocks.

Multiple serial sections of each TBLB and 2-step sections of each block of lobectomy specimen were routinely prepared for hematoxylin and eosin (H&E) stain. Special histochemical stain including Brown-Hopps method of Gram stain, Gomori's methenamine silver (GMS) stain, and modified Ziehl Neelsen technique for acid fast bacilli (Fite stain) were done in all cases of PAM at the time of first diagnosis. All H&E and special stained slides of the 6 patients identified were retrieved for a review under a bright light microscopy. In addition, polarized light was used to examine all H&E slides. The criteria for the diagnosis of PAM included the presence of typical 'sulfur granules' and inflammatory reaction. Excluded were the cases showing inflammatory reaction without 'sulfur granules,' or cases showing organism colonization without inflammation.

This study included 6 patients, 5 men and one woman with the age ranged from 40 to 84 years. Their medical records were also retrieved for a review with respect to demographic data, presenting symptoms and signs, radiographic features, fiberoptic bronchoscopic (FOB) findings, treatment and follow-up information.

Results

The review of all retrieved slides confirmed the original surgical pathologic diagnosis of PAM in all cases. All 7 TBLB specimens showed typical 'sulfur granules,' necrotic debris, inflammation and granulation tissue. TBLB from case 2 and case 5 also contained vegetable fibers. Case 1 underwent FOB but TBLB was not done due to severe cough. The diagnosis of PAM in case 1 was first made from the left upper lobe (LUL) lobectomy specimen when he

suffered the second episode of massive hemoptysis that required emergency surgery. Case 4 had TBLB done twice at the left lower lobe (LLL) and the correct diagnosis was made on both specimens. During the treatment with penicillin intravenous infusion, he had a massive hemoptysis. Therefore, emergency LLL lobectomy was carried out as a life-saving surgery. Each lobectomy specimen showed markedly dilated bronchiole containing 'sulfur granules' and necrotic debris. The dilated bronchiole was surrounded with granulation tissue and organizing pneumonitis. The typical 'sulfur granules' were readily visualized within inflammatory exudate on all H&E stained slides, but Gram stain and GMS stain provided better demonstration of the filamentous organisms, (Figure 1 and Figure 2). Fite stain was negative in all cases. No granuloma was seen in any tissue sections.

Each patient had at least 3 sputum smears and cultures done for acid-fast bacilli and the results were negative. Sputum culture of case 1 showed *Klebsiella pneumonia* on 2 occasions. Case 6 had blood drawn for aspergillus antigen, antibody and melioid titer and the results were negative. Latex agglutination (galactomannan) and immunodiffusion tests were used for the detection of aspergillus antigen and antibody respectively. The detailed clinical information is shown in Table 1 and 2. All patients received antibiotic (including ofloxacin, ciprofloxacin, amoxicillin, penicillin, or anti-tuberculous drugs) treatment for few days to weeks prior to the histopathologic diagnosis of PAM. Information related to treatment and follow-up is shown in Table 3. The comparison of clinical manifestation between the previous study of Dujneungkunakorn et al and this study is shown in Table 4.

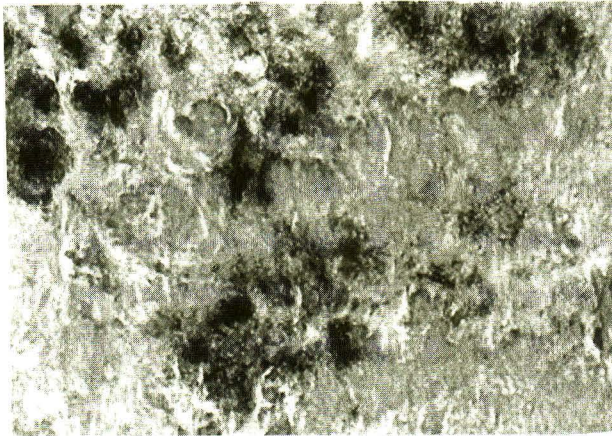


Figure 1. A transbronchial biopsy shows several clusters of basophilic 'sulfur granules' of actinomycotic colonies, (H & E stain X 400).



Figure 2. A higher power view of the transbronchial biopsy shows the characteristic 'sulfur granules' with darker amorphous colonies at the center and peripheral radiated arrangement of filamentous organisms, (GMS stain X 600).

Discussion

Actinomycosis was initially recognized as the disease in cattle. LeBlanc made the first description of this disease in cattle in 1826. Von Langenbeck first discovered this illness in human in 1845, but it was not published until almost 40 years later.^(24,27) In 1876, Bollinger described cattle with an indurated mass containing yellow granules in the jaw, so called 'lumpy jaw.' A year later, Harz had studied the sulfur granules and named the bacillus he found *Actinomyces bovis*, or 'ray fungus of cattle.'^(24,27) In 1878, Israel detected the typical 'sulfur granules' from specimen at human autopsy and 13 years later, they were able to culture this organism from human lesional material. Therefore, the organism was named *Actinomyces israelii* in honor of the early investigative workers.^(24,27) Although other *Actinomyces* species have subsequently been seen in human disease, *Actinomyces bovis* has never been

isolated from any human lesional material.⁽²⁴⁾

PAM is a relatively rare disease, most commonly caused by *Actinomyces israelii*. This organism has been confirmed to be endogenous in human and it is not found in soil or on plants.⁽²⁸⁾ The variable clinical manifestation and relative rarity of PAM cause great diagnostic difficulty, yet its sensitivity to specific antibiotic therapy makes early diagnosis mandatory. According to several reports, none or only few of the patients were diagnosed at hospital admission and the majority of them were diagnosed either from surgical lung resection or autopsy materials.^(3-6,9,11,16,20) In the largest series of Actinomycosis reported by Brown et al indicated that the attending physicians made the correct diagnosis in only 19 of 181 cases, (10.5 %) with a diagnostic delay of one month to 2 years in 90 % of the cases.⁽¹⁷⁾

Table 1. Clinical data of the 6 patients with pulmonary actinomycosis.

Case	Age/ Sex	Occupation	Presenting Symptoms & Signs	Underlying Conditions	Duration before Dx	Clinical Dx	Specimen for Pathologic Dx
1.	43/M	Government employee	Hemoptysis X 3 months Massive X 2 weeks Anemia, weight loss	DM, HT	7 months	Tuberculosis Lung abscess, cancer Pneumonia	Emergency LUL lobectomy at second episode of massive hemoptysis
2.	84/M	Retiree	Aspiration X 1 month Dyspnea, cough	COPD	1.5 months	Lung cancer	TBLB X 2 at RLL Retained FB
3.	40/M	Laborer	Chronic hemoptysis Weight loss X 1 year Fever X 1 week Chest pain X 3 days Mild anemia	Smoking	8 months	Tuberculosis Recurrent Pneumonia Lung cancer	TBLB at RUL FNA was negative for malignant cell
4.	57/M	Farmer	Fever, Anemia Hemoptysis X 1 month Massive hemoptysis	Smoking Drinking	1.5 months	Tuberculosis Lung cancer Pneumonia	TBLB X 2 at LLL Emergency LLL lobectomy
5.	65/F	Retiree	Cough X 1 year Dyspnea & Malaise X 1 month	DM	14 months	Bronchiectasis Retained Foreign bodies	TBLB at RLL Retained FB
6.	45/M	Laborer	Cough X 4 months Weight loss, Anemia	Drinking Smoking	4.5 months	Aspergilloma Pneumonia	TBLB at LUL

Abbreviations: M = Male, F = Female, DM = Diabetes Mellitus, HT = Hypertension, RUL = Right upper lobe, RLL = Right lower lobe, LUL = Left upper lobe, LLL = Left lower lobe, TBLB = Transbronchial lung biopsy, Dx = Diagnosis, FB = Foreign bodies

Table 2. Radiographic and Bronchoscopic findings of the 6 patients with pulmonary actinomycosis.

Case	Chest X-rays	HRCT Scan of the chest	FOB
1.	Cavitated mass at LUL	A 2X3 cm cavitary lesion with patchy infiltrates at LUL	Swelling of LUL bronchial mucosa, TBLB was not done due to severe cough during the procedure
2.	Patchy infiltrates at RML, RLL	Right basal fibrosis, improved after 1 month of antibiotic treatment	Necrotic tumor occluding common basal RLL bronchus. FOB 1 month after antibiotic treatment, only yellow plaque was seen.
3.	Patchy infiltrates at RUL	A 3X5 cm RUL mass with involvement of superior segment of RLL and right paratracheal node Repeat HRCT 8 months later: improved RUL lesion	Mass at RB2a
4.	Consolidation at LLL, slightly improved after antibiotic treatment	A 2X3 cm mass at superior segment of LLL	First FOB: no record available Second FOB: Active bleeding at LB6
5.	Bronchiectasis of RML and lingular segment	Not available	FB was seen at RLL bronchus. Upon removal of FB, yellow discharge came out.
6.	Mass at LUL, patchy infiltration at RML and lingular segment. Lesion was completely clear up after 8 months of antibiotic treatment	A 5X9 cm Abscess at LUL	Necrotic mass at LB1&2 with minimal bleeding

Abbreviations: HRCT = High resolution computed tomography, FOB = Fiberoptic bronchoscopy, RUL = Right upper lobe, RML = Right middle lobe,

RLL = Right lower lobe, LUL = Left upper lobe, LLL = Left lower lobe, cm = centimeter, FB = Foreign bodies.

Table 3. Treatment and follow-up information.

Case	Before Dx of PAM	After the Dx of PAM
1.	Ofloxacin X 2 weeks Ciprofloxacin X 2 weeks	Emergency LUL lobectomy, Augmentin X 2 weeks then Cloxacillin X 1 month A&W at 9.5 months after surgery
2.	Ofloxacin X 10 days	Augmentin X 3 months A&W at 3 months after Dx
3.	Ofloxacin X 2 weeks	Pen GS X 1 month, developed allergic rash, then switched to Doxycycline X 10 days Amoxicillin plus Augmentin X 9 months, Additional Loratidine was also given Follow-up HRCT X 2 times: Improved Repeated CXR: fibrotic scar. A&W at 3 years after Dx, Last visit for possible GI bleeding, then lost to follow-up
4.	Anti-tuberculous drugs X 1 month	Pen GS X 1.5 months, then massive hemoptysis that required emergency LLL lobectomy Pen VK X 6 months after surgery A&W at 10 months after surgery
5.	Ofloxacin X 2 weeks Amoxicillin X 10 days	Pen VK X 1 month and lost to follow up
6.	Pen GS X 4 days	Pen VK X 6 months A&W at 8 months after Dx

Abbreviations: Pen GS = Penicillin G sodium for intravenous use, Pen VK = Oral Penicillin potassium,
A&W = Alive and well, Dx = Diagnosis, PAM = Pulmonary Actinomyces

Table 4. Comparison of clinical manifestation between the previous study of Dujneungkunakorn et al ⁽²⁶⁾ and this study.

Clinical data	Previous study	This study	Combined studies
Cough	16/16 (100 %)	6/6 (100 %)	22/22 (100 %)
Hemoptysis	10/16 (62.5 %)	3/6 (50 %)	13/22 (59.09 %)
Fever	5/16 (31.25 %)	2/6 (33.33 %)	7/22 (31.82 %)
Weight loss	4/16 (25 %)	2/6 (33.33 %)	6/22 (27.27 %)
Dyspnea	0	2/6 (33.33 %)	2/22 (9.09 %)
Malaise	0	1/6 (16.67 %)	1/22 (4.55 %)
Chest pain	0	1/6 (16.67 %)	1/22 (4.55 %)
Anemia	0	4/6 (66.67 %)	4/22 (18.18 %)

Table 4. Continuous.

Clinical data	Previous study	This study	Combined studies
Underlying conditions			
Diabetes mellitus	6/16 (37.50 %)	2/6 (33.33 %)	8/22 (36.36 %)
History of Tuberculosis	1/16 (6.25 %)	0	1/22 (4.55 %)
Bronchogenic carcinoma	1/16 (6.25 %)	0	1/22 (4.55 %)
Hypertension	0	1/6 (16.67 %)	1/22 (4.55 %)
COPD	0	1/6 (16.67 %)	1/22 (4.55 %)
Radiographic findings			
Mass lesion	6/16 (37.50 %)	2/6 (33.33 %)	8/22 (36.36 %)
Cavitary lesion	2/16 (12.50 %)	1/6 (16.67 %)	3/22 (13.64 %)
Abscess	1/16 (6.25 %)	1/6 (16.67 %)	2/22 (9.09 %)
Empyema	1/16 (6.25 %)	0	1/22 (4.55 %)
Others	6/16 (37.50 %)	2/6 (33.33 %)	8/22 (36.36 %)
FOB findings			
Endobronchial mass	9/16 (56.25 %)	3/6 (50 %)	12/22 (54.54 %)
Yellow discharge	2/16 (12.50 %)	1/6 (16.67 %)	3/22 (13.64 %)
Others	5/16 (31.25 %)	2/6 (33.33 %)	7/22 (31.82 %)

Abbreviations: COPD = Chronic obstructive pulmonary disease, FOB = Fiberoptic bronchoscopy

It has also been well recognized that delayed diagnosis is associated with increased morbidity and mortality. Tastepe et al reported 7 cases of undiagnosed pulmonary infiltrates who underwent resective surgery, 5 lobectomies and 2 wedge resections.⁽¹¹⁾ There were 3 major complications, acute renal failure, empyema, and persistent air leakage in 3 out of 7 cases after the operations. One patient in their report had bronchopulmonary fistula and died of uncontrolled infection and sepsis. In our study, case 1 and 4 received antibiotics before and after emergency lobectomies and both of them had uneventful post-operative course. We believe antibiotic administration helps control infection, especially in case 4 when TBLB established the diagnosis prior to the operation.

TBLB is a well-known technique utilized in the diagnosis of a variety of infectious, neoplastic and other infiltrative lung diseases. It can provide adequate material for both culture and histopathologic examination. In case of PAM, a positive culture may represent saprophytic colonization of the airways.⁽²²⁾ Therefore, culture result should be interpreted in conjunction with histologic examination. In general, the problem with low culture yield may be overcome by proper specimen handling with regard to anaerobic need of the organisms. However, the situation in Thailand is different, the laboratory facilities for anaerobic culture are available in only few institutions, thus makes the culture method almost impossible. Finally, what we have left is histologic examination of TBLB.

While, the detection of 'sulfur granules' in tissue confirms the presence of *Actinomyces* species; inflammation, necrotic debris and granulation tissue are indicative of the battlefield in true infection. 'Sulfur granules' are rarely found in Nocardiosis. *Nocardia asteroides*, the most common *Nocardia* species to cause human pulmonary disease does not usually produce granules or form sinus tract; however, *Nocardia brasiliensis* may do so but to a lesser degree than *Actinomyces* organisms.⁽²⁹⁾ *Nocardia* species is usually acid-fast, although, most of them exhibit this property only with weak decolorizing agents.⁽²⁹⁾ *Actinomyces* species is non-acid-fast, thus give negative result with Fite stain. Several varieties of bacteria may mimic 'sulfur granules' in tissue, including *S. aureus*, *streptococcus* species, *E. coli*, *Pseudomonas* species, *B. proteus*, and *Streptomyces*. However, these organisms do not produce filaments and can easily be distinguished from *Actinomyces* organisms on Gram stain.

The previous study of 16 cases of PAM at this institution indicated that the correct diagnosis was made from TBLB in 10 cases (62.5 %) and fine needle aspiration (FNA) in one case (6.25 %).⁽²⁶⁾ So far there have been only few reports of PAM diagnosed from TBLB.^(3,22,30,31) It has probably been taken for granted. Ariel et al reported 5 cases of endobronchial actinomycosis simulating lung cancer, diagnosed from bronchial biopsy.⁽³²⁾ In our study, PAM was first diagnosed on TBLB in 5 out of 6 cases. The remaining case was diagnosed on a lobectomy specimen because TBLB was not done. Although, PAM was not suspected in any of these patients prior to TBLB, this procedure was done because they did not respond to antibiotic treatment and their clinical

and radiographic features failed to establish the diagnosis. The duration before diagnosis ranged from 1.5 to 14 months (mean, 6 months). Following long-term penicillin therapy, there was no clinical evidence of recurrence in any patients after the follow-up period ranging from 1 to 36 months (mean, 11.25 months). The success of treatment also served to confirm the correct diagnosis.

Detection of 'sulfur granules' requires an accurate morphologic recognition of filamentous organisms in the basophilic granules. The characteristic 'sulfur granule' ranges from 30 to 3000 mm in diameter and may be visible on gross examination if a hand lens is used.⁽³³⁾ 'Sulfur granules' form when *Actinomyces* organisms aggregate in clusters by a polysaccharide substance produced in response to tissue inflammation.⁽²⁵⁾ Inflammation and necrotic debris seen in TBLB are morphologic evidence of the warfare in true infection. TBLB is safe, simple, and accurate, and allows early diagnosis of PAM. It is the least invasive method to obtain diagnostic tissue when compare to surgical (open or video-assisted) lung biopsy, lobectomy or pneumonectomy specimen.

Same as many previous reports, this study indicated a male predominance with a male to female ratio of 5 to 1. It also demonstrated a variety of clinical presentations including fever, cough, hemoptysis, dyspnea, anemia and weight loss. The other associated conditions included history of aspiration, diabetes mellitus (DM), excessive smoking, drinking, and COPD. Most cases of PAM, the organisms gain entrance by aspiration of oral contents and produce pulmonary infection in the dependent segments of the lung.⁽¹⁾ Therefore, PAM should be suspected when susceptible patient

presents with history of aspiration. DM, alcoholism, and low immunity are conditions that impair host defense mechanism, thus affecting extent and eradication of this infection.

Pulmonary lesions suggestive of PAM may cross fissures or pleura, may involve mediastinum, contiguous bone or chest wall or may be associated with a sinus tract. In this study, mass and cavitory lesions were the most common radiographic findings. Although, the presenting symptoms are oftentimes non-specific but when taking radiographic features in consideration, PAM should be suspected. FOB with TBLB should be performed whenever clinical and radiographic features fail to establish the diagnosis.

In conclusion, early diagnosis of PAM requires an awareness of its natural history and a high level of suspicion on the part of the attending physician, thus lead them to perform FOB and TBLB for definitive diagnosis.

References

1. Hasleton PS. Pulmonary bacterial infection. In Hasleton PS, ed. *Spencer's Pathology of the Lung*. 5thed. New York: McGraw-Hill, St. Louis: 1996: 234-7
2. Conant EF, Wechsler RJ. Actinomycosis and nocardiosis of the lung. *J Thorac Imaging* 1992 Sep; 7(4): 75-84
3. Hsieh MJ, Liu HP, Chang JP, Chang CH. Thoracic actinomycosis. *Chest* 1993 Aug; 104(2): 366-70
4. Lau K. Endobronchial actinomycosis mimicking pulmonary neoplasm. *Thorax* 1992 Aug; 47(8): 664-5
5. Hsieh MJ, Shieh WB, Chen KS, Yu TJ, Kuo HP, Tsai YH. Pulmonary actinomycosis appearing as a "ball-in-hole" on chest radiography and bronchoscopy. *Thorax* 1996 Feb; 51(2): 221-2
6. Parker JS, deBoisblanc BP. Case report: actinomycosis: multinodular pulmonary involvement. *Am J Med Sci* 1994 Jun; 307(6): 418-9
7. Bentley ER, Ostransky D. Unusual manifestations of thoracic actinomycosis. *J Am Osteopath Assoc* 1994 Mar; 94(3): 249-53
8. Dontfraid F, Ramphal R. Bilateral pulmonary infiltrates in association with disseminated actinomycosis. *Clin Infect Dis* 1994 Jul; 19(1): 143-5
9. Sato T, Takada N, Dobashi Y, Suzuki M, Ouchi M, Abe Y. Pulmonary actinomycosis resembling an anterior mediastinal tumor. *Nihon Kyobu Shikkan Gakkai Zasshi* 1997 Aug; 35(8): 888-93
10. Hagiwara S, Ishii Y, Kitamura S. Clinical and radiological study of pulmonary actinomycosis. *Nihon Koryuki Gakkai Zasshi* 1998 Dec; 36(12): 999-1005
11. Tastede AI, Ulasan NG, Liman ST, Demircan S, Uzar A. Thoracic actinomycosis. *Eur J Cardiothorac Surg*. 1998 Dec; 14(6): 578-83
12. Baik JJ, Lee GL, Yoo CG, Han SK, Shin YS, Kim YW. Pulmonary actinomycosis in Korea. *Respirology* 1999 Mar; 4(1): 31-5
13. Tolentino A, Ahkee S, Ramirez J. Pancoast's syndrome secondary to thoracic actinomycosis. *J Ky Med Assoc* 1996 Nov; 94(11): 500-2
14. Ariel I, Breuer R, Kamal NS, Ben-Dov I, Mogel P, Rosenmann E. Endobronchial Actinomycosis Simulating Bronchogenic carcinoma:

- Diagnosed by Bronchial Biopsy. *Chest* 1991 Feb; 99(2): 493-5
15. Balikian JP, Cheng TH, Costello P, Herman PG. Pulmonary actinomycosis: A report of three cases. *Radiology* 1978 Sep; 128(3): 613-6
16. Weese WC, Smith IM. A study of 57 cases of actinomycosis over a 36-year period. *Arch Intern Med* 1975 Dec; 135(12): 1562-8
17. Brown JR. Human actinomycosis. A study of 181 subjects. *Hum Pathol* 1973; 1: 319-30
18. McQuarrie DG, Hall WH. Actinomycosis of the lung and chest walls. *Surgery* 1968 Nov; 64(5): 905-11
19. Prather JR, Eastridge CE, Hughes FA Jr, Mc Caughan JJ Jr. Actinomycosis of the thorax. Diagnosis and treatment. *Ann Thorac Surg* 1970 Apr; 9(4): 307-12
20. Shannon HM, Wightman AJ, Carey FA. Pulmonary actinomycosis -a master of disguise. *J Infect* 1995 Sep; 31(2): 165-9
21. Lord FT. The etiology of actinomycosis: The presence of actinomyces in the contents of carious teeth and the tonsillar crypts of patients without actinomycosis. *JAMA* 1910; 55: 1261-71
22. Kay EG. Actinomycosis in chronic bronchopulmonary infections. *Am Rev Tuberc* 1948; 57; 322-9
23. Brogden JC. Actinomycosis of the gastrointestinal tract: A study of fourteen cases. *J Lab Clin Med* 1922; 8: 180-9
24. Bennhoff DF. Actinomycosis: diagnostic and therapeutic considerations and a review of 32 cases. *Laryngoscope* 1984 Sep; 94(9): 1198-217
25. Pollock PG, Meyers DS, Frable WJ, Valicenti JF Jr, Koontz FP, Beavert CS. Rapid diagnosis of actinomycosis by thin-needle aspiration biopsy. *AJCP* 1978 Jul; 70(1): 27-30
26. Dujneungkunakom T, Riantawan P, Tungsagunwattana S. Pulmonary actinomycosis: a study of 16 cases from Central Chest Hospital. *J Med Assoc Thai* 1999 Jun; 82(6): 531-5
27. Rippon J W. *Medical Mycology*. W.B. Saunders, Philadelphia, PA, 1974: 13-28
28. Delacretz R, Grigoriu D, Ducei G. *Medical Mycology (Atlas)*. Hans Huber, 1976: 149-51
29. Fraser RS, Muller NL, Colman N, Pare' PD. Fungi and Actinomyces. In Fraser and Pare's *Diagnosis of Diseases of the Chest*, 4th Edition. WB Saunders Company, Philadelphia, Pennsylvania 1999: 875-979
30. Morita S, Honda Y, Fujishima T, Hirasawa M, Tanaka H, Satoh M, Abe S. A case of pulmonary actinomycosis; histologic diagnosis obtained from transbronchial lung biopsy specimen. *Nihon Kyobu Shikkan Gakki Zasshi* 1994 Jul; 32(7): 676-9
31. Yew WW, Wong PC, Lee J, Fung SL, Wong CF, Chan CY. Report of eight cases of pulmonary actinomycosis and their treatment with imipenem-cilastatin. *Monaldi Arch Chest Dis* 1999 Apr; 54(2): 126-9
32. Ariel H, Brewer R, Kamal S, Bendov I, Mogle P, Rosenmann E. Endobronchial actinomycosis simulating bronchogenic carcinoma: Diagnosis by bronchial biopsy, *Chest* 1991; 99: 493-5
33. Hotchi M, Schwarz J. Characterization of actinomycotic granules by architecture and staining methods. *Arch Pathol* 1972 May; 93(5): 392-400