

## Result and safety of orchiectomy under spermatic cord block

Meechai Saelim\*

Julin Opanurak\*

**Saelim M, Opanurak J. Result and safety of orchiectomy under spermatic cord block.**  
**Chula Med J 2005 Jul; 49(7): 369 - 75**

**Objective** : *To study for the result, safety, success rate and complication of spermatic cord block to operate orchiectomy.*

**Research design** : *Prospective and descriptive study.*

**Setting** : *Division of Urology, Department of Surgery, Faculty of Medicine, Chulalongkorn University.*

**Materials and Methods** : *From December 2002 to October 2004, 19 men with prostatic cancer who were no indication for radical prostatectomy and required hormonal ablation treatment. In every patient, we performed orchiectomy under spermatic cord block by injection of 8-10 ml 0.25% bupivacaine hydrochloride to each spermatic cord and infiltrate at skin incision site.*

*During the operation we monitored blood pressure, pulse rate, and record abnormal symptoms such as abdominal pain, nausea, vomiting and pain score of the procedure was assessed at the end of the operation.*

**Result** : *Of the 19 patients, 18 had successful operation under spermatic cord block. One patient needed to be converted to general anesthesia because of severe pain during the operation; 1 patient had transient bradycardia but no hypotension; 2 patients had tachycardia (one of the two who were converted to general anesthesia; another had no symptom). 7 patients (36.84 %) had mild pain, 10 patients (52.63 %) had moderate pain and 2 patients (10.53 %) had severe pain.*

*None of the patients had any complication related to local anesthetic drugs; and there was no major complication detected in the series.*

**Conclusion** : *Spermatic cord block is successful in most patients, safe for orchiectomy and not suitable for anxiety disorder and obese patient. It can be the alternative method of anesthesia for the selected patient.*

**Keywords** : *Orchiectomy, Spermatic cord block, Local infiltration.*

Reprint request : Saelim M. Department of Surgery, Faculty of Medicine, Chulalongkorn University, Bangkok 10330, Thailand.

Received for publication. March 22, 2005.

**มีชัย แซ่ลิ้ม, จุลินทร์ โอภาณุรักษ์. ผลการผ่าตัดอัณฑะ (orchietomy) ด้วยการฉีดยาเฉพาะที่ที่ spermatic cord. จุฬาลงกรณ์เวชสาร 2548 ก.ค; 49(7): 369 - 75**

- เหตุผลในการทำวิจัย** : การผ่าตัดอัณฑะ (orchietomy) เป็นการผ่าตัดเล็ก ใช้เวลาผ่าตัดไม่นาน ซึ่งปกติระดับความรู้สึกด้วยวิธีดมยาสลบหรือฉีดยาชาที่ไขสันหลัง การระงับความรู้สึกด้วยวิธีฉีดยาเฉพาะที่ที่ spermatic cord ยังไม่เป็นที่รู้จักแพร่หลาย และยังขาดข้อมูลผลของการผ่าตัด
- วัตถุประสงค์** : เพื่อศึกษาผลการผ่าตัด, ความปลอดภัย, ความสำเร็จ และภาวะแทรกซ้อน ในการผ่าตัดอัณฑะ (orchietomy) ด้วยวิธีฉีดยาเฉพาะที่ที่ spermatic cord
- รูปแบบการวิจัย** : การศึกษาแบบพรรณนา
- สถานที่ศึกษา** : ภาควิชาศัลยศาสตร์ คณะแพทยศาสตร์ จุฬาลงกรณ์มหาวิทยาลัย
- ตัวอย่างและวิธีการศึกษา** : ผู้ป่วยจำนวน 19 ราย ที่เป็นมะเร็งต่อมลูกหมากที่ต้องรักษาด้วยวิธีการผ่าตัดอัณฑะ (orchietomy) ได้รับการผ่าตัดโดยการฉีดยาเฉพาะที่ที่ spermatic cord ด้วย 0.25 % bupivacaine hydrochloride 8 - 10 มิลลิลิตร และบริเวณถุงอัณฑะที่จะผ่าตัด
- ผลการศึกษา** : ผู้ป่วยจำนวน 19 ราย ผ่าตัดสำเร็จด้วยวิธีการฉีดยาเฉพาะที่ที่ spermatic cord 18 ราย, 1 ราย มีอาการปวดมาก จึงต้องเปลี่ยนวิธีระงับความรู้สึกด้วยการดมยาสลบ, ผู้ป่วย 1 ราย ชีพจรเต้นช้า (< 60 ครั้ง/นาที), 2 ราย ชีพจรเต้นเร็ว (> 100 ครั้ง/นาที) (1 ใน 2 รายนั้นต้องดมยาสลบผ่าตัด) ไม่มีผู้ป่วยรายใดเลยที่มีอาการวิงเวียนศีรษะ, คลื่นไส้อาเจียน
- ผู้ป่วย 7 ราย (36.84 %) ปวดเล็กน้อย (pain score อยู่ในช่วง 0 - 3/10), ผู้ป่วย 10 ราย (52.63 %) ปวดปานกลาง (pain score อยู่ในช่วง 4-6/10), ผู้ป่วย 2 ราย (10.53 %) ปวดรุนแรง (pain score อยู่ในช่วง 7-10/10)
- ไม่มีผู้ป่วยรายใดเลยที่มีภาวะแทรกซ้อนจากการฉีดยาเฉพาะที่
- สรุป** : การฉีดยาเฉพาะที่ที่ spermatic cord เพื่อผ่าตัดอัณฑะ (orchietomy) นั้นปลอดภัย สามารถผ่าตัดได้สำเร็จเกือบทุกราย ไม่เหมาะกับผู้ป่วยที่มีความวิตกกังวลสูง และรูปร่างอ้วน เป็นทางเลือกหนึ่งนอกเหนือจากวิธีให้การระงับความรู้สึกอื่น
- คำสำคัญ** : การผ่าตัดอัณฑะ, การฉีดยาเฉพาะที่, การระงับความรู้สึกที่ spermatic cord

Orchiectomy is a minor procedure, either done under spinal block or general anesthesia. Some surgeons, however, prefer to do it with spermatic cord block; so far there are no data available on its safety, efficacy nor technique description have been reported. Spermatic cord block is not widely recognized a technique for anesthesia in patient receiving scrotal operation.

Keitn W Kaye<sup>(1)</sup>, in 1982 reported 35 patients who received local anesthesia sufficient for vasectomy, hydrocelectomy, spermatocelectomy or orchiectomy: 10-12 ml 0.5% bupivacaine hydrochloride injected through the spermatic cord, approximately 1 cm below and medial to the pubic tubercle and infiltrated anesthesia at the overlying skin.

Eugene F. Fuchs<sup>(2)</sup>, in 1982 reported 344 cases of scrotal procedure with excellent result, achieved with spermatic cord block by injection of 0.5% bupivacaine hydrochloride just superior to the tubercle.

## Materials and Methods

Of 19 patients from December 2002 – October 2004 who were diagnosed prostatic cancer. They were nonlocalized prostatic cancer or physical status not suitable for radical prostatectomy surgery.

All subjects were operated and evaluated postoperative by one surgeon.

After the procedure has been described, the patients were offered the choice of having the operation done under spermatic cord anesthesia as an alternative either to general or spinal anesthesia.

We excluded patients who were allergic to bupivacaine hydrochloride, or having severe

hypertension, recent MI, unstable angina, uncorrected bleeding disorder, paraplegia and neuro-sensory deficit .

During the pre-operation we explained the patient the procedure and provided anesthesia only on the scrotal content and scrotal skin at the incision site; he would feel some pain initially during the injection of anesthetic agent, and he might have some abdominal discomfort during the cord manipulation, and postoperatively he could ambulate or immediately take some food.

The patient was not allowed to take anything by mouth after midnight before the procedure.

Oral administration of lorazepam 1 mg at night and 1/2 -1 hr before the operation is used as the only preoperative sedation.

Every patient was given an intravenous line (heparin lock medicut) and an anesthetist was on stand-by to give anesthesia if spermatic cord block did not work.

The anesthetic agent is 0.25 % bupivacaine hydrochloride was selected, as it has long pharmaceutical action.

The patient<sup>(1-3)</sup> was in supine position. The pubic tubercle is palpated; the cord was trapped between the index and middle fingers of the surgeon; 1 cm below and medial to the tubercle was the injected point, infiltrate at skin and pass the needle vertically down to the anterior aspect of the pubic bone. In it course the needle, thus passes through the spermatic cord, 8 -10 ml bupivacaine hydrochloride is injected through the cord at slightly different angle and the needle entering the blood vessel be aware of.

After the spermatic cord was blocked the skin at the incision site was infiltrated with 3-5 ml

bupivacaine hydrochloride, 3 -5 minutes before the start of the operation so that drug became effective.

Orchiectomy was performed in the midline raphae incision with epididymis – sparing fashion to create a round structure mimic a small testis for cosmetic result. The wound was closed with 3-0 CCG and no drain was given.

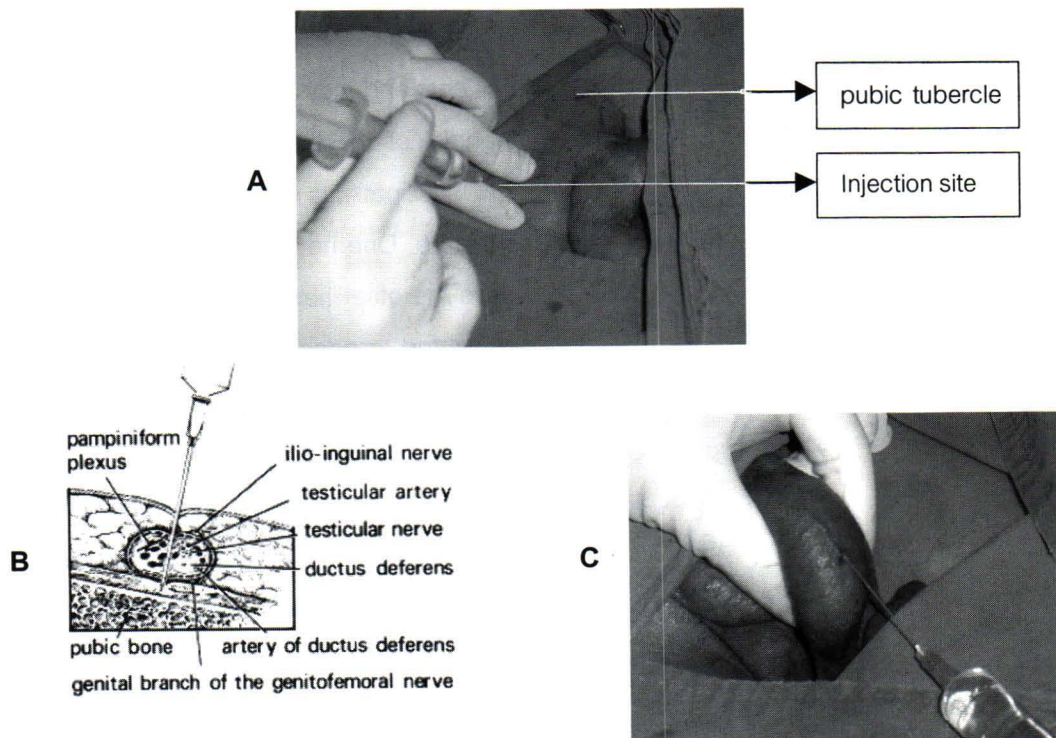
During the operation, the patient was monitored and blood pressure, pulse rate and abnormal symptom were recorded; when surgery finished the patient's pain score of the procedure (including pain of anesthetic injection) was assessed immediately by using visual analog pain scale (0 = no pain, 5 = moderate pain and 10 = worst possible pain)

At 1-week follow-up, the patient's symptom and wound were evaluated again.

### Result

Of the 19 patients age 59 – 93 yr (mean = 72.11 yr),operative time 25 – 70 min (mean 41.84 min), amount of bupivacaine hydrochloride 12 – 34 ml (mean = 23.63 ml) orchiectomy under spermatic cord block were successful in 18 – 19 (94.74 %). One patient failed because he had so severe pain that needed to be converted to general anesthesia.

One patient had bradycardia (pulse rate = 54/ min, 5 min in duration); 2 patients had tachycardia (pulse rate = 124/min, 102/min). None of patients had hypotension, nausea or vomiting. No complication related to the anesthesia nor the procedure was seen. Most of the patients felt little pain especially when monopolar electrocautery was used to cut the tissue or stop bleeding.



**Figure 1.** A) trapping spermatic cord with 2 fingers; injection at the site 1 cm below and medial to the pubic tubercle. B) transverse section of spermatic cord at injection site; C) scrotal skin infiltration at incision site.

Post-operatively, all of the patients ambulated immediately; 17 patients (89.47 %) rated their visual analog pain scale between 0–6; 2 patients (10.53 %) numbered their visual analog pain 10 (1 of them converted from local to general anesthesia).

When classify to mild (pain score 0-3/10), moderate (pain score 4-6/10), and severe pain (pain score 7-10/10).

7 patients (36.84 %) was in mild pain group, 10 patients (52.63 %) had moderate pain, and severe pain in 2 patients (10.53 %).

At 1-week follow-up, 1 patient suffer from surgical wound infection which later he improved by wound dressing and oral antibiotic treatment; 1 patient had scrotal hematoma which improved with time and conservative treatment.

**Table 1.** The number of pain scale assessed at the end of the procedure.

Visual analog pain score	Number of patient
0	4 (21.05 %)
1	2 (10.53 %)
2	0
3	1 (5.26 %)
4	4 (21.05 %)
5	5 (26.32 %)
6	1 (5.26 %)
7	0
8	0
9	0
10	2 (10.53 %)

0 = no pain; 5 = moderate pain; and  
10 = worst possible pain.

## Discussion

The technique of spermatic cord block is base on the anatomy:<sup>(4)</sup> as the cord emerges from the external ring, it passes over the pubic tubercle and the shifted medially to the scrotum. In this region it is closely associated with the ilioinguinal nerve and the genital branch of genitofemoral nerve, which supply the testis and its covering, the epididymis and the vas deferens but not the scrotal skin. The scrotal skin receives sensory supply from the pudendal nerve and the perineal branch of the posterior cutaneous nerve of the thigh, therefore it needs to be infiltrated with the anesthetic agent separately from spermatic cord block.

Good result of spermatic cord block facilitates a successful orchiectomy. No complication related to anesthesia was detected in the series. The advantage of spermatic cord block is its short time of recover, low cost and may be performed in patient who has high risk of anesthesia.

2 patients numbered their visual analog pain scale 10. One he had underlying anxiety disorder, while the other had severe pain that needed to be converted to general anesthesia which might have caused by his obesity (BW 79.5 kg, HT 165 cm, BMI 29.20 kg/m<sup>2</sup>; mean BW = 52.46 kg; patients who had success operation whose BW was in the range of 39 – 64 kg). Obesity made it difficult to palpate the cord and inject anesthetic agent to the correct point, so the spermatic cord block did not work well.

One patient had bradycardia (pulse rate = 54/min) which might due to his vagovagal reflex when the cord was under traction; however he developed no other symptom or hypotension.

Several patients still felt pain after spermatic cord block was done, and when the monopolar electrocautery was used, but during the sharp dissection they felt not pain. This might be caused by the current of monopolar electrocautery that dispersed to the remote grounding site, which out of the area that the ilioinguinal nerve and genitofemoral nerve supply.

Experience from the study allows us to recommend limited use of low-voltage electrocautery to stop bleeding. Bipolar electrocautery may reduce cautery effect associated with pain.

### Conclusion

In summary, spermatic cord block is successful in most patients and safe for orchietomy. It can be the alternative method of anesthesia in selected patient.

The surgeon should have a good knowledge of the anatomy of the spermatic cord, its nerves supplies and relation ship between them. For

preoperation , the patient needs to be explained the procedure and some symptoms that he may experience during the operation.

Spermatic cord block is not suitable in patient with anxiety or obesity. They should receive general or spinal anesthesia.

### References

1. Kaye KW, Lange PH, Fraley EE. Spermatic cord block in urologic surgery. *J Urol* 1982 Oct; 128(4): 720-1
2. Fuchs EF. Cord block anesthesia for scrotal surgery. *J Urol* 1982 Oct; 128(4): 718-9
3. Hinman F. *Atlas of Urologic Surgery*. 2<sup>nd</sup> ed. Philadelphia: W.B.Saunders, 1998: 75-76, 375-78
4. Berry M, Bannister LH, Standring SM. Nervous system. In: Williams PL, ed. *Gray's Anatomy*. 38<sup>th</sup> ed. New York: Churchill Livingstone, 1995: 1277-80