

## Successful repair of post myocardial infarction left ventricular aneurysm.

Kittichai Luengtaviboon\*

Supot Srimahachoti\* Supranee Niruthisard\*\*

Luengtaviboon K, Srimahachoti S, Niruthisard S. Successful repair of post myocardial infarction left ventricular aneurysm. *Chula Med J* 1996 Jun; 40(6): 495-502

*Postmyocardial infarction left ventricular aneurysm is not common, It is the result of transmural myocardial infarction. Small and medium size aneurysms are usually asymptomatic and do not require surgical intervention. Large aneurysms may cause three types of complications i.e. heart failure, embolisms, and ventricular arrhythmia. Rupture is rare in a true aneurysm. We report a young man with a one month old anteroseptal myocardial infarction who had heart failure, hypotension and chest pain typical of angina pectoris. His left ventricular ejection fraction was only 18 % with a huge left ventricular aneurysm. Despite inotropic support with dopamine and dobutamine and intravenous nitroglycerine, there was little improvement in his symptoms and blood pressure. A coronary angiogram showed total occlusion of the proximal anterior descending artery with no collaterals. Surgery was recommended. There was an area of localized rupture of the true left ventricular aneurysm which was contained by pericardium and pleura. The aneurysm was partially resected and remodeling aneurysmorrhaphy by "the Dor technique" was performed. The patient was weaned from the heart lung machine with adrenalin and dopamine. He recovered quite well with marked postoperative improvement in the dyspnea and chest pain. Resection of the left ventricular aneurysm gives good results in patient with large aneurysms with normal contraction of residual myocardium. It is a better choice compared to heart transplantation.*

**Key words:** *Left ventricular aneurysm, Dor technique of repair.*

Reprint request: Department of Surgery, Faculty of Medicine, Chulalongkorn University,  
Bangkok 10330, Thailand.

Received for publication. March 1, 1996.

\*Department of Surgery, Faculty of Medicine, Chulalongkorn University.

\*\*Department of Anesthesiology, Faculty of Medicine, Chulalongkorn University.

กิตติชัย เหลืองทวีบุญ, สุพจน์ ศรีมหาโชติ, สุปราณี นีรุตติศาสน์. การผ่าตัดซ่อมแซมภาวะหัวใจห้องซ้ายล่างโป่งพองที่เกิดตามหลังภาวะกล้ามเนื้อหัวใจตายจากการขาดเลือด. จุฬาลงกรณ์เวชสาร 2539 มิถุนายน; 40(6): 495-502

ภาวะหัวใจห้องซ้ายล่างโป่งพอง ซึ่งเกิดตามหลังภาวะกล้ามเนื้อหัวใจตายจากการขาดเลือดพบได้ไม่น้อย แต่มักมีขนาดเล็กหรือปานกลางซึ่งไม่ก่อให้เกิดอาการแทรกซ้อนและไม่ต้องการการผ่าตัด ภาวะหัวใจห้องซ้ายล่างโป่งพองซึ่งมีขนาดใหญ่จะมีภาวะแทรกซ้อนได้ 3 ประการคือ หัวใจวาย มีลิ้มเลือดหลุดไปอุดตามหลอดเลือดแดงต่าง ๆ ของร่างกาย และภาวะหัวใจเต้นผิดจังหวะ รายงานผู้ป่วยชายไทยอายุ 34 ปี ซึ่งมีประวัติสูบบุหรี่จัด และเกิดภาวะกล้ามเนื้อหัวใจตายเฉียบพลัน มีความดันโลหิตต่ำและภาวะหัวใจด้านซ้ายวาย ตรวจพบมีการบีบตัวของหัวใจด้านซ้ายล่างเพียง 18% และมีการโป่งพองของผนังหัวใจซ้ายล่างมีขนาดใหญ่มาก แม้ให้การรักษาด้วยยาเต็มที่ผู้ป่วยก็ไม่ดีขึ้น ฉีดสีหลอดเลือดหัวใจพบการอุดตันของหลอดเลือดแอลเอตี ในขณะที่ผ่าตัดพบมีการปริของหัวใจซ้ายล่าง ซึ่งโป่งพองออกได้ตัดผนังที่โป่งพองบางส่วนออกและใช้หลอดเลือดเทียมตัดเย็บแทนผนังส่วนที่ขาดหายไปหัวใจกลับมาทำงานได้ดี ผู้ป่วยมีอาการดีขึ้นมากหลังผ่าตัด ไม่มีอาการเหนื่อย อยู่ในโรงพยาบาล 2 สัปดาห์หลังผ่าตัด การติดตามเมื่อ 2 เดือนหลังผ่าตัด การติดตามเมื่อ 2 เดือนหลังผ่าตัด ผู้ป่วยทำงานเบา ๆ ได้ไม่มีอาการเหนื่อย หรือเจ็บหน้าอกอีก การผ่าตัดซ่อมแซมภาวะโป่งพองของหัวใจด้านซ้ายล่างโดยการใช้ผนังหลอดเลือดเทียมเย็บเป็นผนังของหัวใจซ้ายล่างแทนการเย็บโดยตรง ช่วยให้หัวใจซ้ายล่างมีขนาดไม่เล็กมากเกินไป และเป็นวิธีที่ยุงยากน้อยกว่าการผ่าตัดเปลี่ยนหัวใจ

Left ventricular aneurysms is an uncommon complication of acute myocardial infarction (MI). The incidence is decreasing due to improved early management of acute MI, including thrombolytic therapy and emergency revascularization. It is commonly associated with single left anterior descending artery occlusion. The location is anterior or apical part of the left ventricle. It usually takes one month before the aneurysm matures. The aneurysm is akinetic or dyskinetic and causes a marked decrease in the left ventricular stroke volume and ejection fraction. Blood stagnation predisposes to clot formation in the aneurysm. There are three complications of left ventricular aneurysm. These are heart failure, embolism arrhythmia. However, only large aneurysms are symptomatic and should be resected surgically. Preoperative coronary angiogram is mandatory, for combined coronary bypasses must be done at the time of the aneurysmectomy. Which is the best technique for the aneurysmectomy is controversial. Simple amputation gives small left ventricular cavity volume and is prone to postoperative low cardiac output. Patch repair or aneurysmorrhaphy is more attractive due to larger cavity size and better postoperative hemodynamics. But too large a patch will make the akinetic segment too large and may interfere with ventricular contractions. The technique described by Dor<sup>(1)</sup> gives good LV geometry and results in better hemodynamics. The long-term result is also better than other techniques.

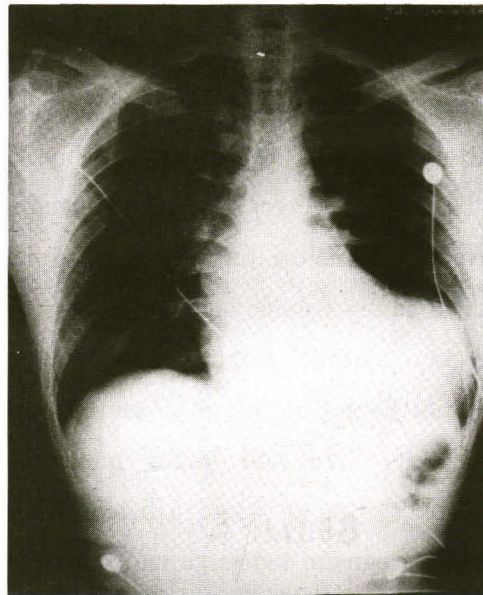
### Case Report

A 34 year old male was admitted to the Department of Medicine of Chulalongkor

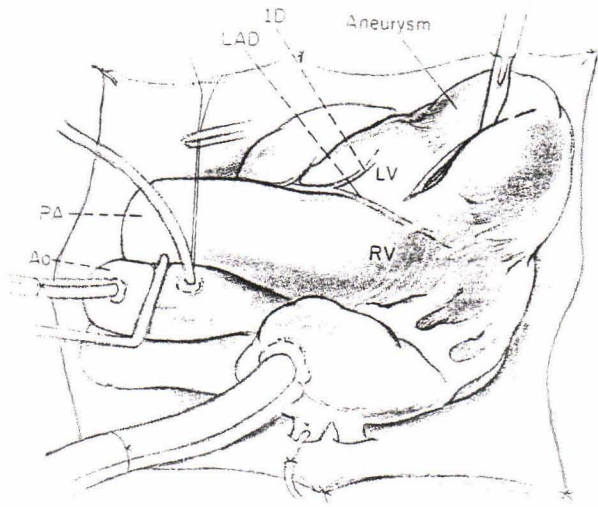
Hospital due to severe dyspnea and orthopnea. He had a one month history of chest pain. His ECG showed acute anterior myocardial infarction. An echocardiogram revealed an ejection fraction of 18% a huge anteroapical left ventricular aneurysm, and mild mitral insufficiency. He had congestive heart failure and angina despite treatment with isosorbide dinitrate, digitalis, and diuretics. A coronary angiography was planned but the patient refused it. He was discharged home with moderate heart failure and in functional class III. Five days before this presentation he had developed increasing dyspnea and frequent chest pain which improved with sublingual intrate. Orthopnea and paroxysmal nocturnal dyspnea were also present and this led to his admission. During admission his blood pressure was found to be 100/80 mmHg, heart rate 120/min and respiratory rate of 30/min. He was afebrile. Physical examination revealed engorged neck veins. S3 was present. No cardiac murmur was audible. Fine crepitation was found in both lower lung bases. He was admitted to the CCU and treated with intravenous heparin, dobutamine and dopamine. His blood pressure became unstable and tended to be hypotensive. His ECG did not change compared to a previous study. A chest X-ray showed cardiomegaly with a prominent apical shadow (Fig.1). The left side of the cardiac shadow nearly touched the left chest wall. Pulmonary congestion was clearly evident. An echocardiogram showed aneurysmal dilation of the apical and anterior part of the left ventricle with spontaneous echoes inside. The calculated left ventricular ejection fraction was less than 15%. The rest of the left ventricle and the right ven-

tricle had acceptable contractility and thickness. A coronary angiogram was performed which demonstrated total occlusion of the proximal left anterior descending artery, Late filling of that vessel was not seen. The rest of the coronaries were normal. He had more severe dyspnea and chest pain after the angiography. Surgical consultations for either conventional aneurysmectomy or cardiac transplantation were made. Because of the patients's economic compliance and the finding of the chest X-ray and echocardiogram, conservative surgery was selected as the better choice. With a median sternotomy incision, the heart was canulated with a single right atrial canula and ascending aortic canula. There was clearly an aneurysm of the anteroapical part of the left ventricle. The size was about 15 cm.in diameter. The aneurysm was densely adhered to the pericardium. A cardiopulmonary bypass with moderate systemic hypothermia and cold crystalloid cardioplegia was infused after aortic cross-clamping. The aneurysm was dissected from the pericardium with electrocautery. Unexpectedly, there was a localized area of rupture of the aneurysm with loculated clots confined by the pericardium. A segment of sero porosity dacron graft (Vascutex gelseal, size 30 mm.) was cut to convert into a rectangular shaped sheet. It measured 4.67 cm. long and 4 cm. wide. The junction between the inner surface of the aneurysm, which was smooth and white and normal myocardium, was identified. A purse string of 2/0 Ticon was made at this area to decrease the diameter of the defect

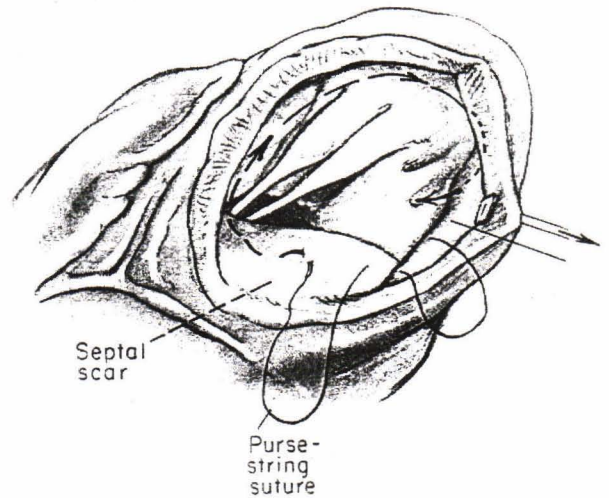
to about 4 cm. The patch was sutured to the inner wall of the aneurysm just outside the purse string suture with continuous 3/0 Prolene. The remnant of the aneurysm was then sutured together to cover the patch technique of operation. We could not initially wean the patient from the heart-lung machine. This was thought to be caused by invagination of the patch into the ventricle and resulting in a too small ventricle. The aneurysm wall stitch was removed to expose the patch. At this time the heart could take over from the machine with support with adrenalin, nitroglycerin an dopamine. His pulmonary and diastolic pressures decreased from 46 mmHg before repair to 32 mmHg after the repair.



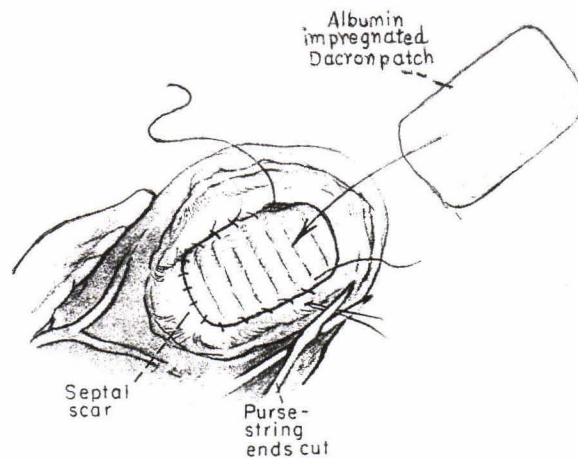
**Figure 1.** Chest X-ray before surgery showed marked cardiomegaly. with protrusion of left ventricle shadow due to aneurysm of left ventricle.



**Figure 2A.** Technique for repair of anterolateral left ventricular aneurysms by the remodeling ventriculoplasty method of Dor. Left ventricular approach of the aneurysm. All clots are removed.



**Figure 2B.** A purse string suture of 210 Dacron is placed along the junction between good ventricular and septal wall and scar. This suture will decrease the size of neck of aneurysm to improve its geometry.



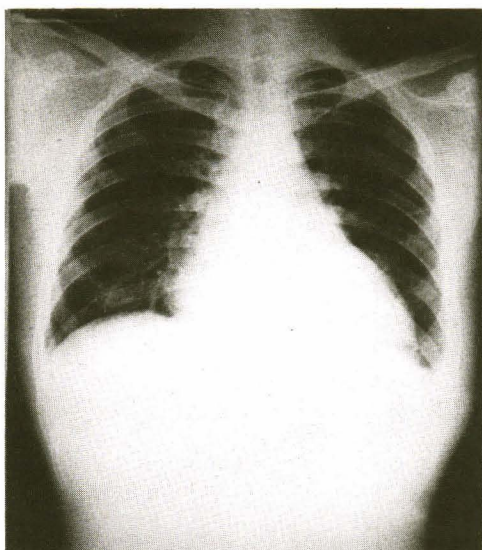
**Figure 2C.** The Dacron patch is cut to be a little larger than the orifice and is sewn into place with continuous 3-0 polypropylene suture.



In the ICU, primacor was added which further decreased PAD to 22 mmHg with good arterial pressure. He was progressively weaned from both adrenalin and dopamine. The patient recovered quite well and was extubated on the first postoperative day. There was only moderate postoperative bleeding, with chest tube drainage of 500 ml during the first 24 hours.

An echocardiogram was performed at the 10th day postoperatively. It revealed no significant mitral regurgitation. The ejection fraction of the left ventricle was 53 % . He was in functional class 3.

One month after surgery he was in functional class 2 and could do some work at home. There was no remaining angina or dyspnea. A chest X-ray showed near normal cardiac shadow (Fig.3).



**Figure 3.** Chest X-ray after repair of left ventricle by Dor's technique (Endoaneurysmorrhaphy). There was decrease in cardiac shadow and contour of left ventricle looked normal.

## Discussion

The LV aneurysm wall is thin and clearly demarcated. Its inner surface is smooth with varying amounts of mural thrombus attached to it. Fibrous tissue of the type present in aneurysms takes at least one month to form.<sup>(2)</sup> 85% are located anterolaterally near the apex.<sup>(3)</sup> Most patients experience dyspnea which persist from the time of infarction<sup>(4)</sup> 15-30 % have symptoms related to ventricular tachycardia which may become intractable to medical treatment and cause death.<sup>(4)</sup> Despite the fact that about one-half of aneurysms contain a clot, thromboembolism occurs in only a small proportion of patients.<sup>(5)</sup> LV aneurysms do not increase appreciably in size for more than 6 months after their genesis. The nonaneurysmal portion of the left ventricular wall is subject to increased systolic wall stress as the ventricular size increases (as described by LaPlace's law) and may ultimately lose its systolic reserve and contribute to left ventricular enlargement and failure.<sup>(6)</sup> Klein showed that inactivation (by akinesis or dyskinesis) of at least 20 % of the left ventricular wall area is required for left ventricular enlargement to be stimulated.<sup>(7)</sup> The paradoxical movement in the aneurysmal portion of the wall reduces the efficiency of the ventricle because systolic work is wasted on expansion of the aneurysm.<sup>(8)</sup> The size of the aneurysm is a risk factor for premature death in surgically untreated patients . In patients with small aneurysms (usually without symptoms of heart failure, the probability of survival is dictated primarily by the severity and extent of their coronary arterial stenoses. Functional characteristics of the remainder of the ventricle are

major determinants of survival. The technique of repair by using patch closure, as described by Dor and colleagues, is suitable for anterior aneurysms. This technique is a remodeling ventriculoplasty which results in improved left ventricular function. Fontan determined that the Dacron patch should be oval and should have a long diameter of 2.0 to 2.5 cm in situ.<sup>(9)</sup> Too large a patch will produce too large an end-systolic volume and reduces the global ejection fraction, whereas too small a patch reduces ventricular volume excessively. The survival rate for surgically resected large aneurysms is higher than those after nonsurgical treatment.<sup>(10)</sup> Rupture is rare in a true aneurysm, but it is common in false aneurysms. Our patient developed a large aneurysm with congestive heart failure, low cardiac output and localized rupture, which may have been the precipitating factor causing clinical deterioration and which required a second admission. Therefore it was clear that surgery was the only chance for survival of this patient. Heart transplantation is another choice, but due to scarcity of available donor hearts and the long waiting time, this patient was likely to die before a suitable heart would be available. Repair was predicted to likely be successful for couple of reasons. Firstly, the remaining left ventricle had reasonable contractility. The coronary involvement was single LAD occlusion with normal anatomy in the other coronary arteries. Late deaths after surgery in about third of the patients are usually due to chronic congestive heart failure, but the Dor modification of the operation may reduce this figure. Dor reported improved survival rates using his technique as compared to the classical

technique of repair.<sup>(11)</sup> Most long-term survivors have a reasonable period of marked symptomatic improvement after LV aneurysmectomy. Our case demonstrates that the technique of LV aneurysmorrhaphy is a better alternative to transplantation. It can be done with minimal morbidity and mortality with generally reliable good results.

## References

1. Dor V, Saab M, Coste P, Loraszeweska M, Montiglio F. Left ventricular aneurysm: a new surgical approach. *Thorac Cardiovasc Surg* 1989 Feb; 37(1):11-9
2. Dubnow MH, Burchell HB, Titus JL. Postinfarction ventricular aneurysm. A clinicomorphologic and electrocardiographic study of 80 cases. *Am Heart J* 1965 Dec;70(6):753-60
3. Buehler DL, Stinson EB, Oyer PE, Shumway NE. Surgical treatment of aneurysms of the inferior left ventricular wall. *J Thorac Cardiovasc Surg* 1979 Jul;78(1):74-8
4. Rogers WJ, Oberman A, Kouchoukos NT. Left ventricular aneurysmectomy in patients with single vs multivessel coronary artery disease. *Circulation* 1978 Sep;58 (Suppl 2):I-50-I-56
5. Barratt-Boyes BG, White HDD, Agnew TM, Pemberton JR, Wild CJ. The results of surgical treatment of left ventricular aneurysms. An assessment of the risk factors affecting early and late mortality. *J Thorac Cardiovasc Surg* 1984 Jan;87(1): 87-98
6. Klein MDD, Heraman MV, Gorlin R. A hemodynamic study of left ventricular

- aneurysm. *Circulation* 1967 Apr;35(4):614-30
7. Cabin HS, Roberts WC. True left ventricular aneurysm and healed myocardial infarction. Clinical and necropsy observations including quantification of degrees of coronary arterial narrowing. *Am J Cardiol* 1980 Nov;45(5):754-63
8. Jan KM. Distribution of myocardial stress and its influence on coronary blood flow. *J Biomech* 1985;18(11):815-20
9. Fontan F. Transplantation of knowledge. *J Thorac Cardiovasc Surg* 1990 Mar;99(3):387-95
10. Cullhed I, Delius W, Bjork I, Hellen A, Nordgren I. Resection of left ventricular aneurysm: late results. *Acta Med Scand* 1975 Apr;197(4):241-8
11. Donaldson RM, Honey M, Balcon R, Banium SO, Sturridge MG, Wright JEC. Surgical treatment of postinfarction left ventricular aneurysm in 32 patients. *Br Heart J* 1976 Dec;38(12):1223-8