

## Spinal fracture complicating ankylosing spondylitis from swimming : a case report

Areerat Anannontsak\*

Sek Aksaranugraha\*

Anannontsak A, Aksaranugraha S. Spinal fracture complicating ankylosing spondylitis from swimming : a case report. *Chula Med J* 1995 Aug; 39(8): 601-606

*An osteoporotic condition of the spine of patients with longstanding ankylosing spondylitis is prone to fracture. Swimming is the most effective recreational exercise recommended for patients who suffer from this disease. The advantages of swimming are maintenance of range of motion of both the axial and peripheral joints, improvement of chest expansion and pulmonary function, improvement of cardiovascular endurance. This is a case report of longstanding ankylosing spondylitis demonstrated in the L4 vertebra and its posterior element fractures. The cause of the subject's fractures were postulated to be rotated and hyperextended forces experienced during swimming. In this rigid spine patient, repeated movements such as rotation and hyperextension, even in forces of a small amounts might produce a fracture in the spine. This is a good example to remind any doctor that swimming should be recommended only in early stage of ankylosing spondylitis but not in the late one complicated with severe spinal osteoporosis.*

**Key words:** *Ankylosing spondylitis, Osteoporotic spine, Spinal fracture, Swimming.*

Reprint request : Department of Rehabilitation Medicine, Faculty of Medicine,  
Chulalongkorn University, Bangkok 10330, Thailand.

Received for publication. June 15, 1995.

อารีรัตน์ อนันต์นนท์ศักดิ์, เสก อักษรานุเคราะห์. ภาวะกระดูกสันหลังหักจากการว่ายน้ำ  
ในผู้ป่วยโรคกระดูกสันหลังอักเสบชนิดยึดติด. จุฬาลงกรณ์เวชสาร 2538 สิงหาคม;  
39(8): 601-606

ภาวะกระดูกสันหลังโป่งบางในผู้ป่วยที่เป็นโรคกระดูกสันหลังอักเสบชนิดยึดติดเป็นระยะ  
เวลานานมีโอกาสเกิดกระดูกหักได้ง่าย การว่ายน้ำเป็นการออกกำลังกายที่ดีที่สุดที่มักจะแนะนำใน  
ผู้ป่วยโรคนี้ มีข้อดี คือ ช่วยคงพิสัยการเคลื่อนไหวของข้อต่างๆ ในร่างกายทั้งข้อกระดูกสันหลังและ  
ข้อของกระดูกแขนและขา ช่วยเพิ่มการขยายตัวของทรวงอก การทำงานของปอดและหัวใจดีขึ้น  
เพิ่มความทนทานของร่างกาย รายงานผู้ป่วยรายนี้เป็นโรคกระดูกสันหลังอักเสบชนิดยึดติดเป็น  
ระยะเวลานานเกิดกระดูกสันหลังระดับเอวข้อที่ 4 หัก สาเหตุคาดว่าเกิดจากแรงหมุนตัวและแรง  
จากการเหยียดขาและแอ่นหลังขณะว่ายน้ำ ในผู้ป่วยโรคนี้ แม้แรงเพียงขนาดเล็กน้อย ตัวอย่างเช่น  
ในผู้ป่วยรายนี้ก็สามารถทำให้กระดูกสันหลังหักได้ รายงานผู้ป่วยรายนี้เป็นตัวอย่างที่ดีว่า ในการ  
ที่แพทย์จะแนะนำการว่ายน้ำแก่ผู้ป่วยโรคนี้ ควรแนะนำเฉพาะในระยะแรกของโรค ถ้ารายที่เป็น  
มานานหลายปีจนมีภาวะกระดูกสันหลังโป่งบางแล้วไม่ควรแนะนำ

August 1995

Spinal fractures of ankylosing spondylitis are an infrequent though not rare complication. Commonly, they occur in the cervical spine, but are rare in the lumbar spine which are more often caused by more violent trauma.<sup>(1-3)</sup> Leca and Sicard (1970) and Hunter and Dubo (1978) found fractures below the cervical spine in less than one fifth of patients.<sup>(2)</sup> The incidence of neurological complications are much higher in the cervical region. High thoracic fractures are usually regarded as rather stable, whereas fractures at the thoracolumbar junction are considered unstable and prone to neurological complication. Lumbar fractures always have fewer neurological complications.<sup>(1-4)</sup>

The diagnosis of spinal fractures in advanced ankylosing spondylitis may be difficult for several reasons. Firstly, the spinal trauma is often trivial and would not be expected to cause spinal fracture. Secondly, the neurological damage may or may not occur. Thirdly is the difficulty in radiologic visualization of the fracture site. In the flexion deformity of the spine the erosive and sclerotic changes and the concomitant spinal osteoporosis may make the fracture area unclear. Fourthly is the continuous pain episodes from the underlying inflammatory spondylitis, so additional pain sensations may pass unrecognized.<sup>(1-15)</sup> Early recognition of the fractures and prompt therapy may improve the prognosis. This is the first case report in the world of lumbar fracture in ankylosing spondylitis resulted from swimming which is not a violent trauma.<sup>(1-15)</sup>

## Case report

A thirty-five year old man was consulted for rehabilitation at Chulalongkorn Hospital in March 1993. He has had a 20 years history of ankylosing spondylitis. He developed an acute severe low back pain while he was swimming one day before admission. Clinical findings revealed severe low back pain on changing his position with marked tenderness at the spinous process of the fourth vertebrae. Straight leg raising test were negative on both sides. There was no neurological deficit.

Total and differential white blood cell counts and the erythrocyte sedimentation rate were within normal limits. Radiographic findings revealed a classical bamboo spine with marked osteoporosis and radiolucent lines at the posterior element and vertebral body of the fourth lumbar spine. This was suspected of fracture which was confirmed by CT scan. (fig 1, 2, 3, 4) A bone scan showed increased radioisotope uptake at the seventh cervical vertebra, the fourth lumbar vertebra and the first sacral vertebra. (fig 5) Magnetic resonance imaging showed no acute lumbar disc herniation. Bed rest for four weeks with administration of a nonsteroidal-antiinflammatory drug and a muscle relaxant were prescribed, together with a rehabilitation program to relieve the pain by using modalities and to maintain range of motion, strength and endurance. The bone mass density was 0.77 g/square cm., below two standard deviation of normal values. Nasal calcitonin spray was also prescribed for relief of the severe pain and to prevent from bone resorption. The pain progressively decreased and the patient started progressive ambulation in the fourth week with lumbosacral corset supporting the lumbar spine.

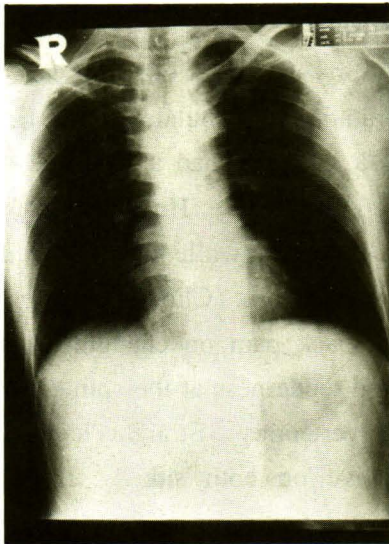


Figure 1. Chest x-ray showed classical bamboo spine with marked osteoporosis.

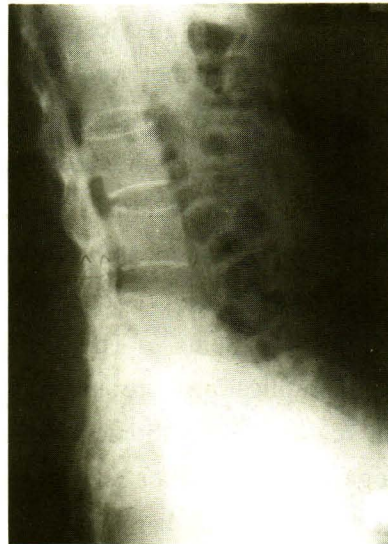

Figure 2. X-ray: L-S spine, lateral view showed radiolucent lines at posterior element and vertebral body of the fourth lumbar spine suspected of fracture.

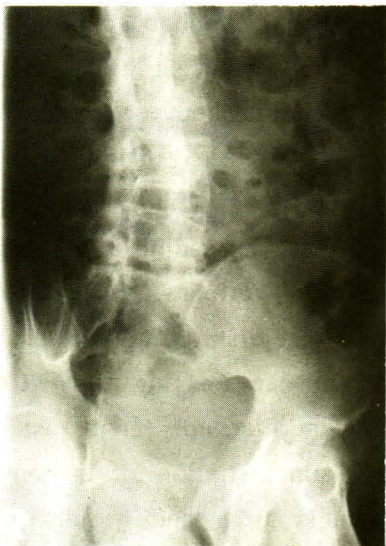

Figure 3. X-ray: L-S spine, oblique view showed radiolucent lines at areas correspond to lateral view.

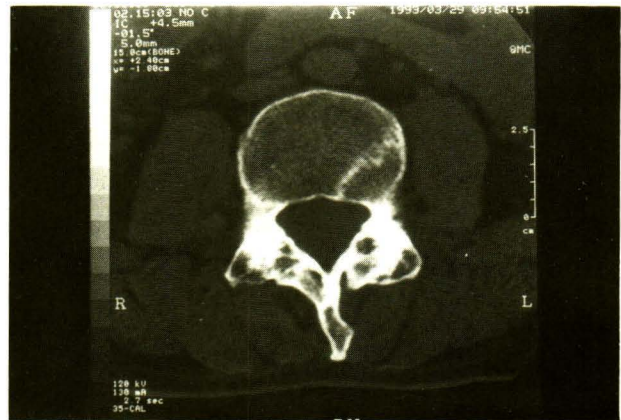


Figure 4. CT scan confirmed the fracture at vertebral body of the fourth lumbar spine.

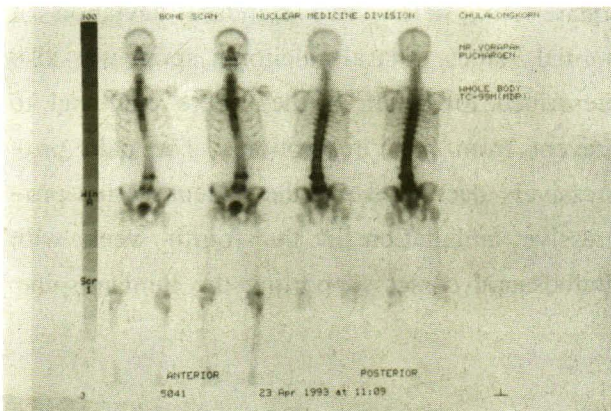
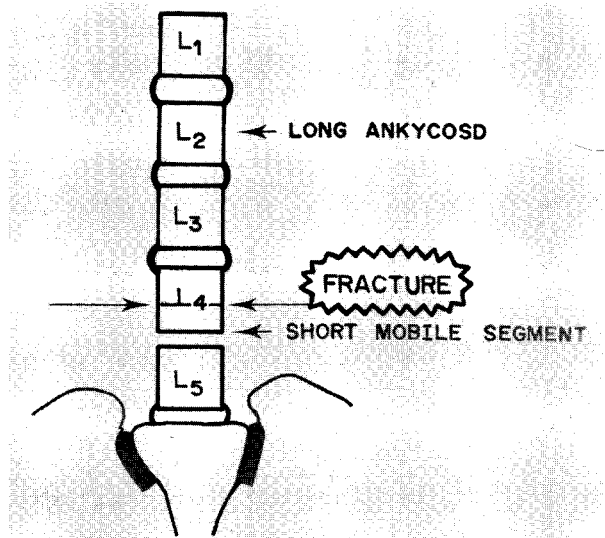


Figure 5. Bone scan showed increase radioisotope uptake at the seventh cervical vertebra, the fourth lumbar vertebra and the first sacral vertebra.

## Discussion

Vertebral osteoporosis is a well recognised radiological feature of advanced ankylosing spondylitis. The spinal fracture site most frequently involved is the cervical, thoracic and lumbar spine segments, respectively.

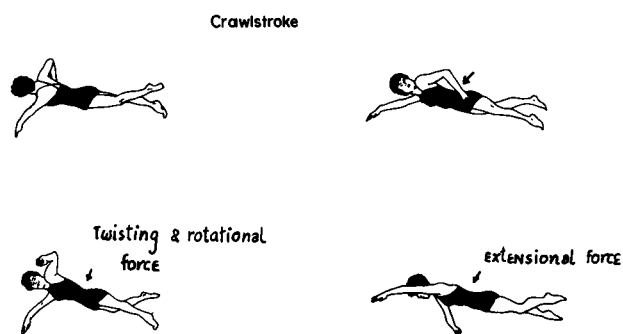
There are three possible explanations for the fourth lumbar spinal fracture in this case. Firstly, radiographic features of this patient showed a free area of ankylosis at the fourth and the fifth lumbar intervertebral space. This segment escaped from fusion while other levels had become ossified, causing high stress and biomechanical failure between the long ankylosed and short mobile segments. (fig. 6) Secondly, the bone density measurement in this case showed severe osteoporosis. The repetitive



**Figure 6.** There is a free area of ankylosis at the fourth and the fifth lumbar intervertebral space, which escaped fusion while other levels become ossified which produced high stress and biomechanical failure between long ankylosed and short mobile segments.

small rotated forces that should not cause fracture to a normal spine, could do so in an osteoporotic spine. Thirdly, a stiff kyphotic spine might result in high stress near the most mobile segment, and with repeated trauma it could lead to fatigue and a stress fracture.

Swimming, as a non-weight bearing exercise, is the most recommended recreational exercise in ankylosing spondylitis, but it can cause twisting and rotational forces. In addition, a kicking legs extended force can cause fracture at the most mobile fragile spine, as in this case.(fig 7)



**Figure 7.** Swimming can cause twisting and rotational force. In addition kicking legs, extended force can cause fracture at the most mobile fragiled spine.

## Conclusion

An osteoporotic spine of patients with longstanding ankylosing spondylitis is prone to fracture. This is a good example to remind any doctor that swimming should be recommended only in an early stage of ankylosing spondylitis, but not in a late one complicated with severe spinal osteoporosis.

## References

1. Fast A, Parikh S, Marin EL. Spinal fractures in ankylosing spondylitis. *Arch Phys Med Rehabil* 1986 Sep; 61(9):595-7
2. Thorngren KG, Liedberg E, Aspelin P. Fractures of the thoracic and lumbar spine in ankylosing spondylitis. *Arch Orthop Traumat Surg* 1981; 98(2):101-7
3. Gelman MI, Umber JS. Fractures of the thoracolumbar spine in ankylosing spondylitis. *An J Roentgenol* 1978 Mar; 130(3):485-91
4. Ralston SH, Urquhart GDK, Brzeski M, Sturrock RD. Prevalence of vertebral compression fractures due to osteoporosis in ankylosing spondylitis. *BMJ* 1990 Mar 3; 300(6724):563-5
5. Wilkinson M, Bywaters EGL. Clinical features and courses of ankylosing spondylitis. *Ann Rheum Dis* 1958; 17: 209-28
6. Guttmann L. Traumatic paraplegia and tetraplegia in ankylosing spondylitis. *Paraplegia* 1966 Nov; 4:188-203
7. Hunter T, Dubo H. Spinal fractures complicating ankylosing spondylitis. *Ann intern med* 1987 Apr; 88(40):546-9
8. Woodruff FP, Dewing SB. Fracture of the cervical spine in patients with ankylosing spondylitis. *Radiology* 1963 Jan; 80(1): 17-21
9. Kanefield DG, Mullins BP, Freehafer AA, Furey JG, Horenstein S, Chamberlin WB. Destructive lesions of the spine in rheumatoid ankylosing spondylitis. *J Bone Surg* 1969 Oct; 51-A(7):1369-75
10. Yau AC, Chan RN. Stress fracture of the fused lumbo-dorsal spine in ankylosing spondylitis: a case report of three cases. *J Bone Joint Surg* 1974 Nov; 56-B(4): 681-7
11. Corke CF. Spinal fracture and paraplegia after minimal trauma in a patient with ankylosing vertebral hyperostosis. *BMJ* 1981 Jun 20; 282(6281):2035
12. Bergmann EW. Fractures of the ankylosed spine. *J Bone Joint Surg* 1949; 31-A: 669-71
13. Hansen ST Jr, Taylor TKF, Honet JC, Lewis FR. Fracture-dislocations of the ankylosed thoracic spine in rheumatoid spondylitis. Ankylosing spondylitis, Marie-Strumpell disease. *J Trauma* 1967 Nov; 7(6):827-37
14. Grisolia A, Bell RL, Peltier LF. Fractures and dislocations of the spine complicating ankylosing spondylitis: a report of six cases. *J Bone Joint Surg (Am)* 1967 Mar; 49-A(2):339-44
15. Hunter T, Dubo H. Spinal fractures complicating ankylosing spondylitis. a long-term follow up study. *Arthritis Rheum* 1983 Jun; 26(6):751-9