

## Successful transcatheter embolization of traumatic hepatic artery false aneurysm : case report.

Boonchoo Sirichindakul\*

Suvit Sriussadaporn\* Somjai Wangsupachart\*\*

**Sirichindakul B, Sriussadaporn S, Wangsupachart S. Successful transcatheter embolization of traumatic hepatic artery false aneurysm : case report. Chula Med J 1995 Jul;39(7): 537-542**

*A case of traumatic hepatic artery false aneurysm is presented. A 45-year-old female patient had a gunshot wound of the liver which was treated by suturing the entrance and exit of the bullet tract 3 months before this admission. She was referred to Chulalongkorn Hospital because of false aneurysm of the right hepatic artery detected by ultrasonography on routine follow up. A CT scan of the abdomen with arterial enhancement revealed a 4x3x3 cm.<sup>3</sup> intrahepatic hematoma in the right lobe of the liver. Angiography via the right common femoral artery was performed and a false aneurysm arising from the segmental branch of the right hepatic artery was demonstrated. Embolization of the right hepatic artery with Gelfoam was subsequently performed successfully. The patient was well and discharged 2 days later. Follow up CT scans at 1 and 3 months postembolization revealed a near complete resolution of the intrahepatic hematoma with no arterial enhancement. Percutaneous transcatheter embolization is an effective and safe procedure for management of posttraumatic hepatic artery false aneurysm. The procedure is simple and may spare the patients from potentially dangerous major hepatic surgery.*

**Key words :** *False aneurysm, Hepatic artery.*

Reprint request : Sirichindakul B, Department of Surgery, Faculty of Medicine  
Chulalongkorn University, Bangkok 10330, Thailand.

Received for publication. May 15, 1995.

\* Department of Surgery, Faculty of Medicine, Chulalongkorn University.

\*\*Department of Radiology, Faculty of Medicine, Chulalongkorn University.

บุญชู ศิริจินดากุล, สุวิทย์ ศรีอัมภพร, สมใจ หวังศุภชาติ. การรักษาเส้นเลือดโป่งพองในเนื้อตับที่เกิดจากการถูกยิงด้วยวิธีการอุดเส้นเลือดผ่านทางผิวหนัง. จุฬาลงกรณ์เวชสาร 2538 กรกฎาคม;39(7): 537-542

ผู้ป่วยหญิงไทยคู่อายุ 45 ปี มีประวัติได้รับบาดเจ็บที่ตับจากการถูกยิงเมื่อ 3 เดือน ก่อนรักษาโดยการผ่าตัดเย็บปิดบาดแผลที่ตับ ต่อมาตรวจพบจากอัลตราซาวด์ว่ามีโพรงก้อนเลือดในเนื้อตับกลีบขวา ทำการตรวจเพิ่มเติมโดยเอ็กซเรย์คอมพิวเตอร์ พบว่ามีเส้นเลือดโป่งพองอยู่ในบริเวณโพรงของก้อนเลือด ได้ทำการรักษาผู้ป่วยโดยวิธีการอุดเส้นเลือดผ่านทางผิวหนัง (Percutaneous Transcatheter Embolization; PTE) จากการติดตามผู้ป่วยด้วยเอ็กซเรย์คอมพิวเตอร์ เมื่อ 1 เดือนและ 3 เดือนหลังจากการทำPTE พบว่า โพรงก้อนเลือดในตับมีขนาดเล็กลง และไม่พบว่ามีเส้นเลือดโป่งพอง PTE เป็นวิธีการที่ปลอดภัยและมีประสิทธิภาพในการรักษาผู้ป่วยที่มีเส้นเลือดโป่งพองของตับจากอุบัติเหตุ นอกจากนี้ยังช่วยให้ผู้ป่วยไม่ต้องเสี่ยงต่อการผ่าตัดอีกด้วย

Traumatic hepatic artery false aneurysm has been diagnosed with increasing frequency owing to modern advanced imaging modalities and angiography. Angiography not only plays an important role for diagnostic purposes but also contributes an invaluable therapeutic method, namely percutaneous transcatheter embolization (PTE).<sup>(1-3)</sup> Because the acceptance of PTE as a standard treatment for various vascular pathologies of the liver, there are many case reports of PTE for management hepatic artery aneurysm since 1977.<sup>(4)</sup> Advantage of PTE not only spares the patient from an unnecessary extensive hepatic surgery but also reduces morbidity and mortality.<sup>(1,2,5,6)</sup> We present a case of hepatic artery false aneurysm from gunshot wound which was successfully treated with PTE.

### Case presentation

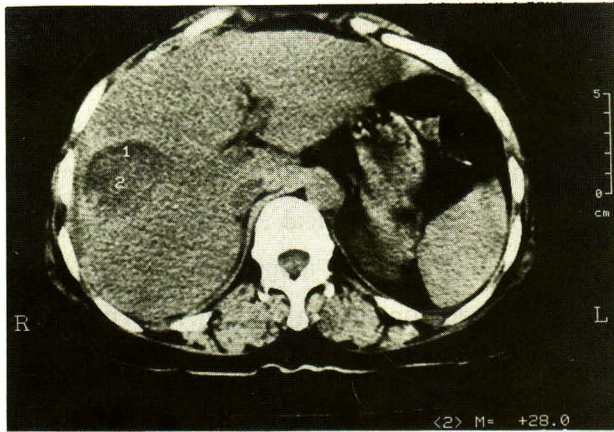
A 45-year-old woman was referred to Chulalongkorn Hospital from a rural hospital with diagnosis of hepatic artery false aneurysm. Three months prior, she had sustained a gunshot wound in the right upper quadrant of her abdomen and she underwent emergency exploratory laparotomy. At operation, a complete penetration of the right lobe of the liver was found and treated by suturing the hepatic parenchyma together (hepatorrhaphy). She had an uneventful recovery and was discharged 2 weeks later. Although she was asymptomatic, a sequential check up of her liver with ultrasonography demonstrated an intrahepatic hematoma in the right lobe

which had increased in size. Arterial flow into the hematoma was also detected by doppler ultrasonography. She was subsequently transferred to Chulalongkorn Hospital.

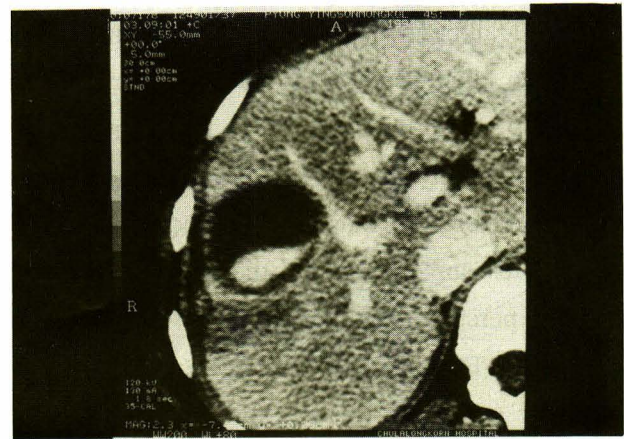
The initial physical examination revealed a healthy woman with a midline scar from the previous operation on her abdomen. The blood pressure was 130/80 mmHg, the pulse rate 80 beats/min., and the BT 36.5°C. No abnormal physical finding was detected.

Laboratory findings; CBC Hb 12.4 gm%, Hct 38%, WBC 6500 cell/mm<sup>3</sup> and platelet 250,000 cell/mm<sup>3</sup>. Liver function tests: TB 0.61 mg%, DB 0.53 mg%, SGOT 25 u/L, SGPT 20 u/L and Alkaline phosphatase 136 u/L.

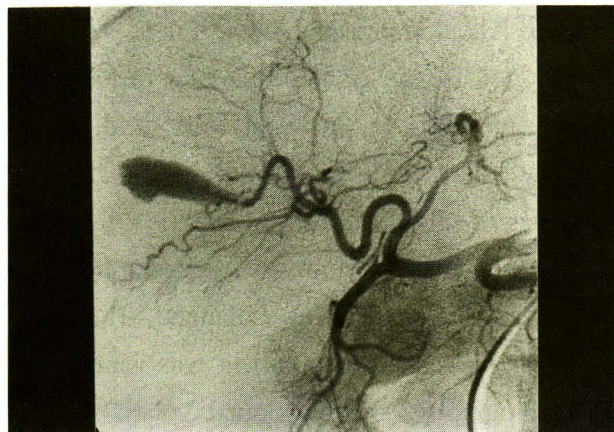
A CT scan of the abdomen revealed an 4x3x3 cm<sup>3</sup> mass in the right lobe of the liver partially filled with contrast material and the diagnosis of false aneurysm of hepatic artery was established. (Fig. 1 and 2) Angiography with possible PTE were electively planned. However, two days later, while the patient was waiting for the angiography, she developed colicky abdominal pain with stable vital signs. The hematocrit level dropped from 38% to 31%. An impending rupture of the intrahepatic hematoma or leaking of blood into the biliary tract was suspected and emergency angiography via the right common femoral artery was subsequently performed 10 hours later. A false aneurysm arising from the segmental branch of right hepatic artery was demonstrated and successfully embolized with Gelfoam. (Fig.3 and 4).



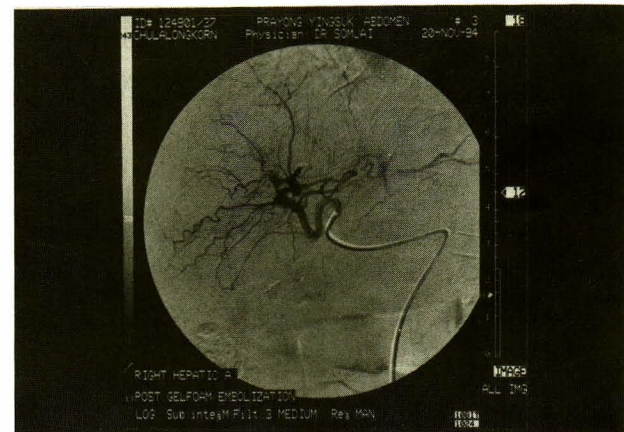
**Figure 1.** Pre-contrast CT scan shows mixed hypodensity and isodensity mass, 4x3x3 cm<sup>3</sup>, at anterior segment of right lobe of the liver.



**Figure 2.** Post IV contrast scan shows partial filling of the contrast medium in the lesion suggestive of false aneurysm.



**Figure 3.** Hepatic artery angiogram reveals an aneurysm sized 3.1x1.4 cm. extending from segmental branch of right hepatic artery with relatively surrounding hypovascular area indicated surrounding clot or hematoma.

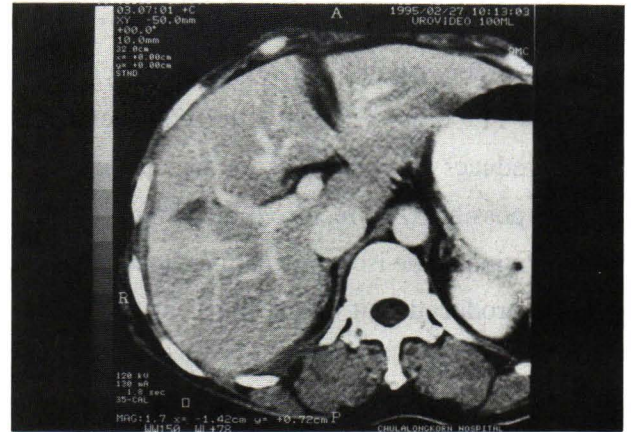
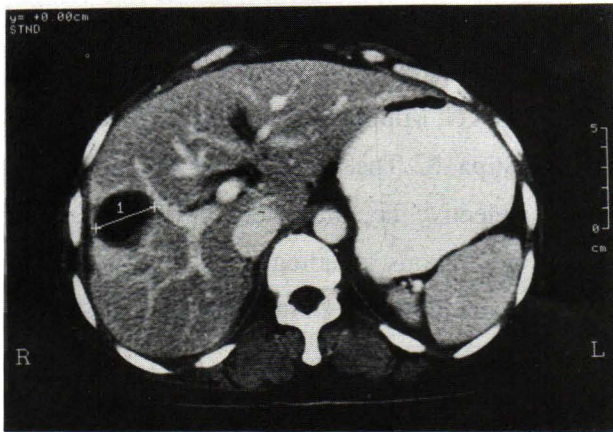


**Figure 4.** After gelfoam embolization via superselective right hepatic artery approach, there is no further visualization of the aneurysmal lesion.

The postembolization course was uneventful and she was discharged 2 days later with normal liver function tests. One and three months after embolization she was seen at the Outpatient Department with normal results.

Contrast enhanced CT scans performed 1 and 3 months postembolization revealed a small residual lesion in the right lobe of the liver suggestive of a healing hematoma with no evidence of recurrent false aneurysm. (Fig 5a and 5b).





**Figure 5 a & b.** One month (a) and three months (b) post embolization; Decreasing in size of the lesion is showed.

### Discussion

Hepatic artery false aneurysm was first described by Dr. Wilson in 1809 in a 50-year-old man who died because of rupture of a large aneurysm of the left hepatic artery.<sup>(7)</sup>

The false aneurysm may result from trauma,<sup>(1,3,4,7,8)</sup> iatrogenic procedures such as percutaneous liver biopsy, transhepatic cholangiography and biliary drainage<sup>(2,8)</sup> and infective processes which were common in the past.<sup>(1,4,7,9)</sup>

Pitfall at the initial operative management of a hepatic injury can contribute to the development of a hepatic artery false aneurysm. Suture repair of the liver wound without hepatotomy to open up the bullet tract in gunshot wounds of the liver may occasionally be successful if no branch of the hepatic artery is injured. When branches of the hepatic artery are injured as in the bullet tract in this case, false aneurysm formation is inevitable without suture ligation of the injured vessels. This forms the basis of management of penetrating injuries of the liver by hepatotomy and suture ligation of bleeding vessels.<sup>(8)</sup> However, when the bullet tract is located in the depth of liver parenchyma and hepatotomy, unroofing the

tract may be dangerous, it can be left undisturbed. If injury to branches of the hepatic artery is doubtful or strongly suspected, angiography and PTE may be performed later.<sup>(8)</sup>

Complications of false aneurysms of hepatic artery are ruptured intrahepatic hematoma,<sup>(7-9)</sup> hemobilia,<sup>(1-3,5-9)</sup> liver abscess,<sup>(8)</sup> all of which are potentially fatal if improperly treated.

In the past, most hepatic artery false aneurysms were treated by surgical means, i.e. hepatic arterial ligation<sup>(1-4,6,7,9)</sup>, hepatotomy and suture ligation of the feeding hepatic artery<sup>(6,9)</sup> and frequently hepatic resection.<sup>(1-3,5,8,9)</sup> High morbidity and mortality have been reported with such surgical management<sup>(1)</sup> which have been now almost totally replaced by angiography and therapeutic embolization.<sup>(1,2,6,9)</sup>

Successful PTE for posttraumatic hepatic artery false aneurysm was introduced in the late 1970s<sup>(10,11)</sup> It has been employed with increasing popularity and is widely accepted nowadays. Several advantages of PTE over surgical approaches have been described.<sup>(2,4)</sup> It is a treatment that can be repeated. It is safer because it deals directly with the arterial lesion. It is better tol-

rated in debilitated patients who are poor surgical risks. Surgery should be reserved for cases in which PTE fails.<sup>(2)</sup> Highly selective embolization reduces both the risk of hepatic necrosis and the possibility of recurrent bleeding.<sup>(4,6)</sup> After embolization, some ischemic damage to hepatocyte may be produced, but this is transient because of the blood supply by the portal system and the rapid development of an intrahepatic arteriole collateral circulation.<sup>(3)</sup>

In conclusion, PTE is an effective and safe procedure for the management of posttraumatic hepatic artery false aneurysm. The procedure is simple and may spare the patients from potentially dangerous major hepatic surgery.

## References

1. Kadir S, Athanasoulis CA, Ring EJ, Greenfield A. Transcatheter Embolization of intrahepatic arterial aneurysms Radiology 1980 Feb; 134(2):335-9
2. Hirsch M, Avinoach I, Keynan A, Khodadadi J. Angiographic diagnosis and treatment of hemobilia. Radiology 1982 Sep; 144(4): 771-2
3. Curet P, Baumer R, Roche A, Grellet J, Mercadier M. Hepatic hemobilia of traumatic or iatrogenic origin ; recent advances in diagnosis and therapy, review of the literature from 1976 to 1981. World J Surg 1984 Feb; 8(1):2-8
4. Goldblatt M, Goldin AR, Shaff MI. Percutaneous embolization for the management of hepatic artery aneurysm. Gastroenterol 1977 Nov;73(5):1142-6
5. De Toma G, Mingoli A, Modini C, Cavallaro A, Stipa S. The value of angiography and selective hepatic artery embolization for continuous bleeding after surgery in liver trauma : case reports. J Trauma 1994 Sep; 37(3):508-11
6. Czerniak A, Thompson JN, Hemingway AP, Soreide O, Benjamin IS, Allison DJ, Blumgart LH. Hemobilia: A disease in evolution. Arch Surg 1988 Jun; 123(6): 718-21
7. Sheridan JT. Hepatic artery aneurysm : report of a case and review of the literature. Arch Surg 1956 Feb; 72(2):300-10
8. Croce MA, Fabian TC, Spiers JP, Kudsk KA. Traumatic hepatic artery pseudoaneurysm with hemobilia. Am J Surg 1994 Sep; 168(3):235-8
9. Jonsson K, Bjernstad A, Eriksson B. Treatment of a hepatic artery aneurysm by coil occlusion of the hepatic artery. AJR 1980 Jun;134(6):1245-7
10. Bass EM, Crosier JH. Percutaneous control of post traumatic hepatic hemorrhage by gelfoam embolization. J Trauma 1977 Jan; 17(1):61-3
11. Rubin BE, Katzen BT. Selective hepatic artery embolization to control massive hepatic hemorrhage after trauma. AJR 1977 Aug; 129(2):253-6