

Prenatal sonographic diagnosis of hydrops fetalis in Chulalongkorn Hospital.

Teera Wacharaprechanont * Boonchai Uerpairojkij*

Yuen Tannirandorn * Dhiraphongs Charoenvidhya* Sukhit Phaosawasdi*

Wacharaprechanont T, Uerpairojkij B, Tannirandorn Y, Charoenvidhya D, Phaosawasdi S. Prenatal sonographic diagnosis of hydrops fetalis in Chulalongkorn Hospital. *Chula Med J* 1994 Nov; 38(11): 667-677

Objective : *The use of sonographic findings to evaluate the etiology of fetal hydrops and to determine the types of hydrops*

Study design : *Retrospective descriptive study*

Result : *Twenty cases with prenatally diagnosed hydrops fetalis underwent sonographic study in Chulalongkorn Hospital between September 1, 1993 and July 31, 1994. Three patients had previously delivered a hydropic baby. Homozygous alpha-thalassemia was the most frequent (35%) cause, followed by infectious cause (20%), cystic hygroma (15%) and cardiac anomalies (10%). One case of Rh isoimmunization (5%) was detected. Hydrops fetalis was associated with an increased incidence of maternal anemia, polyhydramnios, prematurity and preeclampsia-like syndrome.*

Sonographic criteria were developed to aid in determining the cause of hydrops fetalis (anemia-related causes or non-anemia-related causes).

Conclusion: *Sonography had a major role in the identification, evaluation and management of the hydropic fetuses.*

Key words: *Hydrops fetalis, Ultrasonography, Etiology, Alpha-thalassemia.*

Reprint request : Wacharaprechanont T, Department of Obstetrics and Gynecology, Faculty of Medicine, Chulalongkorn University, Bangkok 10330, Thailand.

Received for publication. November 1, 1994.

ธีระ วัชรปรีชาพันธ์, บุญชัย เอื้อไพโรจน์กิจ, เยื่อน ดันนิรันดร, ธีระพงศ์ เจริญวิทย์, สุจิต เฝ้าสวัสดิ์. การวินิจฉัย ไฮดรอปส์ ฟีตัลลิส ก่อนคลอดด้วยคลื่นเสียงความถี่สูงในโรงพยาบาลจุฬาลงกรณ์. จุฬาลงกรณ์เวชสาร 2537 พฤศจิกายน; 38(11): 667-677

วัตถุประสงค์	เพื่อประเมินสาเหตุของทารกในครรภ์ที่เป็น <i>hydrops fetalis</i> และ จำแนกชนิดของ <i>hydrops</i> โดยการตรวจด้วยคลื่นเสียงความถี่สูง
รูปแบบการวิจัย	การศึกษาเชิงพรรณนาชนิดย้อนไปข้างหน้า
ผลการวิจัย	ได้ทำการตรวจทารกในครรภ์ที่เป็น <i>hydrops fetalis</i> จำนวน 20 ราย ใน รพ. จุฬาลงกรณ์ตั้งแต่วันที่ 1 กันยายน 2536 ถึง 31 กรกฎาคม 2537 ในจำนวนนี้ 3 รายเคยมีประวัติตั้งครรภ์ <i>hydrops</i> ในครรภ์ก่อน พบว่าสาเหตุของ <i>hydrops</i> ที่พบบ่อยที่สุดเรียงตามลำดับดังนี้คือ <i>homozygous alpha-thalassemia</i> พบร้อยละ 35, การติดเชื้อพบร้อยละ 20, <i>cystic hygroma</i> พบร้อยละ 15 และความผิดปกติทางรูปร่างของหัวใจแต่กำเนิด ร้อยละ 10 พบทารก <i>hydrops</i> 1 รายที่เกิดจาก <i>immune hydrops fetalis (Rh isoimmunization)</i> การตั้งครรภ์ <i>hydrops</i> ทำให้มารดามีภาวะแทรกซ้อนสูงขึ้นได้แก่ ความดันโลหิตสูงขณะตั้งครรภ์, ภาวะช็อค, ครรภ์แฝดน้ำและคลอดก่อนกำหนด เป็นต้น การตรวจคลื่นเสียงความถี่สูงช่วยบอกถึงสาเหตุที่ช่วยให้เกิด <i>hydrops fetalis</i> ได้ เช่น <i>cystic hygroma</i> , <i>structural heart defect</i> เป็นต้น ในทารก <i>hydrops</i> ที่เกิดเกี่ยวเนื่องกับภาวะช็อค มักพบรกมีขนาดใหญ่ ส่วนทารก <i>hydrops</i> ที่ไม่เกี่ยวเนื่องกับภาวะช็อคมักมี <i>pleural effusion</i> หรือมีวุ้นในมดลูก
สรุป	การตรวจด้วยคลื่นเสียงความถี่สูงมีบทบาทสำคัญในการจำแนกชนิด, ประเมินสาเหตุ, สภาวะของโรค, พยากรณ์โรคและการรักษาทารกในครรภ์

Hydrops fetalis can be classified according to immune and non-immune causes. The manifestations of hydrops are heterogeneous and vary somewhat depending on the underlying etiology of the disorder. Ultrasound can easily document the features of hydrops (Fig.1) which include subcutaneous edema (defined as skin thickness greater than 5 mm.), ascites, pericardial effusions, pleural effusions and thickened placenta (>6 cm). Polyhydramnios and oligohydramnios are also reported with hydrops.⁽¹⁾ To diagnose hydrops fetalis ultrasonically, the fetuses should have skin edema and an effusion in at least one serous cavity, or two serous effusions without skin edema.⁽²⁾

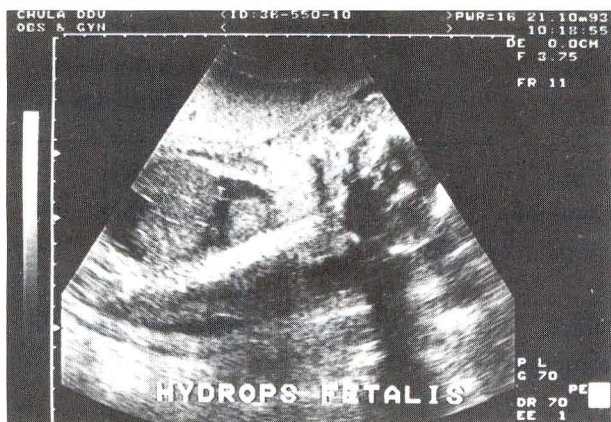

Figure 1. Sagittal view of fetal hydrops showing skin edema, ascites and pleural effusions.

Various abnormalities have been associated with the condition, including maternal and fetal anemia, cardiac abnormalities and arrhythmias, chromosome abnormalities, congenital infections and alpha-thalassemia.⁽³⁾ The clinical outcome and management can be predicted only if the correct etiology is identified. Complications of pregnancy associated with hydrops fetalis include hydramnios, preeclampsia, premature labor, etc.

We reviewed our sonographic and clinical data from 20 cases observed in our department in which the sonographic appearance was helpful in determining the etiology of the hydrops. Our suggestions are for obstetric investigation of fetuses with the disorder.

Materials and methods

From September 1, 1993 to July 31, 1994, 20 consecutive fetuses with hydrops fetalis underwent sonography using an Aloka SSD-2000 (Aloka, Tokyo, Japan) with a 3.5 MHz, sector transducer and a 3.5 MHz. pulsed and color Doppler ultrasonogram. For the 20 patients, the examinations of 11 took place at our hospital, and the other 9 patients were referred for investigation from other hospitals.

All cases were evaluated retrospectively. Fetal head edema was assessed at the posterior parietal level, and placental thickness was measured at the mid-placenta at right angles to the placental plane. Polyhydramnios and oligohydramnios were assessed by amniotic fluid index (AFI) as described by Phelan.⁽⁴⁾ In some of the examined cases, blood velocities were also recorded from the umbilical artery & vein, inferior vena cava and the atrioventricular (AV) valve (to search for AV insufficiency jets).

In addition to comprehensive ultrasound scanning of the fetus and placenta, the remaining work-up included maternal blood for complete blood count with differential and red blood cell indices, Acid-elusion test, ABO type and rhesus antigen status, indirect Coombs' test, titers for TORCH screen, serologic test for syphilis, OGTT, Hemoglobin (Hb) electrophoresis and G-6PD deficiency screen. Amniotic fluid was obtained

for fetal karyotype when appropriate. Percutaneous umbilical blood sampling was performed for rapid fetal karyotype Hb chain analysis, serum albumin, liver function tests (LFT), and fetal plasma analysis for specific IgM for TORCH screening and fetal blood gases.

When the evaluation was complete, the patients were counseled regarding the prognosis and offered the therapeutic options. Outcomes were evaluated at the review of newborn records, autopsy or clinical evaluation.

Statistics

The two-tailed Fisher exact test was used to compare parametric variables between groups with a significance level at $p < 0.05$.

Results

Table 1 presents the fetal age at presentation, and sonographic, clinical and pathologic data regarding the 20 cases with hydrops fetalis. The mean maternal age was 29.92 years (range 16-38 years). Three patients had previously delivered a hydropic baby (alpha-thalassemia)

Table 1. Fetal hydrops diagnosed by ultrasound.

Category	Case	Maternal age (yr.)	Fetal age (wk.)	Sonographic evidence	Outcome	Etiology & associated findings
Immune	1	29	24	ascites, edema, thick placenta, hepatomegaly, cardiomegaly, pericardial eff.	FDIU	Rh isoimmunization
Nonimmune						
Hematologic	2	30	22	ascites, edema, thick placenta, hepatomegaly, pleural eff.	TAB	alpha-thalassemia
	3	33	28	ascites, edema, thick placenta, hepatomegaly, cardiomegaly, pericardial eff., pleural eff., dilated UV.	TAB	alpha-thalassemia (recurrent hydrops.)
	4	30	32	ascites, thick-placenta, cardiomegaly, pericardial eff., pleural eff., oligohydramnios, dilated UV.	Still birth	alpha-thalassemia (recurrent hydrops)
	5	27	28	ascites, edema, thick placenta, hepatomegaly, oligohydramnios, dilated UV.	TAB	alpha-thalassemia
	6	27	33	ascites, edema, thick placenta, hepatomegaly, cardiomegaly, oligohydramnios	TAB	alpha-thalassmia
	7	24	29	ascites, edema, thick placenta, hepatomegaly, pleural eff., oligohydramnios, dilated UV.	Still birth	alpha-thalassemia severe preeclampsia, anemia

	8	38	28	ascites, edema, thick placenta, hepatomegaly, pleural eff., oligohydramnios, dilated UV, cardiomegaly, pericardial eff.	TAB	alpha-thalassemia
Maternal infection	9	35	26	ascites, edema, pleural eff., bradyarrhythmia	Still birth	Toxoplasmosis
	10	34	35	ascites, edema, pleural eff., polyhydramnios	Still birth	Toxoplasmosis
	11	16	38	ascites, pleural eff., polyhydramnios	C/S (Breech & PROM) 2500 g. Living child	VDRL 1 st visit (27 wk):Neg (38 wk):1:32 FTA-ABS:Reactive & IgM:Reactive
Cystic hygroma	12	25	36	ascites, hydrocele pleural eff.	Living child	Coxsackie B virus Myocarditis
	13	21	26	Marked edema, pleural eff., ascites	TAB	Chromosome :46,XY
	14	32	16	Marked edema, pleural eff., ascites	TAB	Chromosome:failed culture
Cardiac	15	32	18	Marked edema, pleural eff, ascites, thick placenta	TAB	Chromosome:45,XO
	16	20	38	ascites, cardiomegaly, pericardial eff., pleural eff., tricuspid regur.	NL 2330 g. Neonatal death (aspiration)	Common atrium Chromosome :46, XY
	17	33	38	ascites, cardiomegaly, pericardial eff., pleural eff., tricuspid regur. bradycardia	Still birth 1700 g.	Large VSD, DM, Mild preeclampsia
Idiopathic	18	35	29	ascites, edema, pleural eff., polyhydramnios	Still birth	
	19	28	32	ascites, edema, pleural eff., polyhydramnios	Neonatal death	Placenta previa totalis
	20	30	34	ascites, edema, pericardial eff., polyhydramnios	Neonatal death	

TAB = therapeutic abortion
C/S = cesarean section
eff. = effusion
FDIU = fetal death in utero

UV = umbilical vein
NL = normal labour
regur = regurgitation

Table 2. Indication for sonogram.

Indication	Number
1. Referred for evaluation	9
2. Decreased fetal movement	2
3. Large for date	2
4. Preeclampsia	2
5. Preterm labour	2
6. Others	3

Table 3. Distribution of fetuses with Anemia-related and Non-anemia hydrops by selected ultrasound findings.

Ultrasound finding	Hydrops		P*
	Anemia (N=8)	Non-anemia (N=12)	
Thick placenta	8	1	0.0001
Dilated UV.	5	0	0.0036
Oligohydramnios	5	0	0.0036
Polyhydramnios	0	5	0.0547

*Two-tailed Fisher exact test.

Prenatal and postnatal investigations could establish a cause in 85% of the patients. The most common causes of hydrop fetalis in our study were homozygous alpha-thalassemia (35%), followed by infectious causes (20%), cystic hygroma (15%), and cardiac anomalies (10%). One case of Rh isoimmunization (immune hydrops fetalis) was detected. There were 3 idiopathic cases because neither ultrasound nor clinical evaluation revealed any etiology.

Ascites was observed in nearly all cases. Thirteen cases (65%) had pleural effusions, 17 cases (85%) had skin edema, and 7 cases (35%) had pericardial effusions. Nine cases (45%) demonstrated a thickened placenta, and 8 of these cases occurred in the anemia-related hydrops fetalis. These 9 cases also included all cases of alpha-thalassemia (7 cases) and the 1 Rh isoimmunization case. Polyhydramnios and oligohydramnios were present in 5 cases (25%) in each category.

The indications for sonographic examinations are shown in Table 2. Sonographic features in anemia-related hydrops and non-anemia-related bydrops are shown in Table 3.

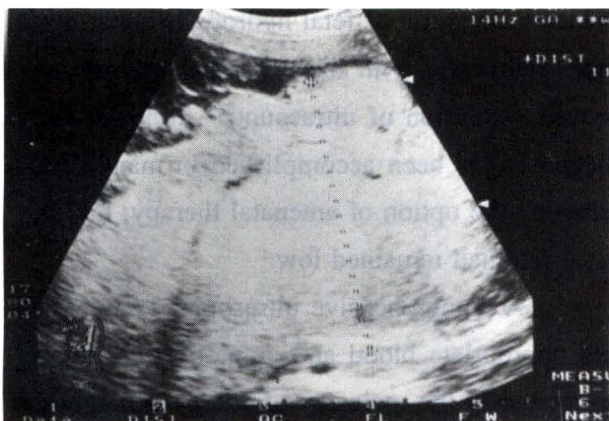


Figure 2. Longitudinal sonogram showing a thickened placenta.

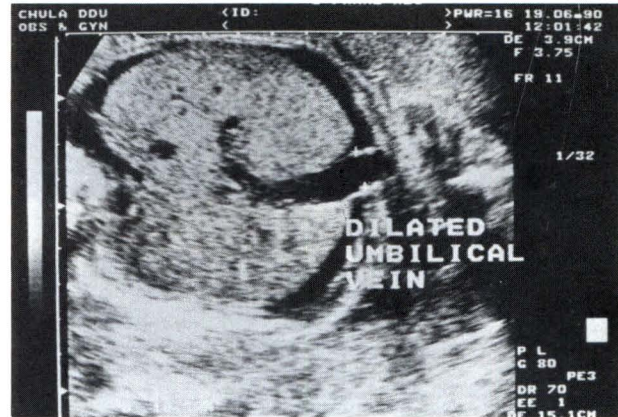

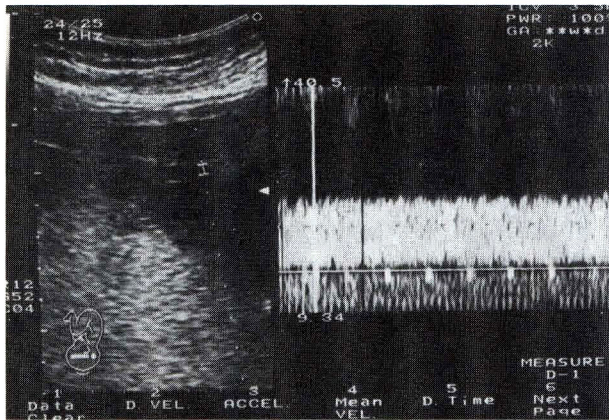
Figure 3. Transverse sonogram demonstrated a dilated umbilical vein.

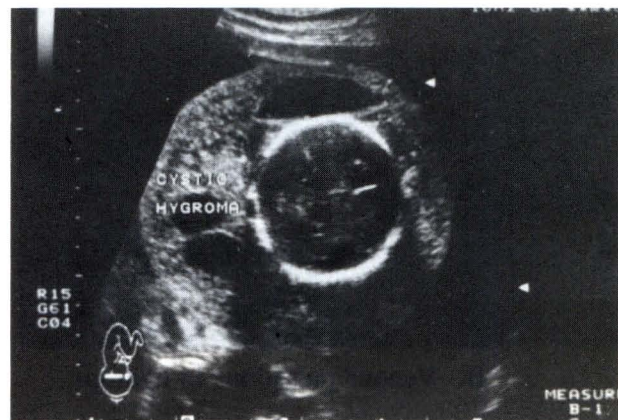

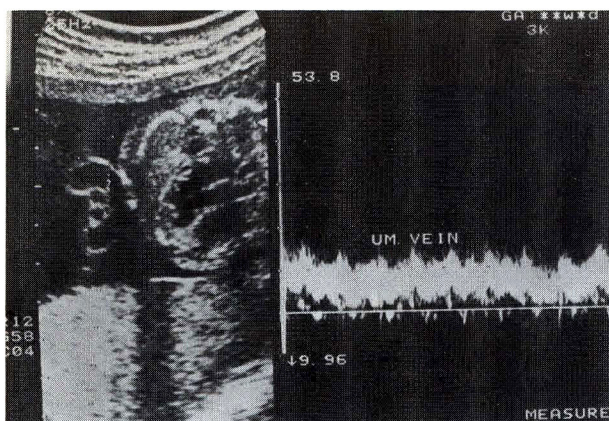
Figure 4. Transverse sonogram showing septated cystic hygroma.

A thickened placenta, dilated umbilical vein (UV) and oligohydramnios occurred significantly more frequently in anemia-associated hydrops (Figures 2 and 3). Fetuses not having anemia as the cause of hydrops most often exhibited pleural effusion or marked edema (more evident in cystic hygroma hydrops) (Figure 4.)

Umbilical venous pulsations (Figure 5), tricuspid & mitral valve regurgitation (Figure 6) and reversed flow in the inferior vena cava were also observed in some cases of severe hydrops fetalis.



A. Normal nonpulsating pattern.



B. Venous pulsations in hydrops.

Figure 5. Doppler wave form study of Umbilical vein.

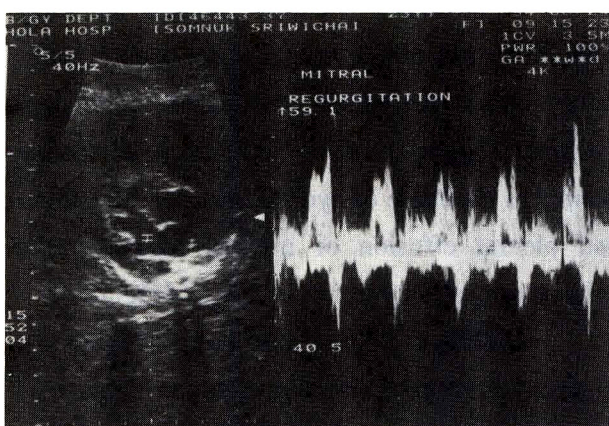


Figure 6. Mitral valve regurgitation.

Fetal transfusion was considered in the immune hydrops case, but because of a lack of Rh negative, group O, low titered blood and due to the severity of the fetal condition, the fetus died just before the operation began.

Maternal complications in association with hydrops fetalis were preeclampsia (2 severe preeclampsia, 1 mild preeclampsia), anemia,⁽²⁾ preterm delivery⁽²⁾ and placenta previa totalis.⁽¹⁾

Excluding the 10 electively aborted fetuses and the 2 alive fetuses, the remaining fetuses either were stillborn or died within a short time after delivery. The APGAR scores in the survivors were 1, 8 and (intubated), 8 at 1' and 5' minute respectively.

Determination of karyotype was attempted in 7 fetuses with non-immune hydrops fetalis. The results were that one case of cystic hygroma was abnormal (45,XO), 2 were culture failures (due to technical failure and aminocytes cell death collected after fetal death) and 4 had normal results.

Discussion

Hydrops fetalis is associated with a significant perinatal morbidity and mortality rate. The prenatal diagnosis of fetal hydrops is being made more frequently with the expanded use and improved resolution of ultrasound. Although early diagnosis has been accomplished in many cases, allowing the option of antenatal therapy, the survival rate had remained low.

A comprehensive ultrasound examination and appropriate blood and amniotic fluid testing are currently the mainstay of antenatal diagnosis. Prenatal fetal echocardiography and fetoplacental hemodynamic evaluation using Doppler flow wave

may also offer additional information in the evaluation of the hydropic fetuses.

Percutaneous ultrasound-guided fetal blood sampling has recently been added to aid in the diagnosis and management of patients with immune and non-immune hydrops. It allows a rapid diagnosis of chromosomal, hematologic, and metabolic disorders and is also helpful in cases of fetal infections because analysis of fetal plasma for specific IgM can give an indication of intrauterine infection of fetal tissue. A precise diagnosis is critical so that those fetuses that could benefit from in-utero therapy can be correctly identified, therefore, referral to a specialized center is recommended for complete evaluation.

Postmortem examinations of hydrops fetuses can explain the cause of the hydrops to confirm the clinical, biochemical, or pathologic findings.

We reported 20 cases of hydrops fetalis during the ten-month-period study. This number is high because nearly half (9 cases) of our cases were referred from other centers. Thorough prenatal and postnatal investigations established a cause in 85% of the patients. Most cases were due to fetal abnormalities, of which homozygous alpha-thalassemia constituted the largest part. Our finding correlates well with other reports from Asia,⁽⁵⁾ but differed from the reports among white populations^(1,2) which most cases were due to cardiac or chromosomal causes. In those fetuses, it is conceivable that a pathogenic mechanism is related to heart failure. Noninvasive physiologic methods that define congestive heart failure in the fetuses are not currently available, but Doppler ultrasonography can provide blood velocity correlation of abnormal physiology.⁽⁶⁾ Umbilical ve-

nous pressure has been found to be increased in fetuses with congestive heart failure and hydrops from fetal anemia during cordocentesis.⁽⁷⁾ Umbilical vein dilatation or pulsation and the reversed flow in the inferior vena cava have been reported as a correlation of central venous pressure change with asphyxia in animal studies,⁽⁸⁾ in human fetuses with alpha-thalassemic hydrops,⁽⁹⁾ and in fetuses with arrhythmia or the absence of end-diastolic blood velocity in the umbilical artery.⁽¹⁰⁾ The importance of regurgitant blood flow across one or both atrioventricular valves remains unclear,⁽⁶⁾ but it is reported to correlate with poor prognosis hydrops fetalis due to increased central venous pressure from congestive heart failure.⁽¹¹⁾

The increase in cardiac output in the anemic fetus may be accompanied by increased extramedullary hematopoiesis, liver enlargement and decreased colloid oncotic pressure.⁽¹²⁾

Decreased oncotic pressure, increased capillary permeability and lymphatic abnormalities may occur with chromosomal abnormalities, metabolic disorders and infections. Congenital infection may cause liver damage and hypoproteinemia as another possible mechanism for non-immune hydrops fetalis, and myocarditis in such a fetus could result in congestive heart failure.⁽¹⁾

Table 3 shows the sonographic features most strongly associated with either hydrops due to fetal anemia or non-anemia related causes. The fetuses with anemia were much more likely to exhibit a thickened placenta, hepatomegaly and dilated UV.^(6,7)

Fetuses affected with the homozygous form in which the primary Hb Bart's, are invariably hydropic at birth. Oligohydramnios and

fetal growth retardation have been noted in alpha-thalassemia with hydrops suggesting that the sublethal fetal hypoxemia of relatively long duration may sometime embarrass fetal development, growth and nutrition.⁽¹¹⁾ Couples at risk for a fetus with alpha-thalassemia hydrops can be identified prospectively by routine hemoglobinopathy screening. This involves hemoglobin electrophoresis and measurement of the RBC indices. In view of the hopeless prognosis for the fetus and the risk for the mother in alpha-thalassemia, most informed at-risk couples choose prenatal diagnosis and request termination of the pregnancy when an affected fetus is identified.

Cystic hygroma is a benign developmental lymphangioma which arises from congenital blockage of lymphatic drainage. Ultrasonically, cystic hygroma may be septated or non-septated cysts involving the neck. All cases of cystic hygroma in our study also showed marked edema, marked bilateral pleural effusion and ascites. Fetal chromosomal abnormalities are associated with the majority of cases. The outcome of septated cystic hygroma diagnosed at early gestational age is very poor.⁽¹²⁾

Cardiovascular abnormalities diagnosed in our report are structural cardiac defects, which included common atrium and large VSD with severe bradycardia. The prognosis in these fetuses is very poor.

Maternal causes are relatively rare and consist mainly of infection and diabetes. Among our cases there were two toxoplasmosis, one syphilis and one coxsackie B virus case. Both of toxoplasmosis cases were dead while the others are alive. In our syphilitic case, VDRL testing at the first visit (27 wks.) had been reported as negative.

There was no maternal clinical evidence of syphilis. Ultrasonography at 38-week-gestation revealed a hydropic fetus with polyhydramnios. A second maternal serologic sample yielded a positive titer of 1:32 on serum dilution, and the treponemal test result was positive. It may be possible for the syphilitic infection to be hidden by the prozone phenomenon.⁽¹³⁾ We further recommend that every woman should have VDRL testing with serum dilution, and it should be repeated in the third trimester.

It is also important to inform patients that there is a risk of recurrence. For immune hydrops fetalis, a high proportion of the fetus will be alloimmunized in the next pregnancy, but only 23% of the alloimmunized pregnancies would be expected to develop hydrops in utero.⁽¹⁴⁾ While non-immune hydrops generally has a low recurrent risk, it may vary from negligible to 25% in the case of specific autosomal recessive syndromes, such as thalassemia. Parents of hydropic infants should be counseled concerning the probable outcome and the risk of recurrence.

Conclusion

An analysis of 20 cases of hydrops fetalis in Chulalongkorn Hospital between September, 1993 and July, 1994 revealed that most of the cases were due to homozygous alpha-thalassemia. Maternal complications were increased in these fetuses. Sonography has a major role in the identification, evaluation and treatment of the hydropic fetus. A diagnostic protocol for investigation of hydrops fetalis is important for the clinical management of the patient and for subsequent genetic counseling, despite recent advances, the prognosis of the non-immune hydrops fetalis is generally poor.

References

1. Norton ME. Nonimmune hydrops fetalis. *Semin Perinatol* 1994; Aug. 18(4):321-32
2. Santolaya J, Alley D, Jaffe R, Warsaf SL. Antenatal classification of hydrops fetalis. *Obstet Gynecol* 1992 Feb; 79(2):256-9
3. Poeschmanu RP, Verheijen RHM, Van Dongen WJ. Differential diagnosis and causes of nonimmunological hydrops fetalis: a review. *Obstet Gynecol Surv* 1991 Apr; 46(4):223-31
4. Phelan JP, Ahn Mo, Smith CV, Rutherford SE, Anderson E. Amniotic fluid index measurements during pregnancy. *J Reprod Med* 1987 Aug; 32(8):601-4
5. Nakayama R, Yamada D, Steinmiller V, Hsia E, Hale RW. Hydrops fetalis secondary to Bart hemoglobinopathy. *Obstet Gynecol* 1986 Feb; 67(2):176-80
6. Gudmundsson S, Huhta JC, Wood DC, Tulzer G, Cohen AW, Weiner S. Venous doppler ultrasonography in the fetus with nonimmune hydrops. *Am J Obstet Gynecol* 1991 Jan; 164(1pt1) : 33-7
7. Weiner CP. Umbilical pressure measurement in the evaluation of nonimmune hydrops fetalis. *Am J Obstet Gynecol* 1993 Mar; 168(3pt1):817-23
8. Reuss ML, Fudolph AM, Dae MW. Phasic blood flow patterns in the superior and inferior venae cavae and umbilical vein of fetal sheep. *Am Obstet Gynecol* 1983 Jan; 145(1):70-8
9. Woo JS, Liang ST, Lo RL, Chan FY. Doppler blood flow velocity waveforms in alpha-thalassemia hydrops fetalis. *J Ultrasound Med* 1987 Dec; 6(12):679-84
10. Reed KL, Appleton CA, Anderson CF, Shenker L, Sahn Dj. Doppler studies of vena cava flows in human fetuses—insights into normal and abnormal cardiac physiology. *Circulation* 1990 Feb; 81(2):498-505
11. Tulzer G, Gudmundsson S. Doppler in non-immune hydrops fetalis. *Ultrasound Obstet Gynecol* 1994 July; 4:279-83
12. Santolaya-Forgas J, Warsaf-SL. Hydrops and associated anomalies, In: Brock DJH, Rodeck Ch, Ferguson-Smith MA, eds. *Prenatal Diagnosis and Screening*. Edinburgh; Churchill Livingstone, 1992:329-47
13. Berkowitz K, Baxi L, Fox HE. False-negative syphilis screening: the prozone phenomenon, nonimmune hydrops, and diagnosis of syphilis during pregnancy. *Am J Obstet Gynecol* 1990 Sep; 163(3):975-7
14. Bowman JM, Pollock JM. Amniotic fluid spectrophotometry and early delivery in the management of erythroblastosis fetalis. *Pediatrics* 1965 May; 35(5):815-35