

Gastrointestinal fistulae associated with a large abdominal wall defect : the usefulness of synthetic meshes : a case report.

Suvit Sriussadaporn* Wiset Tangchai*
Arun Rojanasakul* Sirachai Chindaruk*
Sukalaya Lerdlum** Boonchu Chitmaitree***
Vorasri Maungmingsuk*** Rajada Migasena***
Supranee Niruthisard*** Ruenreong Leelanukrom***
Ekachai Choedamphai*** Mattana Hanvanich****
Smonporn Bunyaratavej**** Somkai Sangwatanaroj****
Pogchit Pramuan*** Visist Dhitavat*

Sriussadaporn S, Tangchai W, Rojanasakul A, Chindaruk S, Lerdlum S, Chitmaitree B, Maungmingsuk V, Migasena R, Niruthisard S, Leelanukrom R, Choedamphai E, Hanvanich M, Bunyaratavej S, Sangwatanaroj S, Pramuan P, Dhitavat V. Gastrointestinal fistulae associated with a large abdominal wall defect : the usefulness of synthetic meshes : a case report. Chula Med J 1993 Jul; 37(7) : 469-476

A case of gastrointestinal fistulae associated with a large abdominal wall defect was reported. The abdominal wall integrity was temporarily maintained by the use of synthetic meshes. Both absorbable (Dexon) mesh and non-absorbable (Mersilene) mesh were used in this case. Recurrent fistulae developed after placement of the meshes but was surgically closed successfully. The patient recovered and was discharged home after 8 months and 4 days of hospitalization. Synthetic mesh is an invaluable conduit for maintaining abdominal wall integrity in a patient with a large abdominal wall defect when autogenous tissues are not available.

Key words : *Gastrointestinal fistula, Abdominal wall defect, Synthetic mesh.*

Reprint request : Sriussadaporn S, Department of Surgery, Faculty of Medicine, Chulalongkorn University, Bangkok 10330, Thailand.

Received for publication. April 1, 1993.

* Department of Surgery, Faculty of Medicine, Chulalongkorn University.

** Department of Radiology, Faculty of Medicine, Chulalongkorn University.

*** Department of Anesthesiology, Faculty of Medicine, Chulalongkorn University.

**** Department of Medicine, Faculty of Medicine, Chulalongkorn University.

สุวิทย์ ศรีอัมภากร, วิเศษ ต่างใจ, อรุณ โรจนสกุล, ศิรัชย์ จินดารักษ์, สุกัลยา เลิศล้ำ, บุญชู จิตไมตรี, วรศรี ม่วงมิ่งสุข, รัชฎา มิคะเสน, สุปราณี นริตติศาสน์, รื่นเริง สีลานุกรม, เอกชัย เจิดอำไพ, มัทนา หาญวนิชย์, สมนพร บุญยะรัตเวช, สมเกียรติ แสงวัฒนาโรจน์, ปกจิตรต์ ประมวญ, วิศิษฎ์ ฐิตวัฒน์. การปิดหน้าท้องชั่วคราวโดยใช้ตาข่ายสังเคราะห์ในผู้ป่วยที่มีความบกพร่องของผนังหน้าท้อง : รายงานผู้ป่วย 1 ราย. จุฬาลงกรณ์เวชสาร 2536 กรกฎาคม ; 37(7) : 469-476

รายงานผู้ป่วย 1 ราย ที่มีการรั่วของกระเพาะอาหารและลำไส้ ร่วมกับความบกพร่องของผนังหน้าท้องเนื่องจากการติดเชื้อ ผู้ป่วยรายนี้ได้รับการปิดหน้าท้องชั่วคราว โดยใช้ตาข่ายสังเคราะห์ซึ่งใช้ทั้งชนิดที่ละลายได้ (Polyglycolic acid, Dexon mesh) และชนิดที่ไม่ละลาย (Polypropylene, Mersilene mesh) แม้ว่าจะมีการรั่วของลำไส้เล็กเกิดขึ้นอีกเมื่อใช้ตาข่ายสังเคราะห์ปิดหน้าท้อง ในที่สุดรูรั่วก็ปิดลงหลังจากได้รับการผ่าตัดหลายครั้ง และผู้ป่วยกลับบ้านได้ รวมเวลาที่รักษาอยู่ในโรงพยาบาลจุฬาลงกรณ์ 8 เดือน 4 วัน ตาข่ายสังเคราะห์ช่วยในการปิดหน้าท้องชั่วคราว ในระหว่างที่รอให้ผู้ป่วยแข็งแรงขึ้นเพื่อรอรับการผ่าตัดแก้ไขความบกพร่องของผนังหน้าท้องต่อไป

Gastrointestinal fistulae associated with a large abdominal wall defect is one of the most difficult problems in surgery. The mortality rate of about 60% has been reported in the literatures.^(1,2) The management of these severely ill patients demands careful fluid, electrolytes and cardiovascular monitoring, good nutritional support, meticulous wound care and aggressive infection control, all of which require a great deal of co-operation between the involved nurses, physicians, anesthesiologists and surgeons. The following is a case report of gastrointestinal fistulae associated with a large abdominal wall defect in whom the abdominal wall defect was temporarily supported by synthetic meshes. He survived and was discharged home after a tremendous effort of the medical team.

Case presentation

A 20 year-old male patient was transferred to Chulalongkorn Hospital in a severe septicemic condition. He had been run over by a truck in a motor vehicle accident one month prior to this admission. After the accident, he was brought to a rural hospital in profound shock. The initial resuscitation included cardiopulmonary resuscitation. An emergency exploratory laparotomy was undertaken,

the operative findings were as follows : 1) blood in the peritoneal cavity of about 2,500 ml 2) a severe splenic injury 3) a ruptured duodenum. Splenectomy, duodenal repair and pyloric exclusion with a gastrojejunostomy were performed. He received 20 units of blood transfusion and several litres of colloid and crystalloid solutions during the operation. He had a turbulent post-operative course and underwent another 3 exploratory laparotomies with multiple small bowel resections and anastomoses and was eventually referred to us on 25th May 1992.

Upon initial physical examination at Chulalongkorn Hospital, he looked critically ill with deep jaundice. His temperature was 38.8⁰C, pulse 120/min, blood pressure 110/70 mmHg. He had been intubated and was on a mechanical ventilator owing to his respiratory insufficiency since the accident. There was a large abdominal wound with the stomach, transverse colon and small bowel forming the floor of the wound (Fig. 1). Multiple fistulae around the previous gastrojejunostomy anastomosis and the small bowel were noted. Moderate skin erosion was found around the abdominal wound due to the excoriation of bile and intestinal content. The diagnosis at that time was multiple gastrointestinal fistulae with intra-abdominal sepsis.

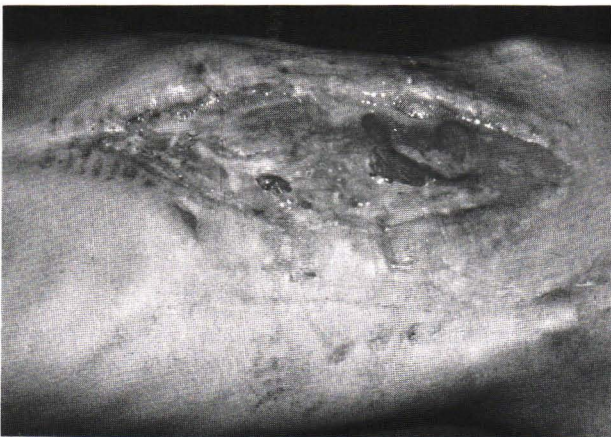

Figure 1. Appearance of abdominal wound at initial admission at Chulalongkorn Hospital.

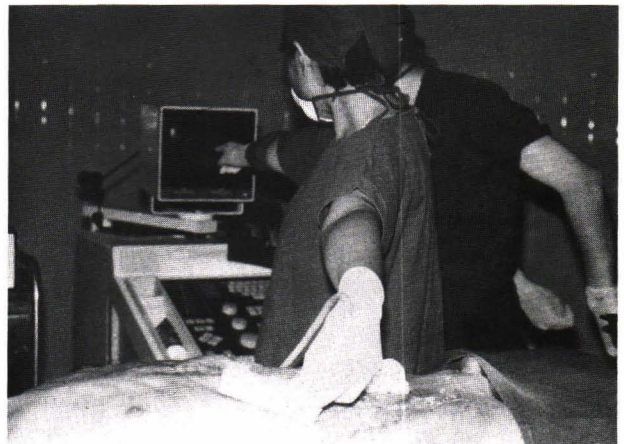

Figure 2. Ultrasonography was done in the operating room before starting the first operation.

After correction of fluid and electrolytes imbalance, the first exploratory laparotomy at Chulalongkorn Hospital was carried out on 27th May 1992. Before the operation, an ultrasound was performed on the operating table to search for intra-abdominal abscesses and collections (Fig. 2). At the operation, the partially disrupted gastrojejunostomy anastomosis was disconnected and the gastrotomy was closed. Adhesions of the small bowel were carefully dissected, the procedure was extremely difficult. When the whole small bowel was clear from previous adhesions, a segment of small bowel containing multiple fistulae was resected and reconstructed with an end to end anastomosis. All the intra-abdominal collections were removed and drained. The hematoma in the

medial segment of the left lobe of the liver which was initially missed and was only detected by ultrasonography was evacuated and drained. The infected abdominal wall was debrided until the healthy tissue was uncovered. At the end of the operation, it was found that the abdominal wall defect was too large to be closed by fascia to fascia or skin to skin methods, so a polyglycolic acid (Dexon) mesh was used to maintain the abdominal wall integrity. The Dexon mesh was sutured to the abdominal fascia (Fig. 3,4). The wound was dressed with a bulky gauze dressing and the entire wound was covered with a plastic drape to prevent excessive loss of fluid from the abdominal cavity. The patient tolerated the operation well.

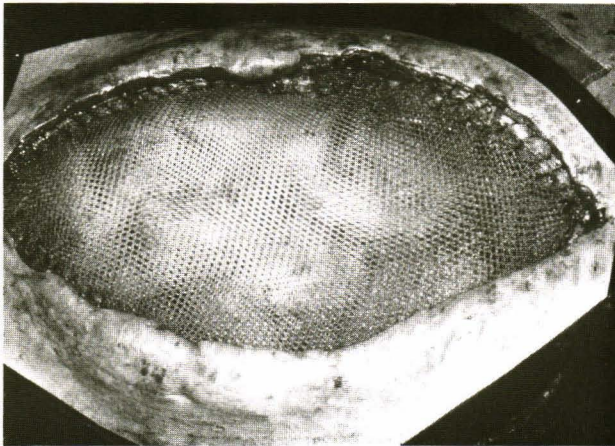


Figure 3. Appearance of wound after Dexon mesh placement.

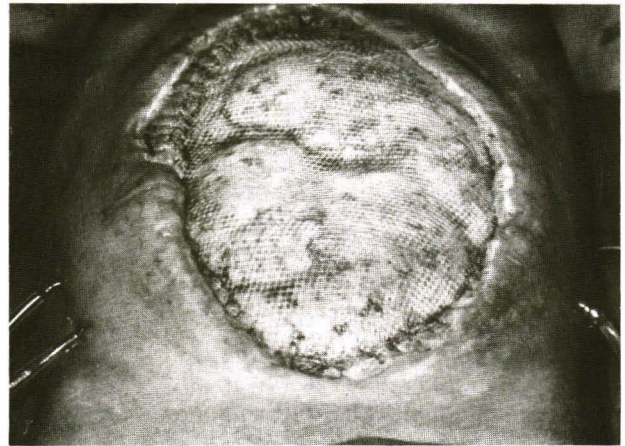

Figure 4. Granulating tissue rapidly covering the Dexon mesh (1 month).

One month later, while the patient was gradually recovering, a new small bowel fistula occurred (Fig. 5,6). He was brought to the operating room again. It was found that there was no longer any strength to the Dexon mesh, hence the mesh was removed. The small bowel fistula was identified and closed and the abdominal wall integrity was maintained by two layers of synthetic meshes. The inner layer was a Dexon mesh and the outer layer was a polypropylene (Mersilene) mesh which was placed to maintain strength of the abdominal wall. The Dexon mesh

was placed underneath the Mersilene mesh to prevent direct contact of abdominal viscera to the rigid non-absorbable Mersilene mesh (Fig. 7,8). His post-operative course was complicated by acute renal failure and congestive heart failure, both of which recovered after intensive medical therapy. Until this moment, his nutrition was mainly supported by parenteral route. However enteric feeding was gradually increased when the fistula was no longer observed. The wound decreased in size with time and wrinkling of the synthetic meshes were noted (Fig. 9, 10)

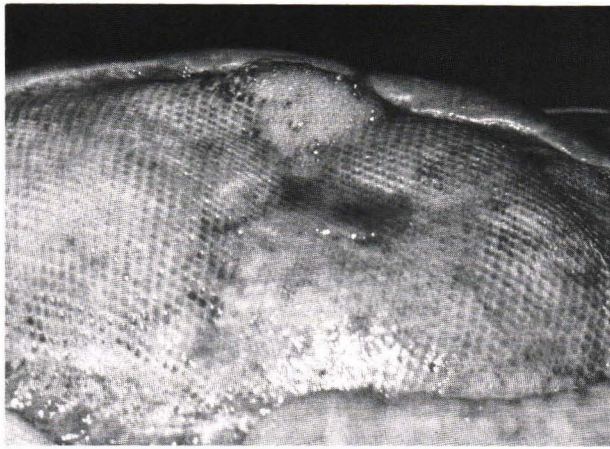


Figure 5. Spontaneous small bowel fistula occurred while the patient was recovering.

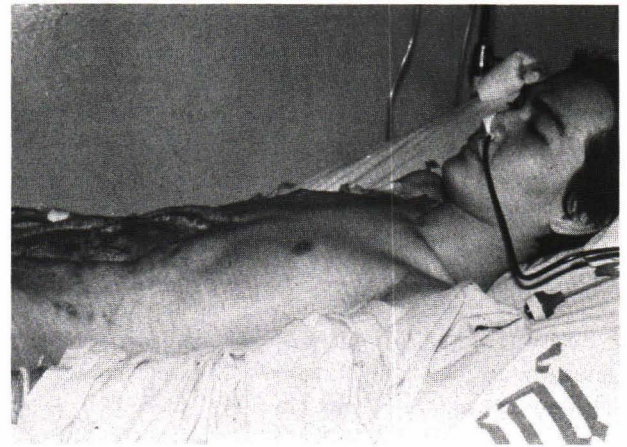

Figure 6. Sad and desperate feeling of the patient when the fistula recurred.

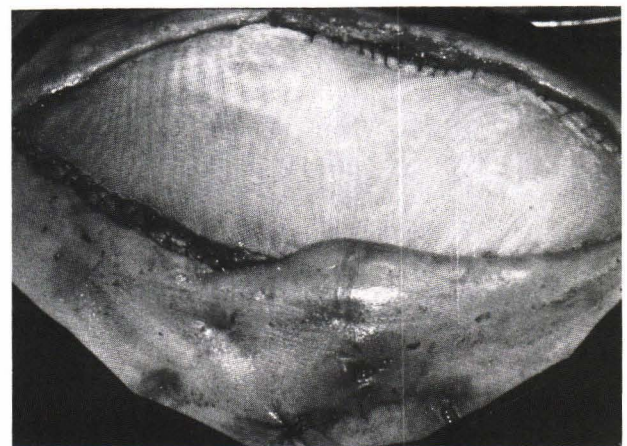
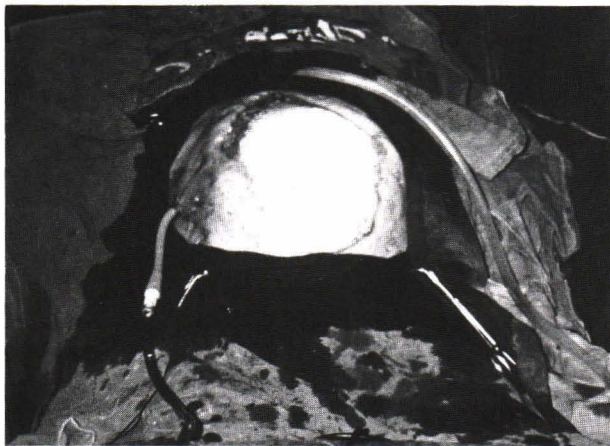


Figure 7 and 8. Appearance of abdominal wound after placement of Dexon and Mersilene meshes. The outer layer is a Mersilene mesh.

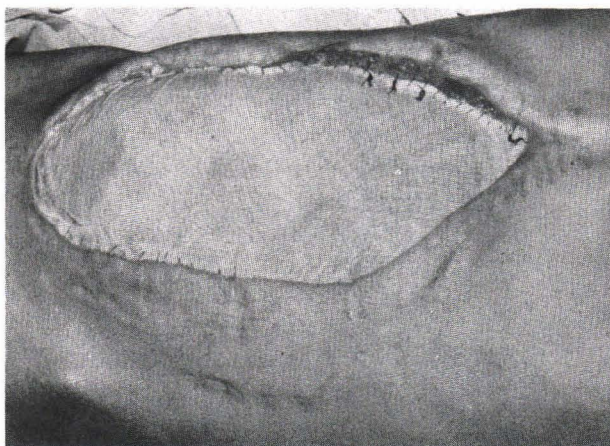


Figure 9. Wound appearance (1 month)

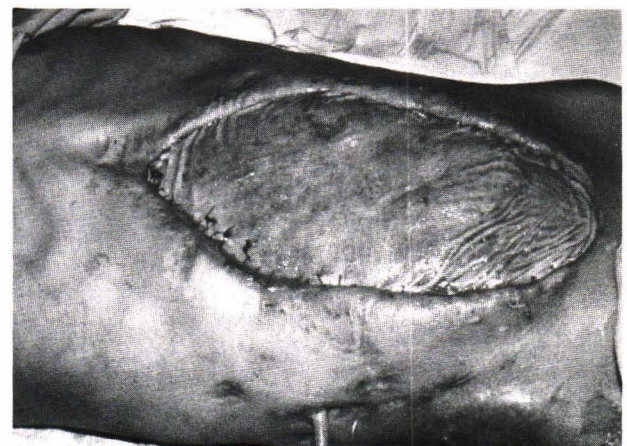


Figure 10. Wound appearance (2 months), wrinkling of the mesh is noted.

Four months later, while the meshes were covered with healthy granulation tissues and the patient was dramatically improving because of the better nutritional status and the resolution of intraabdominal sepsis, a new small bowel fistula took place. This was thought to be due to the exposure of the small bowel to the wrinkled Mersilene mesh (Fig. 11). After careful evaluation, surgical closure of the fistula was planned. The last operation was performed on 3rd December 1992. All the meshes and the granulating tissues were removed and the small bowel fistula was closed. At this time, his condition was much improved and we thought that he had enough abdominal skin and subcutaneous tissues to cover the abdominal wall

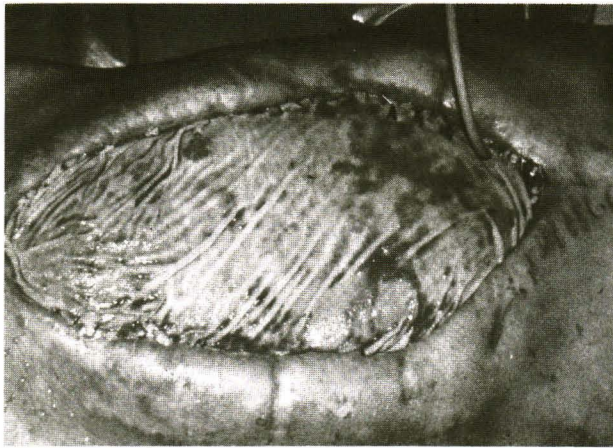


Figure 11. Wound appearance at 4 months (before the final fistula recurred). Note the granulating tissue growing from underneath the mesh and markedly wrinkling of the mesh.

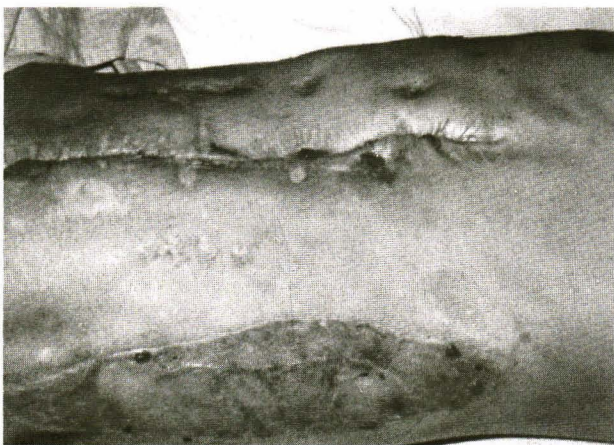

Figure 13. Wound appearance 2 months after final operation.

defect. This was accomplished by mobilization of skin and subcutaneous tissues from both sides of the wound after bilateral vertical incisions at the anterior axillary lines were made. The mobilized skin and subcutaneous tissues were sutured together at the midline of the abdomen, both new lateral abdominal raw surfaces were covered with split thickness skin grafts (Fig. 12). The post-operative course was uneventful with good wound healing (Fig. 13). He was discharged home two months later (Fig. 14). The hospital stay was 8 months and 4 days. A ventral hernia is expected and abdominal wall reconstruction may be needed some time later.

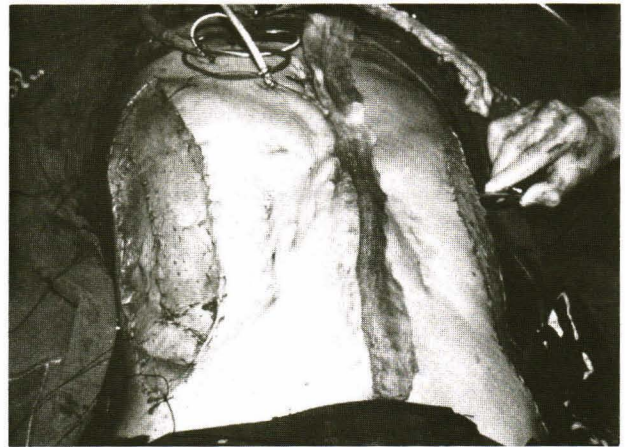


Figure 12. Skin and subcutaneous tissue were mobilized from both sides of the abdominal wall and sutured together. The donor sites were covered with split thickness skin grafts.

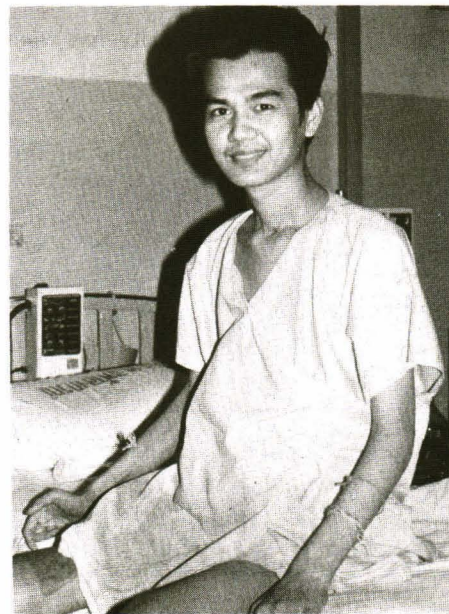


Figure 14. A happy young man before returning home.

Discussion

A large abdominal wall defect usually results from wound sepsis. It is frequently associated with intestinal fistulae and intra-abdominal collections which worsen the situation. Forceful closure of the abdominal wall after fistula control and drainage of intra-abdominal collections is usually impossible or may further damage the abdominal wall owing to tissue necrosis, wound sepsis, and fascial dehiscence.⁽³⁻⁵⁾

Synthetic mesh is invaluable in keeping the abdominal integrity in this situation. Temporary or permanent abdominal wall closure by synthetic mesh is a simple operation and avoids more extensive operative procedures such as local or remote myocutaneous flaps.⁽⁶⁾ Furthermore, most patients with large abdominal wall defects are usually in critical conditions and have limited reserve, synthetic meshes give them a chance to recover and become strong enough for subsequent abdominal wall reconstruction.

Absorbable mesh had been reported with a satisfactory outcome in the closure of a large abdominal wall defect.⁽⁷⁾ The advantages of absorbable mesh are that it can be used safely in contaminated field and need not be removed because it will not remain as an infected foreign body in the wound. The disadvantage is that it loses strength soon after placement, so the abdomen should be externally supported by an abdominal binder during the recovery phase and ventral hernia is inevitable.^(7,8) Non-absorbable mesh has also been reported to provide acceptable results.⁽⁹⁻¹¹⁾ The advantage of non-absorbable mesh is that it provides good strength and may be used as a permanent material with low risk of ventral hernia. The disadvantages are infection, extrusion, and occurrence of enteric fistula.^(3,9)

We had utilized both types of synthetic materials in this case. Although all the meshes were removed at the final operation, they had provided a satisfactory coverage of abdominal viscera while the patient was recovering. The fistulae formation after synthetic mesh placement occurred both with absorbable mesh and combined absorbable and non-absorbable meshes, however, they were successfully closed surgically without too much difficulty due to the improvement in the patient's condition.

Most patients with multiple gastrointestinal fistulae and a large abdominal wall defect will die from nutritional depletion, severe sepsis and multi-system organ failure.^(1,2) Nutritional support in this case report was provided by parenteral route only in the early phase of hospitalization and was gradually replaced by enteric route when the fistulae had been closed. The acute renal failure in this patients was thought to be due to the toxic effect of the aminoglycosides, the renal function returned to normal after cessation of this nephrotoxic drug. Cardiomyopathy from both nutritional depletion and sepsis was the possible

cause of congestive heart failure in this patient. The cardiac function improved after diuretic therapy, digitalization and nutritional support including vitamin B1 supplementation.

We would like to emphasize the usefulness of synthetic mesh in maintaining abdominal wall integrity in desperate situations when there are no available autogenous tissues to cover the abdominal wall defect. The synthetic mesh temporarily or permanently supports the abdominal wall while the patient is recovering until he is strong enough for further abdominal wall reconstruction.

Acknowledgements

We would like to thank all the attending medical teams which included nurses, physiotherapists, residents and staff of the Departments of Anesthesiology, Medicine, Radiology and Surgery of Chulalongkorn Hospital for their great contributions and effort in taking care of this patient.

References

1. Sitges-Serra J, Jaurieta E, Sitge-Creus A. Management of postoperative enterocutaneous fistulas : the roles of parenteral nutrition and surgery. *Br J Surg* 1982 Mar; 69(3) : 147-50
2. Schein M, Decker GA. Gastrointestinal fistulas associated with large abdominal wall defects : experience with 43 patients. *Br J Surg* 1990 Jan; 77(1): 97-100
3. Voyles CR, Richardson JD, Bland KI, Tobin GR, Flint LM, Polk HC. Emergency abdominal wall reconstruction with polypropylene mesh short-term benefits versus long-term complications. *Ann Surg* 1981 Aug; 194(2) : 219-23
4. Mathes SJ, Stone HH. Acute traumatic losses of abdominal wall substance. *J Trauma* 1975 May; 15(5) : 386-90
5. Goris RJA. Ogilvie's method applied to infected wound disruption. *Arch Surg* 1980 Sep; 115(9) : 1103-7
6. Levy E, Palmer DL, Frileux P, Hannoun L, Nordlinger B, Turet E, Honiger J, Pare R. Septic necrosis of the midline wound in postoperative peritonitis. Successful management by debridement, myocutaneous advancement, and primary skin closure. *Ann Surg* 1988 Apr; 207(4) : 470-9
7. Dayton MT, Buchele BA, Shirazi SS, Hunt LB. Use of an absorbable mesh to repair contaminated abdominal-wall defects. *Arch Surg* 1986 Aug; 121(8) : 954-60

8. Tyrell J, Silberman H, Chandrasoma P, Niland J, Shull J. Absorbable versus permanent mesh in abdominal operations. *Surg Gynecol Obstet* 1986 Mar; 168(3) : 227-32
9. Stone HH, Fabian TC, Turkleson ML, Jurkiewicz MJ. Management of acute full-thickness losses of the abdominal wall. *Ann Surg* 1981 May; 193(5) : 612-8
10. Chan STF, Esufali ST. Extended indications for polypropylene mesh closure of the abdominal wall. *Br J Surg* 1986 Jan; 73(1) : 3-6
11. Bauer JJ, Salky BA, Gelernt IM, Kreel I. Repair of large abdominal wall defects with expanded polytetrafluoroethylene (PTFE). *Ann Surg* 1987 Dec; 206(6) : 765-9