

Abdominal Actinomycosis : report of two case.

Monchanok Suvichanvorasin* Vira Kasantikul*
Darunee Boonjunwetwat** Chalernporn Leewongcharoen***

Suvichanvorasin M, Kasantikul V, Boonjunwetwat D, Leewongcharoen C. Abdominal Actinomycosis : report of two case. Chula Med J 1990 Sep; 34(9) : 705-711

Two cases of abdominal actinomycosis are reported. Both patients presented with abdominal masses which were mistaken for malignancy on clinical ground. Pathologically the lesions consisted of dense fibrous connective tissue and granulation tissue mingled with abscesses. Identification of bacterial colonies was essential to establish the diagnosis.

Reprint request : Suvichanvorasin M, Department of Pathology, Faculty of Medicine, Bangkok 10330, Thailand.

Received for publication. May 19, 1990.

* Department of Pathology, Faculty of Medicine, Chulalongkorn University.

** Department of Radiology, Faculty of Medicine, Chulalongkorn University.

*** Department of Surgery, Somdet Mamorial Hospital, Chonburi.

มนชนก สุวิชาญวรสิน, วีระ กสานติกุล, ครุณี บุญยืนเวทวัฒน์, เจริญพร ลีวงศ์เจริญ, แอคติโนมัยโคซิสใน
ช่องท้อง : รายงานผู้ป่วย 2 ราย. จุฬาลงกรณ์เวชสาร 2533 กันยายน ; 34 (9) :

ผู้ป่วยโรคแอคติโนมัยโคซิสในช่องท้อง 2 ราย เป็นชายอายุ 35 ปี และเด็กหญิงอายุ 8 ปี มาพบแพทย์ด้วย
เรื่องก้อนในช่องท้อง การตรวจทางคลินิกและรังสีวิทยาไม่สามารถแยกโรคจากเนื้องอกชนิดร้ายได้ทั้ง 2 ราย จาก
การตรวจทางพยาธิวิทยาพบเป็นการอักเสบเรื้อรังสลับกับฝีหนอง ซึ่งประกอบด้วยเซลล์หนองและกลุ่มของแบคทีเรีย นอก
จากนี้ยังพบฝีในผนังลำไส้ โดยเฉพาะที่ไส้ติ่งทั้งสองราย ลักษณะดังกล่าวประกอบกับการพบเชื้อที่ fecalith ในผนัง
ไส้ติ่งของผู้ป่วยรายแรก ช่วยสนับสนุนว่าการติดเชื้อนี้เริ่มที่บริเวณไส้ติ่งแล้วลุกลามไปยังเยื่อแขวนและผนังลำไส้ส่วนอื่น
การติดเชื้อแอคติโนมัยโคซิสในช่องท้องจำเป็นต้องแยกจากมะเร็งในบริเวณเดียวกันเพื่อการรักษาที่เหมาะสมต่อไป.

Actinomycosis is an infectious disease caused by an anaerobic gram-positive bacteria.⁽¹⁾ The organism is capable of infecting every organ including the cervicofacial, abdominal, thoracic and pelvic regions.⁽²⁻⁴⁾ Clinically, primary abdominal actinomycosis may mimic any infectious or neoplastic diseases.^(3,5-7) We have encountered two cases of abdominal actinomycosis presenting as abdominal mass. Both patients made an excellent recovery by using specific antibiotics after pathological diagnosis of the disease.

Case Reports

Case 1.A 35-year-old man, who had been in good health, developed abdominal mass of one month duration in association with intermittent abdominal pain, at the left lower quadrant. Examination revealed an ill-defined tender mass at the suprapubic region. The heart and lungs were normal. Leukocyte count depicted 12,600 cells/mm³ with 74% neutrophil, 8% eosinophil and 18% lymphocyte. Ultrasonogram and barium enema disclosed solid soft tissue density at the lower abdomen (Fig 1). The clinical impression was leiomyosarcoma.

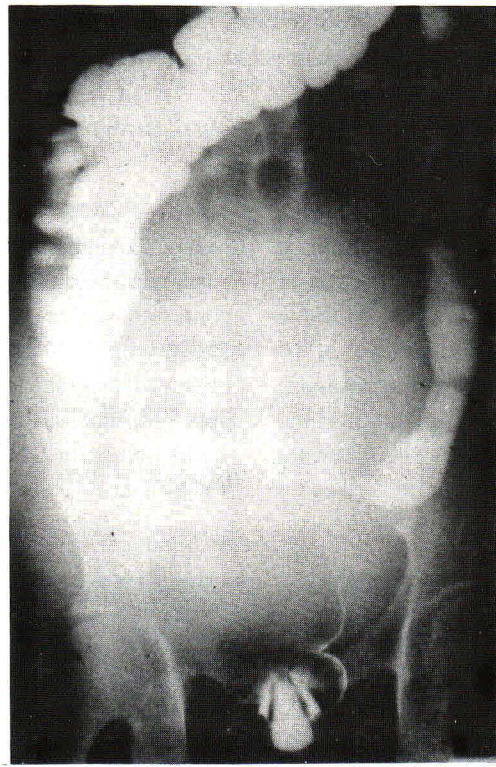


Figure 1. Barium enema demonstrated a soft tissue mass in the abdominal cavity with pressure effect on sigmoid colon (case 1).

At surgery the mass was located in the mesentery with focal adhesions involving the adjacent small and large intestine. The jejunoileal loop, the third part of duodenum, segment of cecum, appendix and sigmoid colon as well as the mesenteric mass were resected.

The specimen was fixed in 10% formalin. A

large, globular, firm mesenteric mass, 6 cm. in diameter was noted showing grayish white cut surface with scattering softened yellow map-like areas (Fig. 2A). The appendix showed thickened serosa and narrow lumen. A fecalith, 0.5 cm. in diameter, was found in the submucosa (Fig. 2B).

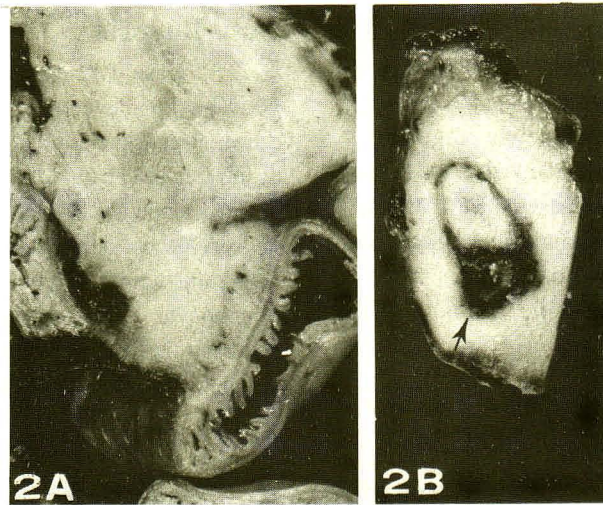


Figure 2. A. Cross-section of the mesenteric mass showing solid grayish white cut surface (case 1). Note the well preserved intestinal mucosa.
B. The thickened appendiceal wall with intramural fecalith (arrow)

Microscopically, the lesion was composed of dense fibrous connective tissue alternated with areas of abscesses and granulation tissue (Fig. 3A). Multiple microabscesses were present in the muscular layer of the small intestine, appendix and sigmoid colon. Furthermore, eosinophilic infiltration and sinus tract were noted in the appendiceal wall. Occasionally, clumps of organism were found within the abscesses, which were characterized by

round or oval basophilic masses with peripheral radiating eosinophilic clubs in routine stain (Fig. 3B). Each colony contained dense meshes of gram positive filamentous bacilli with frequent short branching. Beading was also observed in gram stain (Fig. 4A). The fecalith in the appendix was surrounded by similar organism which stained black in GMS (Fig. 4B), pink in PAS and was not acid-fast.

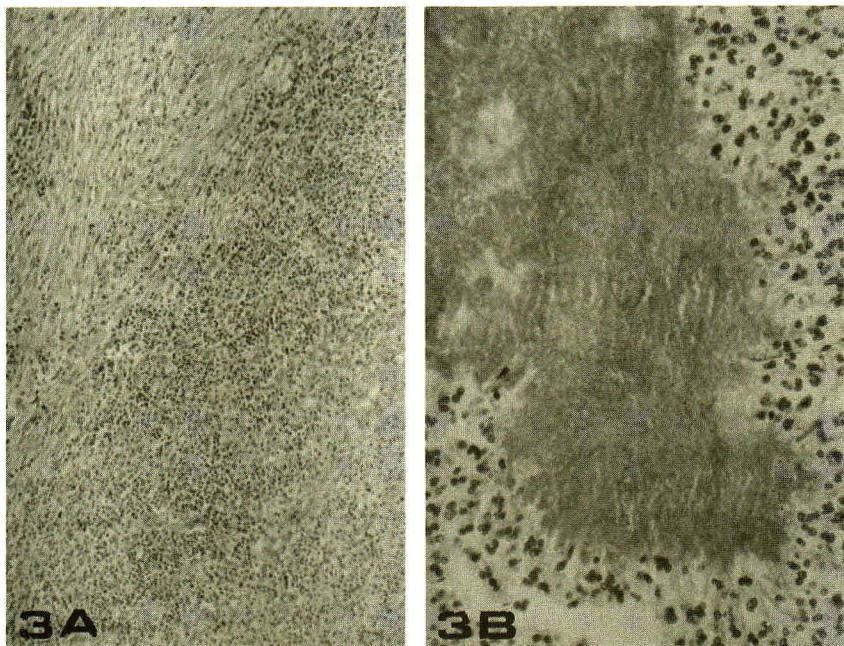


Figure 3. A. Case 1: Photomicrograph showing dense fibrosis and inflammatory cells. H & E \times 40.
B. Clump of bacteria in abscess. H & E \times 400.

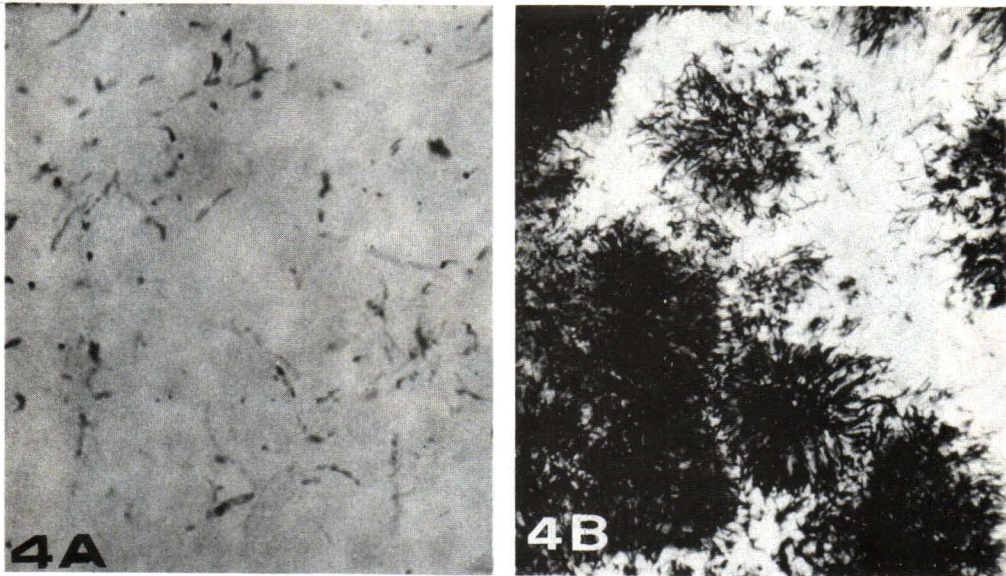


Figure 4. A. Photomicrograph of gram-positive branching filaments of bacteria. Gram $\times 1000$
B. Numerous delicate filaments were shown. GMS $\times 400$.

The post-operative course was complicated by partial gut obstruction and was relieved with conservative treatment. The patient received high dose of penicillin for three weeks and was in good condition when seen 2 weeks after therapy.

Case 2. An 8-year-old girl was admitted to Chulalongkorn Hospital because of a progressive enlarged abdominal mass, fever and pain for 2 weeks. Physical examination revealed a 7×8 cm. mass in the right lower

abdomen and a 3×3 cm. mass in the left. Laboratory data showed a hemoglobin of 11 gm% and leukocyte count of $22,500 \text{ cells/mm}^3$ with 65% neutrophil, 3% eosinophil and 28% lymphocyte. Barium enema, ultrasonogram and CT scan demonstrated a soft tissue mass at the ileocecal region causing irregular narrowing of the intestinal lumen. (Fig. 5,6) The lesion also involved the anterior abdominal wall. The mass was homogeneously enhanced in CT scan. Lymphoma was suspected clinically.

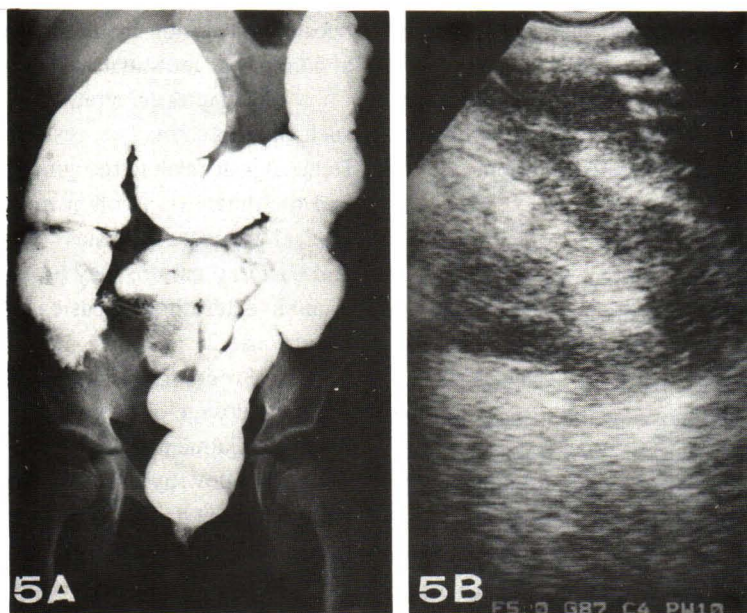


Figure 5. A. Case 2: Barium enema depicted soft tissue mass at the ileocecal area causing deformed cecum and irregular narrowing of terminal ileum.
B. Ultrasonogram disclosed low echoic area locating around intestinal loops in the right pelvic cavity.

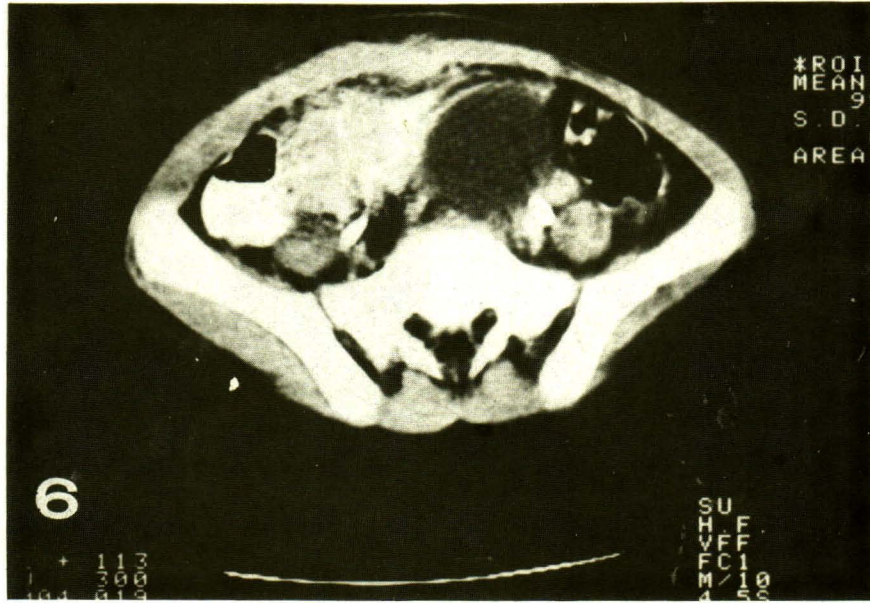


Figure 6. CT scan showed homogeneously enhanced soft tissue mass at the ileocecal area and narrowing of terminal ileal lumen, with extension to adjacent anterior abdominal wall (Case 2).

At surgery there were two invasive lesions with extensive necrosis adherent to the ileum, cecum and anterior abdominal wall. Multiple biopsies with appendectomy were performed. Pus cultures for bacteria, aerobic and anaerobic, and fungus yielded no growth. Microscopically, the biopsies from terminal ileum and abdominal wall showed abscess formation and granulation tissue with a clump of *Actinomyces*. The appendix exhibited intact mucosa with foci of intramural abscess. Foamy histiocytes, lymphocytes and plasma cells were found in the serosa and muscular layer.

Parenteral ampicillin and gentamicin were prescribed for 5 days followed by oral amoxicillin for 14 days. She was discharged in good condition.

Discussion

Generally, the lesion of actinomycosis is characterized by fibrotic scar mingled with abscesses as noted in the current examples.^(2,3,7) The finding of gram positive branching filaments within the abscess was essential to establish the diagnosis of the disease in our patients. It must be emphasized, however, that the presence of eosinophils and blood eosinophilia in case 1 is uncommon and has been rarely described⁽²⁾ Interestingly, most cases of abdominal actinomycosis including the present instances exhibit no mucosal involvement.^(5,7) While the mucosa is preserved, the organisms apparently destroy adjacent structures with direct spread to nearby organs such as liver, spleen,

abdominal wall and mesentery similar to our cases.^(7,8)

Little is known about the pathogenesis of the abdominal lesion.^(5,7,8) It should be noted that the infection often involves the ileocecal region. Some authors suggested that the lesion may arise primarily from the cecum and appendix.^(5,7) The presence of appendicitis in our cases and the findings of intramural fecalith with organism in case 1 are evidence to support this view.

Abdominal actinomycosis is important clinically because the lesion is frequently adherent either to the abdominal or intestinal wall. Moreover, barium enema, CT scan and ultrasonogram may not be able to distinguish such inflammatory process from neoplasm.^(5,9,10,11) Hence it is difficult to recognize this disease with certainty and the diagnosis is often mistaken for malignancy on clinical ground. Awareness of the disease, tissue biopsy and bacterial culture may prevent such an error as well as aid in determine the basic nature of the lesion as noted in our case 2.

Prognosis of the disease is usually excellent after adequate dosage of penicillin.^(2,7,12) The recommended medical treatment is high dose parenteral penicillin for 4 weeks follow by oral form for 3-6 months.^(2,4) Other antibiotics such as tetracycline, ampicillin, chloramphenicol, erythromycin, lincomycin and cephalosporin are alternatives.^(3,8) However, with radical excision of the mass, prolonged high dose penicillin is unnecessary as seen in both our cases.⁽¹²⁾ The combination of ampicillin, gentamicin and amoxicillin in case 2 proved to

be useful for this disease and has not been reported previously.

Acknowledgement

Dr. Vira Kasantikul is in receipt of fund from Chulalongkorn University, Faculty of Medicine-China Medical Board Development Fund.

References

1. Koneman EW, Allen SD, Dowell VR, Janda WM, Sommers HM, Winn WC. Color Atlas and Textbook of Diagnostic Microbiology 3rd ed. Philadelphia : J.B. Lippincott, 1988. 396-9
2. Brown JR. Human Actinomycosis: a study of 181 subjects. Human Pathol 1973 Sep; 4(3) : 319-30
3. Weese WC, Smith IM. A Study of 57 cases of actinomycosis over a 36-year period. A diagnostic "failure" with good prognosis after treatment. Arch Intern Med 1975 Dec; 135(12) : 1562-8
4. Stringer MD, Cameron AE. Abdominal actinomycosis : a forgotten disease? Br J Hosp Med 1987 Aug; 38(2) : 125-7
5. Wibulpolprasert B, Dhiensiri T, Sinavat P, Chartban-chachai V. Abdominal actinomycosis. J Med Assoc Thai 1988 Jul; 71(7) : 355-60
6. Thompson JR, Watts R, Thompson WC. Actinomycetoma masquerading as abdominal neoplasm. Dis Colon Rectum 1982 Jun; 25(4) : 368-70
7. Putman HC, Dockerty MB, Waugh JM. Abdominal actinomycosis: an analysis of 122 cases. Surgery 1950 Nov; 28(5) : 781-800
8. Berardi RS. Abdominal actinomycosis. Surg Gynecol Obstet 1979 Aug; 149(2) : 257-66
9. Shah HR, Williamson MR, Boyd CM, Balachandran S, Augtuaco TL, McConnell JR. CT findings in abdominal actinomycosis. J Comput Assist Tomogr 1987 May-Jun; 11(3) : 466-9
10. Harris LA, DeCosse JJ, Dannenberg A. Abdominal actinomycosis : Evaluation by computed tomography. Am J Gastroenterol 1989 Feb; 84(2) : 198-200
11. Fowler RC, Simpkins KC. Abdominal actinomycosis : a report of three cases. Clin Radiol 1983 May; (3) : 301-7
12. Wohlgemuth SD, Gaddy MC. Surgical implications of actinomycosis. South Med J 1986 Dec; 79(12) : 1574-8