

Exchange transfusion in green pit viper bite : a case report.

Chulee Mitrakul* Sirichai Limsuwan*
Ayut Dhamkrong-at* Punya Seksun*

Mitrakul C, Limsuwan S, Dhamkrong-at A, Seksun P. Exchange transfusion in green pit viper bite : a case report. Chula Med J 1989 Sep; 33(9) : 689-693

A 1 1/2 year old boy, bitten by a green pit viper, manifested severe hemostatic defects, as demonstrated clinically and by laboratory tests, and severe local effects. Despite the transfusion of packed red cells, fresh frozen plasma and whole blood, as well as intravenous antivenom, the patient's condition worsened, with hypertension also developing. The abnormalities, particularly the hemostatic defects, were corrected after the exchange transfusion with fresh whole blood, followed by intravenous platelet - concentrate and cryoprecipitate. The remission, however, lasted for only about 36 hours. The procedure therefore was repeated twice, at intervals of 48 and 43 hours.

When on the fifth day after the bite, the patient developed pulmonary hemorrhage and pulmonary infiltration with high fever, the third exchange transfusion was carried out. After that the hemostasis was consistently normal. Clinical abnormalities also gradually recovered, but only with antibiotics and supportive treatment. Since the local wound at the bite site became necrotic and required skin graft, the boy remained in the hospital for 31 days.

In the recorded case it was demonstrated that:

- 1) continuing absorption of the venom from the local wound may serve as a mechanism possibly responsible for the one-week period of hemostatic diathesis and the persistence of venom in the circulation, usually noted in the green pit viper bite and*
- 2) an exchange transfusion is an effective means to eradicate the green pit viper venom from the circulation, particularly in small children.*

Reprint request : Mitrakul C, Department of Pediatrics, Faculty of Medicine, Chulalongkorn University, Bangkok 10330, Thailand.

Received for publication. May 8, 1989.

**ชุดี มิตรกุล, ศิริรัช ลิมสุวรรณ, आयुคร์ม ธรรมครองอาคร์ม, ปัญญา เสกสรรคร์. การรักษาผู้ป่วยงูเขียวหางไหม้
กัคด้วยการเปลี่ยนถ่ายเลือด: รายงานผู้ป่วย 1 ราย. จุฬาลงกรณ์เวชสาร 2532 กันยายน: 33(9): 689-
693**

เด็กชายไทยอายุ 1 1/2 ปี ถูกงูเขียวหางไหม้กัด มีอาการรุนแรงมากทั้งการเปลี่ยนแปลงเฉพะที่ และภาวะ
เลือดออกง่ายที่แสดงออกด้วยอาการทางคลินิก และผลการทดสอบทางห้องปฏิบัติการ แม้ว่าผู้ป่วยจะ ได้รับการรักษา
โดยให้เลือด น้ำเหลือง เลือด และซีรัมแก่พิษงูเขียวหางไหม้เข้าทางหลอดเลือดแล้ว แต่อาการก็ยังเลวลง ทั้งเกิดมีความ
คันโลหิตสูงแทรกซ้อนขึ้นด้วย อย่างไรก็ตามเมื่อได้รับการรักษาด้วยการเปลี่ยนถ่ายเลือด (exchange transfusion)
ด้วยเลือดสด ตามด้วยให้ platelet concentrate และ cryoprecipitate ฉีกเข้าหลอดเลือด ผู้ป่วยสนองตอบดีมาก
โดยเฉพะความผิดปกติเกี่ยวกับภาวะเลือดออกง่ายได้กลับคืนเป็นปกติ แต่ปรากฏว่าชั่วระยะเวลาประมาณ 36
ชั่วโมงเท่านั้นผลผิดปกติก็เกิดขึ้นอีก ซึ่งต้องทำการเปลี่ยนถ่ายเลือดซ้ำอีกถึง 2 ครั้ง ในระยะเวลาห่างกันประมาณ 48
และ 43 ชั่วโมงตามลำดับ

ในวันที่ 5 หลังถูกงูกัด ได้ทำการเปลี่ยนถ่ายเลือดซ้ำเป็นครั้งที่ 3 หลังจากนั้นภาวะเลือดออกง่ายก็หายเป็น
ปกติและไม่กลับคืนมาอีก อาการอื่น ๆ ของผู้ป่วยก็ค่อย ๆ คืนสู่ปกติด้วยการให้ยาปฏิชีวนะ และรักษาตามอาการภายใน
เวลา 3 สัปดาห์ต่อมา เนื่องจากแผลงูกัดเกิดเนื้อเน่าทำให้แผลกว้าง จึงต้องปลูกผิวหนังใหม่ให้ด้วย ผู้ป่วยจึงอยู่โร
งพยาบาลรวมเวลาทั้งหมดนาน 31 วัน

สังเกตการณ์จากอาการและการดำเนินโรคของผู้ป่วยรายนี้ แสดงว่า:-

1. การค่อย ๆ ถูกขิมของพิษงูจากบริเวณแผลเข้าสู่กระแสเลือดเป็นกลไกหนึ่งที่ทำให้ผู้ป่วยถูกงูเขียว
หางไหม้กัคมีภาวะเลือดออกง่ายรวมทั้งมีพิษงูไหลเวียนอยู่ในกระแสเลือดเป็นระยะเวลานานประมาณ 1 สัปดาห์หลังถูกกัค
2. การเปลี่ยนถ่ายเลือดสามารถกำจัดพิษงูเขียวหางไหม้ออกจากร่างกายได้อย่างมีประสิทธิภาพ โดยเฉพาะ
ในเด็กเล็ก

Green pit viper venom normally has a mild effect on human hemostasis. Fatal effects have, however, occasionally been reported.⁽¹⁻³⁾ The hemostatic defects are hypofibrinogenemia, thrombocytopenia, and increased fibrinolysis, as well as vascular changes. The most specific means to manage snake bite patients is to rid them of the venom, along with other supportive measures. Specific antivenom serum is therefore generally recommended. The combination of prolonged whole blood clotting time and clinical bleedings are usually used as guides for the decision of the initial and repeated doses of antivenom in cases of hematotoxic snake bite. In small children, this routine may not be possible to follow, particularly in those who are in severe condition and complicated by systemic involvements. An exchange transfusion was chosen as another alternative for eradication of the venom in an infant in the following report.

Case Report

At 8.30 pm. on 10 November 1985, a 1 1/2 year - old Thai boy was bitten on his left foot by a green pit viper. Some blood oozed from the wound right after the bite. Soon afterward the foot became swollen and ecchymotic. Physical examination on admission, one hour after the bite, revealed temperature of 38.4°C, pulse rate 144/min, respiratory rate 28/min, body weight 12.5 kg and B.P. 80/40 mmHg. The affected foot was swollen and 3 fang-marks were observed on its dorsum. There was no blood oozing from the wound. The CBC showed Hct of 39% WBC 39,150/c.mm, adequate platelet, PMN 31%, L 68%, E 1%, A blood sample was noted to clot more easily than usual.

Ten hours later, they boy was discovered to be moderately pale and rather restless. Temperature was 37.8°C, pulse rate 176/min, respiration 60/min, B.P. 110/60 mmHg. Left lower extremity was cold, ecchymotic and swollen up to the inguinal level. Pulse of left dorsal pedis was not palpable. The CBC revealed Hct of 26%, WBC 15,800/c.mm, platelet 22,000/c.mm, APTT > 5' (control = 51.4"), PT > 5' (control = 15.5"), fibrinogen 6.75 mg/dl (control = 200 - 400 mg/dl). Altogether PRC 150 ml, FFP 120 ml, green pit viper - antivenom serum 40 ml and fresh whole blood 200 ml. were given during the 12th to 20th hour after the bite.

The boy remained restless and was semiconscious. Pulse rate was 140/min., B.P. 140/90 mmHg. A hemorrhagic blister developed around the bite wounds and the swelling extended up to the trunk. On 11 November 1983, at around 7.30 pm. (24 hours after the bite), exchange transfusion, using 1,900 ml fresh whole blood, was then performed. Three units of platelet - concentrate and 2 units of cryoprecipitate were added intravenously at the end of the procedure.

Twelve hours after the transfusion, his CBC showed Hct of 33%, WBC 11,400/c.mm, platelet 239,000/c.mm, reticulocyte 1.7%, APTT 50.4" (control = 49.8"), PT 23" (control = 15.4"), fibrinogen 290 mg/dl. The boy was alert but cried often. Temperature was 37.1°C, pulse rate 100/min, respiration 20/min, B.P. 140/100 mmHg. No overt bleeding was noted. Swelling crept up to the left hypochondrium. The blister ruptured spontaneously. After the transfusion the child did not void, 150 ml urine was obtained by catheterization.

Twenty four hours after the exchange transfusion, Hct was 32%, platelet 230,000/c.mm.

At 7.30 am. of 13 November, 36 hours after the exchange transfusion the patient was well and conscious. The wound of the ruptured blister became wider, and the swelling slightly increased. His pulse rate was 130/min, respiration 31/min, B.P. 140-160/90-100 mmHg, Hct 31%, APTT was > 5' (control = 52.8"), PT > 5' (control = 15.2") and fibrinogen 6.75 mg/dl.

Between 7.20 and 8.45 pm. of 13 November, 72 hours after the bite and 48 hours after the first transfusion, a second exchange transfusion using 950 ml fresh whole blood was carried out, and 3 bags of cryoprecipitate was intravenously added at the end of the process. Venous blood clotting time one hour later was 10'. The boy appeared alert. There was no signs of systemic bleeding. Eleven hours after the second transfusion, B.P. was 140-150/90-100 mmHg. Other vital signs were good. Necrotic area of the wound was slightly wider. Venous whole blood clotting time was 6 minutes.

On the fifth day of the bite, around 36 hours after the second exchange transfusion, the patient vomitted a small amount of fresh blood once. His temperature was 39.5°C, pulse rate 140/min, respiration 70-80/min, B.P. 150/100 mmHg. He appeared pale and lethargic but could open and close his eyes when asked. He had difficulty in breathing. Rhonchi and fine crepitation could be detected generally on both sides of the chest. The abdomen was moderately distended. The swelling remained the same but appeared more ecchymotic. The scrotum was also swollen. The CBC at this time showed Hct of 16.5% WBC 16,300/c.mm., platelet 10,000/c.mm, PMN 81%, L 19%. APTT was > 5' (control = 52.4"), PT > 5' (control = 16.2") and fibrinogen 69.7 mg/dl. At 3.20 pm. of November 15, a third exchange transfusion was done, about 43 hours after the second one, using 1,060 ml of fresh whole blood. This was again followed with platelet-concentrate and cryoprecipitate, 2 units each, intravenously.

Seven hours later, the Hct was 24%, WBC 18,800/c.mm, platelet 136,000/c.mm, retic 2.4%, PMN 60%, band 1%, L 32%, E 5%, M 2%, APTT 43.0" (control = 50.8"), PT 16.0" (control = 15.4") and

fibrinogen 591 mg/dl. His CBC and hemostatic tests then remained consistently in the normal ranges, (see figure).

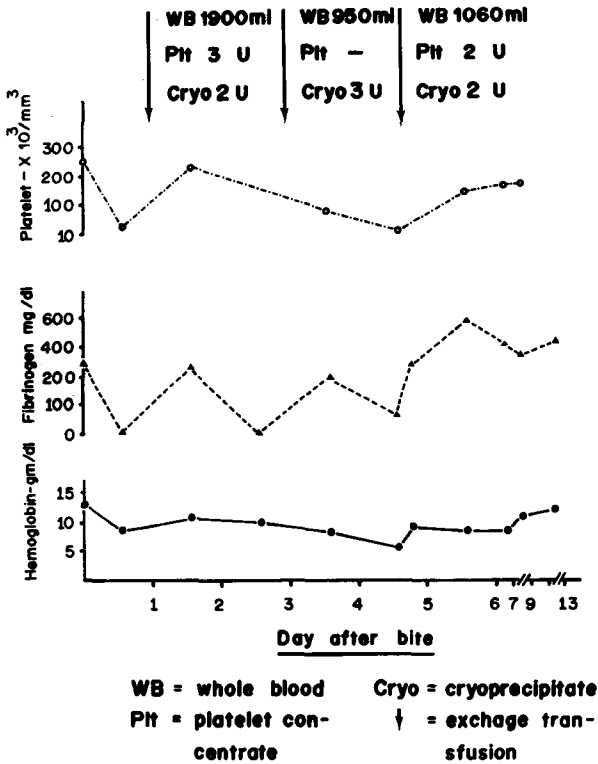


Figure 1. Effect of exchange transfusion on fibrinogen and platelet levels in a boy bitten by a green pit viper.

Chest x-ray film on November 15, just before the third exchange transfusion, showed normal cardiac shadow, alveolar infiltration of both lungs and right pleural effusion, pulmonary edema or hemorrhage. Repeated on November 16 and 18, the films showed a gradual decrease of right pleural effusion but no significant change in bilateral pulmonary infiltration.

Antibiotics, furosemide, hydralazine and lanoxin were given for his persisting systemic complications. The patient gradually returned to normal. After the third exchange transfusion fever and chest abnormalities subsided within two weeks and hypertension was well

corrected one week later. Because skin grafting was required for the wound, his hospital stay totalled 31 days.

Discussion

The two main clinical problems of the green pit viper bite are local swelling and other soft tissue changes around the wound, and hemostatic derangement. Since these findings are caused by different components of the venom, their manifestations are not always directly correlated. Although local swelling is the hallmark of the viper envenomization, severity of swelling after the green pit viper bite obviously exceeds the other two common hematotoxic vipers of Thailand, namely the Malayan pit viper and Russell's pit viper. Compartment syndrome is, however very rarely observed in the green pit viper bite, even in cases with marked swelling, as in the above reported case. Complications of the local wound are also generally mild. Only rarely is skin grafting required.

Bleeding is the clinical finding that must be closely watched for, particularly during the first 24 hours after the bite. Thrombocytopenia and hypofibrinogenemia are the two hemostatic abnormalities directly resulting from the action of green pit viper venom on human blood⁽²⁾ and severe depression of both of them may result in significant clinical bleeding. Antivenom therapy is therefore indicated in patients who have very low platelets and fibrinogen with or without clinical bleeding in association.

The reported patient was in grave condition with severe bleeding tendency, blurry consciousness, hypertension, and, in the third episode, pulmonary hemorrhage and pulmonary infiltration. He required rapid eradication of the venom, as well as rapid correction of hemostatic defects. Exchange transfusion with fresh whole blood suited his need very well, after a dose of 40 ml specific antivenom did not seem to help. Effectiveness of the transfusion, however, was only temporary, around 2 days. The procedure had to be repeated twice, until the fifth day after the bite.

It has previously been noted that hemostatic derangement in the green pit viper bite, both in vivo^(2,3) and in vitro⁽⁴⁾ lasts for about a week after the bite. Continuous absorption of venom from the bite site, lasting about a week, may therefore be one of the mechanisms responsible for this period of abnormal observations.

References

1. Chatterjee SC. Management of snake bite cases. J Indian Med Assoc 1965 Dec; 45(12):654-9
2. Mitrakul C. Effects of green pit viper (*Trimeresurus erythrurus* and *Trimeresurus popeorum*) venoms on blood coagulation, platelets and fibrinolytic enzyme systems: studies in vivo and in vitro. Am J Clin Pathol 1973 Nov; 60(5):654-62
3. Mitrakul C. Clinical features of viper bites in 72 Thai children. Southeast Asian J Trop Med Public Health 1982 Dec; 13(4):628-36
4. Visudhiphan S, Dumavibhat B, Trishnanda M. Prolonged defibrination syndrome after green pit viper bite with persisting venom activity in patient's blood. Am J Clin Pathol 1981 Jan; 75(1):65-9